

Elsevier Editorial System(tm) for Journal of Shoulder and Elbow Surgery
Manuscript Draft

Manuscript Number: JSES-D-09-00274R1

Title: Reliability of the glenoid plane.

Article Type: Original Article

Keywords: glenoid cavity; anthropometry; plane of reference; variability; retroversion; prosthetic surgery; inferior glenoid circle; scapular plane.

Corresponding Author: DR LIEVEN DEWILDE,

Corresponding Author's Institution: UNIVERSITY HOSPITAL GHENT

First Author: Lieven F Dewilde, MD PhD

Order of Authors: Lieven F Dewilde, MD PhD; Tom Verstraete, MD; Wendy Speeckaert, MD; Anne Karelse, MD

Abstract: Hypothesis: The purpose of this study was to investigate the three dimensional orientation of the glenoid plane and the scapular plane. Different definitions of the glenoid plane were used and different planes were measured and we hypothesed that the 3-D plane with the least variation would be best to define the most reliable glenoid plane.

Methods: We studied 150 CT scans from non-pathological shoulders from patients between 18 and 80. The scapular plane and five different glenoid planes were determined: an inferior, anterior, posterior, superior and neutral glenoid plane. Of all planes version and inclination angles were measured. Because all examinations were done in a standardized position to the coronal, sagittal and transverse plane of the body the scapular plane could be defined versus the coronal, sagittal and transverse planes of the body.

Results: The version (mean: 3.76) of the inferior glenoid plane showed a significantly lower standard deviation than the version of the anterior ($p < 0.001$), posterior ($p = 0.001$) and superior ($p = 0.001$) glenoid plane (ANOVA). For inclination all planes have a similar variance. The scapular plane was different between gender ($P = 0.022$) and correlated with age.

Conclusion: This study showed that the retroversion of the inferior glenoid is reasonably constant. The osseous anthropometry of the inferior glenoid can offer a reproducible point of reference to be used in prosthetic surgery of the shoulder.

Revision of the MS. Ref. No.: JSES-D-09-00274

Comments from the Editors and Reviewers:

Associate Editor's comment:

Unfortunately the reviewer are not convinced that this study adds much useful new data to literature.

Weak points are:

Indication for CT scan examination of the contralateral shoulder not given:

The patients that were included had a CT scan examination of the contralateral (pathologic) shoulder for instability (30), AC-joint arthritis (33), Rotator Cuff tears (33), (partial (5), Full thickness (28)), calcifying tendinitis (12), frozen shoulder (8), subacromial impingement (17), tendinitis of the long head of biceps brachii (12), fractures of the proximal humerus (5). Those pathologies are included in the manuscript.

A special selection (Instability, osteoarthritis, cuff tear arthropathy) might have influenced the results.

This is a study about the normal shoulder and we hope to do in the future studies on the pathological shoulder as one might expect this might differ from the normal shoulder. The clinical examination of the shoulder as well as the history was negative of the included shoulder and this is mentioned in the manuscript.

Ethical considerations: Was the consensus of the patients for the scan of the contralateral shoulder and the ethical committee given (difference of exposure both versus one shoulder?).

Ethical approval was cleared from the ethics committee (EC/2009-099/Svdm). The patients received no extra irradiation because it is difficult to impossible to positioning one shoulder more central in the CT-scan to narrow the window of exposure and give less irradiation during the examination. This is mentioned in the manuscript.

Weak methodology:

a) In many osteoarthritis cases the posterior-inferior wear of the glenoid and the presence of osteophytes make probably precise measurements with this method difficult even with the use of the 3-D-software. Reference points which are less influenced by common glenoid deformities would be better.

This study is only a study of the glenoid plane in patients without pathology of the shoulder. To our knowledge this is the first and only study defining this plane in vivo in non pathologic human shoulders. In omathrosis a posterior-inferior wear with loss of a centred glenohumeral joint is seen in $\pm 60\%$ of the cases (64 % eccentric glenoid B1, B2, according to Habermeyer, CORR 2006) so this might be one of the challenges of the future study.

This study mainly uses the surgical guidelines that are advocated today to restore the normal glenoid plane of which is not known what is their different variation in a normal population. It is the is the first study which determines the normal glenoid plane using five different references points. These are not used in current surgical techniques were either all the systems are referring to an adjustment of the plane similar to that of the contralateral shoulder or to an adjustment to the level of the anterior plane of the glenoid.

b) Scan technique: Slices too thick without 3-D-reconstruction to evaluate rotation of the Glenoid surface to the scapula plane.

This study is using Dicom information obtained from CT-scan with slices of which we were told were taken every 2 mm. Of those slices a reconstruction is done of the whole scapula with the software program MIMICS. Due to this remark we went up looking how many slices we have available for every shoulder (in casu scapula) and we calculated at least 125 up to 180 slices per shoulder going up from the acromion down to the inferior angle of the scapula. This means between 1 to 2 mm thickness for one slice. We preferred to mention the maximum thickness of the slices as we considered that this would not affect the results of the determination of the scapular plane. For the same shoulder the glenoid plane is reconstructed using minimally 50 up to 70 slices. We hope that this explains the radiological technique better, the more that the 3-D reconstruction is used in this study to mimic as good as possible the surgical act of determining the glenoid plane. We determined the glenoid plane as we were doing open surgery!

Comparing to routine measurements which actually are performed by the majority of surgeons little new and useful information is provided.

We do not agree with this statement because the surgical technique used today to reconstruct the glenoid plane advises to use Saller's line going from the most superior point of the glenoid to the most inferior point. Another line is drawn between the most anterior point and the most posterior point. Those two lines are used to determine the centre of the glenoid which is approached by a guide to ream in a perpendicular way or if any correction is needed in with a correction calculated on one transversal slice from a 2-D Ct-scan. We think that this study clearly demonstrated that the surgeon best uses at least 3 bony references points (to construct a plane). Those bony reference points are best situated on the rim of the inferior glenoid in an effort to determine the glenoid

plane with the least variation. Because this variation is statistically different from all the other planes on a normal glenoid we think that this plane represents the most reliable glenoid plane. We believe this knowledge is new and useful information that can guide the surgeon. Indeed this study gives not the answer which reference point to use if the posteroinferior point is not available because we only studied a normal population. But apparently the superior point of the glenoid seems not the one to use....

Reviewer #1: Title: What Is Your Glenoid Plane? Is It Accurate?

Manuscript Number: JSES-D-09-00274

General Comments:

This is a well-written interesting manuscript that would be of interest to reader of the Journal of Shoulder and Elbow Surgery, particularly those that perform shoulder arthroplasty. A few revisions and clarifications are in order as outline below. Page numbers need to be reformatted as they are missing from most pages of the manuscript on the printed copy.

Specific Sections Requiring Revision:

Page 1: The authors might want to consider changing the title to something more appropriate such as "Evaluation of Glenoid Morphology" or something similar. We agree that the title might be suboptimal reflecting the message of the study. We suggest to change in: Reliability of the glenoid plane.

Line 12: I believe "transverse" is more appropriate than "transversal." Corrected.

Line 13: I believe "transverse" is more appropriate than "transversal." Corrected.

Line 31: Omit "But" at the beginning of this sentence. Corrected.

Line 40: It would be appropriate to define "Saller's line" in the manuscript. Corrected.

Line 43: I believe "transverse" is more appropriate than "transversal." Corrected.

Line 56: How was pathology excluded in the shoulder (history, normal exam findings, normal CT scan, etc)? The pathology was excluded first by clinical examination and according to the patients history. Secondly every CT-scan with structural bony pathology (like cysts and visual bony deformations of clavícula, scapula or humerus as well as the SC, AC and GH-joint) was rejected. If soft tissue swellings or muscular fatty degeneration of the rotator cuff and/or deltoid were seen the casus was not included.

Line 83: Change "de" to "the." Corrected.

Line 92: I think [7] is the wrong reference for Churchill. Corrected into 5.

Line 96: I think [7] is the wrong reference for Churchill. Corrected into 5.

Line 132: This first paragraph belongs in the Methods section. Corrected.

Line 222: Change "woman" to "women." Corrected.

Line 223: Osteoarthritis is more common in females than males in European series. The converse is true in North American series. We did study a European population and according to the information of Jain N et. al. it a similar phenomenon is seen among the population of the US. (female 66.3% versus male 33.7% ; Nitin Jain, Ricardo Pietrobon, Shawn Hocker, Ulrich Guller, Anoop Shankar, and Laurence D. Higgins The Relationship Between Surgeon and Hospital Volume and Outcomes for Shoulder Arthroplasty J. Bone Joint Surg. Am., Mar 2004; 86: 496 – 505). This information is added to the discussion.

Figure 5: A better figure would be helpful at demonstrating the neutral glenoid plane. Corrected

Table 1: This is actually a Figure, not a Table. Corrected.

Table 2: The table should be reformatted to "English style" replacing the commas with decimal points.
Corrected.

Table 3: The table should be reformatted to "English style" replacing the commas with decimal points.
Corrected.

Table 4: The table should be reformatted to "English style" replacing the commas with decimal points.
Corrected.

Reviewer #2: P 2 line 7

You are not looking for the true glenoid plane but for the more reliable glenoid plane. This is true and we thank the reviewer of this constructive criticism. We changed this in the manuscript and title.

P 2 Line 18

You mentioned in the Method paragraph that you calculated the scapula plane orientation; however no results are reported in the abstract. This is true and we can add this information in the abstract but then it becomes difficult to respect the 200 words limit. We add more information in the result chapter and in the discussion on the findings of the scapular plane.

P 4 line 54

The patients have a wide range of age (18 to 80), which increase the risk of degenerative osteophytes altering glenoid morphology.

The pathology was excluded first by clinical examination and according to the patients history. Secondly every CT-scan with structural bony pathology (like cysts and visual bony deformations of clavícula, scapula or humerus as well as the SC, AC and GH-joint) was rejected. If soft tissue swellings or muscular fatty degeneration of the rotator cuff and/or deltoid were seen the casus was not included.

Furthermore, your CT acquisition slices thickness is large (2mm) (low resolution CT), leading to obscuring the accurate visualisation of potential degenerative osteophytes in patient inclusion. 0.625mm slice allows a far better resolution.

This limitation has to be added in the discussion

Technique : This study is using Dicom information obtained from CT-scan with slices of which we were told were taken every 2 mm. Of those slices a reconstruction is done of the whole scapula with the software program MIMICS. Due to this remark we went up looking how many slices we have available for every shoulder (in casu scapula) and we calculated at least 125 up to 180 slices per shoulder going up from the acromion down to the inferior angle of the scapula. This means between 1 to 2 mm thickness for one slice. We preferred to mention the maximum thickness of the slices as we considered that this would not affect the results of the determination of the scapular plane. For the same shoulder the glenoid plane is reconstructed using minimally 50 up to 70 slices. We hope that this explains the radiological technique better, the more that the 3-D reconstruction is used in this study to mimic as good as possible the surgical act of determining the glenoid plane. We determined the glenoid plane as we were doing open surgery!

P 4 line 62

Please had much more details of the CT-scan setting (CT model used, Slices pixel, kW, mA, field of view..)

Type of scanner : Somatom Volume Zoom - Siemens.

Matrix: 512/ kV:140/ eff. mAs: 350

Field Of View: adapted to the individual patient: max. 500 for both shoulders and minimally for one shoulder 150. The scan field of view (SFOV) is always 500.

P5 line 87

How did you create the planes and calculate the angles (with Mimics software, with another software, by direct measurement on the screen)? Please had further information, because it is crucial for validating and reproducing your method

see technique

P5 lines 92 and 96

The reference does not match with the table of references.

This is corrected (one mistake in Churchill ref 7 →5)

There are also major other problem in the references (missing references..)

We had to blind our own references

Further more, Churchill calculated the glenoid version on cadaver scapula with very basic tools. In his series, the scapula were fixed in the scapular plane and the version and inclination calculated in basic 2D planes perpendicular to the scapular plane. The rotation of the glenoid was not taken into account. We would have expected that the glenoid rotation would have been taken into account with the use of CT 3-D reconstruction, but unfortunately this article failed to do it. This is the major shortcoming of this article and it probably explains why the conclusion of this huge work is so poor.

We can only agree partially with this statement. The method of Churchill is indeed concentrating on the retroversion of the glenoid and this is described as an angle between two lines the line of the scapula and the line of the glenoid at its most anterior and posterior point. This study does much more, it calculates an angle between two planes and not between two lines. And thanks to this we were able to identify a highly statistical significant difference between variation of the inferior plane and the scapular plane compared to the other planes used in this study. This study did not study 2-D information but exclusively 3-D information which we thought would be totally different from the information one can get from a transverse slice of the 2-D CT-scan. We need to admit that this seems not to be the case so one can wonder about the extra value a 3-D reconstruction gives for the orthopaedic surgeon in preoperative planning. But unfortunately this was not the aim of the study.

P5 lines 107-8

I do not understand what this sentence means. Do you mean that the glenoid plane and the transversal plane of the body are parallel?

As mentioned above we studied angles between planes and for comparison reason also for the glenoid inclination and the glenoid retroversion between lines. Because angles between planes never are measured or published in the literature we are trying to compare those angles with similar angles (between the lines) in that are known in the literature. Because in normal osteology the angle between the lines and the planes are similar (with exception for the anterior and posterior plane) we did not discuss this topic. We clarified this more in the methods and comment this difference in the discussion.

P7-8 lines 160-74

Could you please give further details of the scapula plane angles (Mean, SD, max, min)

We included this information. We extended the discussion with this information.

P9 lines 187-90

Please clarify your stance

As mentioned above we tried to do so.

1 **Reliability of the glenoid plane.**

2 Lieven F. De Wilde MD, PhD*

3 T. Verstraeten BSc*

4 W. Speeckaert MD*

5 A. Karelse MD*

6 *Department of Orthopaedic Surgery and Traumatology

7 Ghent University Hospital

8 De Pintelaan 185

9 B-9000 Ghent, Belgium

10 Correspondence :

11 L. De Wilde

12 Department of Orthopaedic Surgery and Traumatology

13 Universitair Ziekenhuis Gent, De Pintelaan 185, B-9000 Ghent, Belgium

14 Tel +32 9 3326796

15 Fax +32 9 3324975

16 E-mail:lieven.dewilde@Ugent.be

17

18 Financial Renumeration:

19 *Lieven De Wilde: The author, their immediate family, and any research*
20 *foundation with which they are affiliated have not received any financial payments or*
21 *other benefits from any commercial entity related to the subject of this article.*

22 *Tom Verstraeten: The co-author, their immediate family, and any research*
23 *foundation with which they are affiliated have not received any financial payments or*
24 *other benefits from any commercial entity related to the subject of this article.*

25 *Wendy Speeckaert: The co-author, their immediate family, and any research*
26 *foundation with which they are affiliated have not received any financial payments or*
27 *other benefits from any commercial entity related to the subject of this article.*

28 *Anne Karelse: The co-author, their immediate family, and any research*
29 *foundation with which they are affiliated have not received any financial payments or*
30 *other benefits from any commercial entity related to the subject of this article.*

31

32 Ethical approval

33 *Ethical approval was cleared from the ethics committee University Hospital*
34 *Ghent - Chairman Prof. dr. R. Rubens (EC/2009-099/Svdm : The normal*
35 *glenohumeral relationships : a 3-Dimensional CT-scan study of the humeral and*
36 *glenoid planes in one hundred and fifty normal shoulders).*

37

38 Figures to be published in colour

39 *Figure 2, 3, 4, 5, 6, 7, 8, 9, and 10 a-b-c*

1 **Reliability of the glenoid plane.**

2

3 **Abstract**

4 *Hypothesis:* The purpose of this study was to investigate the three dimensional
5 orientation of the glenoid plane and the scapular plane. Different definitions of the
6 glenoid plane were used and different planes were measured and we hypothesized that
7 the 3-D plane with the least variation would be best to define the **most reliable** glenoid
8 plane.

9 *Methods:* We studied 150 CT scans from non-pathological shoulders from patients
10 between 18 and 80. The scapular plane and five different glenoid planes were
11 determined: an inferior, anterior, posterior, superior and neutral glenoid plane. Of all
12 planes version and inclination angles were measured. Because all examinations were
13 done in a standardized position to the coronal, sagittal and **transverse** plane of the
14 body the scapular plane could be defined versus the coronal, sagittal and **transverse**
15 planes of the body.

16 *Results:* The version (mean: 3.76) of the inferior glenoid plane showed a significantly
17 lower standard deviation than the version of the anterior ($p < 0.001$), posterior
18 ($p = 0.001$) and superior ($p = 0.001$) glenoid plane (ANOVA). For inclination all planes
19 have a similar variance. **The scapular plane was different between gender ($P = 0.022$)**
20 **and correlated with age.**

21 *Conclusion:* This study showed that the retroversion of the inferior glenoid is
22 reasonably constant. The osseous anthropometry of the inferior glenoid can offer a
23 reproducible point of reference to be used in prosthetic surgery of the shoulder.

24 *Keywords:* glenoid cavity; anthropometry; plane of reference; variability; retroversion;
25 prosthetic surgery; inferior glenoid circle; scapular plane.

26 *Prognostic Study, Level II of Evidence.*

27

28 **Introduction**

29 Restoration of the glenoid plane is essential in total shoulder arthroplasty. Failing to
30 restore the inclination and the version of the glenoid is associated with prosthetic
31 instability and jeopardizes the longevity of the prosthesis²⁵. Correct restoration of the
32 glenoid plane balances the forces across the glenoid and prosthetic components
33 thereby improving stability, and functional outcomes^{14, 19, 30, 33}. The definition of the
34 glenoid plane itself is not clear. This can be explained by the fact that the morphology
35 of the glenoid is extremely diverse⁸. Also the angulation of the glenoid has a wide
36 range of variety in healthy individuals with a version ranging from 14 degrees of
37 retroversion to 12 degrees of anteversion^{3, 5, 10, 22, 24}, and an inclination ranging from –
38 8° to 15.8°^{5, 12}.

39 At the inferior glenoid a constant shape of a true circle can be distinguished^{8, 13, 16}. The
40 plane of this inferior glenoid circle is less variable and can be used as an anatomic
41 guide^{17, 21} in prosthetic glenoid surgery. However the orthopaedic surgeon tends to
42 use the plane with the centre defined as the crossing line between the most superior
43 and inferior point of the glenoid (Saller's line) and the largest antero-posterior distance
44^{1, 26}. Recently a standardized 3-dimensional (3-D) glenoid vault model mimicking the
45 contralateral shoulder was introduced to assist in restoring the plane of the glenoid in
46 the coronal and transversal plane of the body^{6, 27, 28}. It is assumed that this plane
47 represents the normal plane of the body for that individual person¹⁶. The normal
48 anatomy of the 3-D positioning of the glenoid plane in a population is still unknown.
49 The purpose of this study is to investigate the normal three dimensional relationship of
50 the glenoid plane and scapular plane, and we try to define the most reliable glenoid
51 plane, which should be most suitable for prosthetic surgery. Different definitions of the
52 glenoid plane were used and different planes were measured and we hypothesed that
53 the 3-D plane with the least variation would be best to define the 'true' glenoid plane.

54

55 **Material and Methods**

56 We examined 150 Computed tomography (CT) scans of non pathologic shoulders of
57 patients who were examined with an arthro-ct scan for pathology of the contra lateral
58 shoulder. The patients were between 18 and 80 years old (mean: 41.75). There were
59 68 females and 82 males. The age distribution is found in figure 1.

60 Ethical approval was cleared from the ethics committee (EC/2009-099/Svdm). The
61 patients received no extra irradiation because it is difficult to impossible to
62 positioning one shoulder more central in the CT-scan tunnel to be able to narrow the
63 window resulting in less irradiation.

64 The patients that were included had a CT scan examination of the contralateral
65 (pathologic) shoulder for instability (30), AC-joint arthritis (33), Rotator Cuff tears
66 (33), (partial (5), Full thickness (28)), calcifying tendinitis (12), frozen shoulder (8),
67 subacromial impingement (17), tendinitis of the long head of biceps brachii (12),
68 fractures of the proximal humerus (5).

69 The shoulder was included if any pathology was excluded first by clinical
70 examination and according to the patients history. If any structural bony pathology
71 (like cysts and visual bony deformations of clavícula, scapula or humerus as well as
72 the SC, AC and GH-joint) or soft tissue pathology (like swellings or muscular fatty
73 degeneration of the rotator cuff and/or deltoid) were seen the casus was not
74 included.

75 The CT-scan settings are : type of scanner : Somatom Volume Zoom – Siemens
76 (Siemens Business Park, Marie Curiesquare 30 - Square Marie Curie 30; 1070
77 Brussel – Bruxelles). Matrix: 512/ kV:140/ eff. mAs: 350. The scan field of view
78 (SFOV) is always 500. Field of view (FOV): adapted to the individual patient: max. 500
79 for both shoulders and minimally for one shoulder 150.

80 In an effort to minimize the influence of the individual positioning all CT scans were
81 made with the patient positioned as described by the senior author¹⁷ in dorsal
82 recumbency and with a thoracobrachial orthosis to keep the arm adducted in the
83 coronal plane and the forearm flexed in the sagittal plane of the body. The
84 glenohumeral joint was scanned with 2-mm interval slices. Three independent

85 investigators imported CT-images (dicom) into a medical imaging computer software
86 (Mimics® 11.02 for Intel X86 Platform V11.2.2.1 1992-2007 Materialise n.v.,
87 Haasrode Belgium) to create 3D images of the shoulder joint. Both bones of the joint
88 could be separated digitally and virtually manipulated to determine the bony
89 reference points for purposes of measurement.

90 The five different glenoid planes were created as follows:

91 Four points were indicated at the glenoid rim: A superior point (S) and an inferior point
92 (I) at the greatest length of the glenoid (=identical to the points used to determine
93 Saller's line), an anterior point (A) and a posterior point (P) at the greatest width of the
94 glenoid.

95 The *inferior glenoid plane* was determined by three points : the anterior point (A), the
96 posterior point (P) and the inferior point (I) (figure 2).

97 The *anterior glenoid plane* was determined by three points: the superior (S), the
98 inferior (I) and the anterior (A) (figure 3).

99 The *posterior glenoid plane* was determined by three points : the superior (S), the
100 inferior (I) and the posterior (P) (figure 4).

101 The *superior glenoid plane* was determined by three points : the superior (S), the
102 anterior (A) and the posterior (P) (figure 5).

103 The *neutral glenoid plane* was determined by only two points : the superior (S) and
104 the inferior (I), and is perpendicular to the scapular plane (figure 6).

105 The *scapular plane* is the plane determined by three points : a lateral scapular point in
106 the surgical centre of the glenoid (this is the crosspoint (C) between the line between
107 the most anterior point (A) and the most posterior point (P) and the line between the
108 most superior point (S) and the most inferior point (I)), a medial scapular point (MS) at
109 the most medial point of the spina scapula and the inferior scapular point (IS) at the
110 most inferior point of the scapula (figure 7).

111 From these planes different angles were measured:

112 A. Angles measured within the scapula.

113 A. a. angles between lines:

114 **2-D Glenoid version (GV):** the angle between the line from the most anterior point (A)
115 to the most posterior point (P) and **the line of the scapular plane**, calculated conform
116 the method of Churchill ⁵ (figure 8).

117 **2-D Glenoid inclination (GI):** the angle between the line from the most superior point
118 (S) to the most inferior point (P) and the line between the most medial scapular point
119 (MS) and the middle of the glenoid (crosspoint (C)), measured conform the method of
120 Churchill ⁵ (figure 9)

121 **A. b. angles between planes:**

122 **3-D Glenoid retroversion:** the angle between the scapular plane and the plane of
123 different glenoid planes (superior, inferior, anterior, posterior and the neutral plane).

124 **3-D Glenoid inclination:** the angle between the perpendicular to scapular plane
125 including point C and point MS and the plane of different glenoid planes (superior,
126 inferior, anterior, posterior and the neutral plane).

127 **B. Angles of the different glenoid planes (neutral, superior, anterior, posterior**
128 **and inferior) and the scapular plane versus the coronal, sagittal and**
129 **transversal plane of the body (Spatial parameters).**

130 Because all measurements are related to the *scapular plane* all patients were
131 positioned similar to minimize error due to a different scapular orientation. This
132 allowed us to measure the scapular plane and different scapular angles. We defined
133 the angle of the scapular plane and the coronal plane as the *Coronal Scapular Angle*
134 (CSA) (figure 10-a), the angle of the scapular plane and the sagittal plane as the
135 *Sagittal Scapular Angle (SSA)* (figure 10-b) and the angle of the scapular plane and
136 the transversal plane as the *Transversal Scapular Angle (TSA)* (figure 10-c). This
137 means that CSA is comparable to the angle measured in the transversal plane of the
138 body in a normal CT-setting. For the SSA this means that this angle is comparable to
139 the angle of the glenoid plane (AG) ⁹.

140 **Statistical analysis**

141 Statistical testing was performed (ANOVA) to detect significant differences in the
142 measured angles.

143 a. Comparative man/women

144 A Mann-Whitney U test (MWU) was used to detect the distribution of angle

145 measurements between males and females

146 b. Correlation

147 Spearman correlations were used to explore the correlation with age.

148 Regression models for each of the angle measurements were used to verify the

149 interaction between age and gender and to obtain (potentially) age- and gender

150 specific normal distributions of the angle. P-values smaller than 0.05 were considered

151 significant. Terms with $p < 0.10$ were kept in the regression model. No corrections for

152 multiple testing were performed, since the aim is to detect any indication that the

153 construction of normal values for the angle measurements should be done gender

154 and/or age-specific.

155 c. Accuracy, reliability and repeatability

156 Twenty different glenoids were analysed by two independent investigators in order to

157 determine the inter-observer variability. To measure the intra-observer variability, 20

158 specimens were analysed twice by the same person. To determine these variabilities,

159 the interclass and intraclass correlation coefficient were used ²⁹ (ICC, Wilcoxon on

160 Signed Ranks test).

161

162 **Results**

163 *A. Angles measured within the scapula*

164 *A. a. angles between lines:*

165 *2-D Glenoid version (GV):* the descriptive statistics are mean=-3.78° ; Min=-13.74° ;
166 Max=4.89° ; SD=3.50°.

167 *2-D Glenoid inclination (GI):* the descriptive statistics for the method of Churchill⁵ are
168 mean=10.89° ; Min=1.02° ; Max=24.91° ; SD=4.46°.

169 *A. b. angles between planes*

170 *a. Descriptive statistics*

171 *3-D Glenoid retroversion:* the descriptive statistics of the different glenoid planes
172 (superior, inferior, anterior, and posterior) to the scapular plane can be find in (table 1).
173 The angle between the neutral plane is of course always 90°.

174 *3-D Glenoid inclination:* the descriptive statistics of the different glenoid planes
175 (superior, inferior, anterior, and posterior) to the scapular plane can be find in (table 2).

176 *B. Angles of the different glenoid planes (neutral, superior, anterior, posterior*
177 *and inferior) and the scapular plane versus the coronal, sagittal and*
178 *transversal plane of the body (Spatial parameters).*

179 *3-D angle of the different glenoid planes:* the descriptive statistics of the different
180 glenoid planes (neutral, superior, inferior, anterior, and posterior) versus can be find in
181 (table 3).

182 *3-D angle of the scapular plane :* the descriptive statistics of the different glenoid
183 planes CSA, SSA and TSA can be find in (table 4).

184 *b. Comparative statistics*

185 The 3-D retroversion of the inferior glenoid plane showed a significantly lower
186 standard deviation than the version of the anterior (p<0.001), posterior (p=0.001) and
187 superior (p=0.001) glenoid plane (ANOVA). Figure 11-a shows a normal distribution of
188 the inferior glenoid version and figure 11-b shows its Q-Q plot.

189 For the 3-D retroversion of the posterior glenoid plane (p=0.036) significantly different
190 values were found between men (mean : -13,2507) and woman (mean : -14,9748)
191 (MWU test) implying that a less retroverted posterior glenoid plane is found in men.

192 No significant difference between all calculated inclination angles was found
193 (ANOVA).

194 A significant difference between men (mean : 20,3009) and woman (mean : 22,3078)
195 was found (MWU) for the 3-D inclination ($p = 0,035$) of the inferior glenoid plane: in
196 men less inclination is found.

197 A significant difference between the defined different glenoid planes is found $p <$
198 0.001 (MWU).

199 c. Correlation statistics

200 A correlation with age was found for 3-D retroversion of the anterior glenoid plane ($r =$
201 -0.162 , correlation at the 0.05 level) and superior glenoid plane ($0,186$, correlation at
202 the 0,05 level) implying that both planes are more retroverted in the elderly (Spearman
203 correlation).

204 No significant correlation could be calculated between the 3-D inclination angles and
205 age or gender (Spearman correlation).

206 *B. Angles of the scapular plane versus the coronal, sagittal and transversal* 207 *plane of the body (Spatial parameters).*

208 a. Comparative

209 The mean SSA in women is $53,3119^\circ$, in men : $55,4463^\circ$. The difference is
210 significant ($p=0.022$) (MWU) and implies that the scapular plane is more protracted in
211 women.

212 b. Correlation

213 For the SSA ($r = 0.171$, correlation at the 0.05 level) and the TSA ($r=-0.224$,
214 correlation at the 0.01 level) a significant correlation with age was found: in the elderly
215 the protraction and the anteflexion of the scapular plane increases. (Spearman
216 correlation).

217 *Accuracy, reliability and repeatability.*

218 Inter- and intra-observer variability was very high with an intraclass correlation
219 coefficient of 0.98 and an intraclass coefficient of 0.99 (ICC, Wilcoxon Signed Rank
220 Tests).

221 **Discussion**

222 We used a three dimensional reconstruction soft ware program (Mimics®) that
223 enabled us to define the orientation of the scapular plane and glenoid plane versus the
224 coronal, sagittal and transversal plane of the body in a patient positioned in dorsal
225 recumbency. According to the literature this is the first study which defines the three
226 dimensional orientation of the scapular and glenoid plane in vivo. The knowledge of
227 this orientation can be important in future studies of the range of motion of the
228 shoulder ⁴, instability ²⁴ and rotator cuff tears ^{1, 23, 31, 32}.

229 The osseous measurements of this 3-D CT-scan reconstruction are consistent with
230 the literature. The **2-D retroversion** of the superior and inferior plane are comparable
231 with the known osteology ^{3, 5, 11, 17, 20, 21, 22, 26}. The reason why the version of the
232 anterior and posterior plane are not comparable with the literature is that the maximum
233 anteroposterior diameter of the glenoid is not taken into account. The same
234 phenomenon is seen comparing **the 2-D inclination** with the known literature ^{1, 11, 12, 17,}
235 ²⁰. A different absolute value is found regarding the inclination of the inferior or
236 superior plane, a comparable value is found with the neutral, the anterior and posterior
237 plane.

238 Standardizing the positioning of the patient in the scanner minimizes the error of
239 positioning both scapulae in a different coronal plane. The thoracobrachial orthosis
240 forces the elbow (and the shoulder) to be positioned at the same transversal level and
241 brings the upper arms (and caput humeri) in the same rotation. In a previous study ⁹
242 we could demonstrate that this positioning reduces the variability of the in vivo
243 measurements to the variability of the osseous anthropometric results. Unfortunately
244 neither the length, the weight and the body mass of the patients are taken into
245 account, nor are the length and the orientation of the clavícula. These shortcomings
246 can be considered as the major weakness of this study which can thereby not pretend
247 to analyse the impact of the morphology of the clavicle and thoracic cage on the
248 positioning of the scapula.

249 Although this study has a very high intra- en interobserver accuracy a similar variation
250 is found between our measurements and the literature confirming the known variation

251 of these measurements ^{3, 5, 11, 17, 20, 21, 22, 26}. Only one exception is found for this
252 statement : this study defines the inferior glenoid plane as the plane with the least
253 variability regarding the retroversion of the glenoid ($p \leq 0.001$). Conform with the
254 literature this plane is the plane of the inferior glenoid circle ^{8, 13, 16, 21}, which seems to
255 be a constant finding of the in the **normal** glenoid morphology. The variability of the
256 inclination of this plane is similar to the variability of the other planes. The inferior
257 plane is situated more distally so a greater influence of variables as morphology of the
258 clavicle and the thoracic cage can be expected.

259 **Because this study calculates a statistically significant difference between all the**
260 **different planes of the glenoid it seems important to define the most reliable one if the**
261 **surgeon wants to reconstruct normal anatomy. This might be difficult when normal**
262 **anatomy is distorted as is the case in about two third of the rotator cuff sufficient**
263 **omarthrosis which shows a posteroinferior defect of the glenoid ¹². Probably new**
264 **parameters need to be defined ⁶ or computer aided surgery will be indicated to mimic**
265 **as close as possible normal glenoid anatomy.**

266 The results show that the scapular plane is more protracted in women than in men,
267 and that protraction and anteflexion of the scapular plane increase in the elderly. This
268 might be explained by the degree of thoracic kyphosis which increases with age and
269 effects the thoracic morphology and so scapular orientation ^{7, 18}.

270 The scapular positioning influences the glenoid plane as well ^{9, 18}. Nevertheless this
271 study could not find particular relationships between the scapula and the glenoid. We
272 demonstrated a less inclined inferior glenoid plane in men than in woman and
273 maybe this can be seen as a causal factor in the higher incidence of rotator cuff tears
274 in men ^{1, 34}.

275 This study found less retroversion of the posterior glenoid plane in men than in
276 woman and this can be probably an explanation why degenerative osteoarthritis of the
277 shoulder is less frequently found in men than in women ^{2, 15}. The anterior and superior
278 glenoid plane are more retroverted in the elderly, but aging cannot explain this since
279 none of the scans showed degenerative articular signs. Maybe it is a consequence of
280 aging of the rotator cuff ³⁴. These statements need to be confirmed by studies

281 comparing inclination and version in non-pathologic shoulders to the values in
282 shoulders with rotator cuff tears and degenerative osteoarthritic lesions.
283

284 **Conclusion**

285 This study shows that the inferior plane of the glenoid formed by the most anterior,
286 posterior and inferior point of the rim of the glenoid has a constant degree of
287 retroversion. This finding supports the use of this plane as the most appropriate plane
288 to restore normal anatomy. This is important in prosthetic surgery where the
289 restoration of the glenoid anatomy is crucial for the longevity of the prosthesis and the
290 functional outcomes.

291

292 **References**

- 293 1. Bishop JL, Kline SK, Aalderink KJ, Zauel R, Bey MJ. Glenoid inclination: in vivo
294 measures in rotator cuff tear patients and associations with superior
295 glenohumeral joint translation. *J Shoulder Elbow Surg* 2009;18:231-6.
- 296 2. Boileau P, Sinnerton RJ, Chuinard C, Walch G. Arthroplasty of the shoulder *J*
297 *Bone Joint Surg Br* 2006;88:562-75.
- 298 3. Bokor DJ, O'Sullivan MD, Hazan GJ. Variability of measurement of glenoid
299 version on computed tomography scan. *J Shoulder Elbow Surg* 1999;8:595-8.
- 300 4. Chant CB, Litchfield R, Griffin S, Thain LM.. Humeral head retroversion in
301 competitive baseball players and its relationship to glenohumeral rotation range
302 of motion. *J Orthop Sports Phys Ther* 2007;37:514-20.
- 303 5. Churchill RS, Brems JJ, Kotschi H. Glenoid size, inclination, and version: an
304 anatomic study. *J Shoulder Elbow Surg* 2001;10:327-32.
- 305 6. Codsí MJ, Bennetts C, Gordiev K, Boeck DM, Kwon Y, Brems J, et al. Normal
306 glenoid vault anatomy and validation of a uniform glenoid vault shape. *J*
307 *Shoulder Elbow Surg* 2008;17:471-8.
- 308 7. Culham EG, Jimenez HA, King CE. Thoracic kyphosis, rib mobility, and lung
309 volumes in normal women and women with osteoporosis. *Spine* 1994;19:1250-5.
- 310 8. De Wilde LF, Berghs BM, Audenaert E, Sys G, Van Maele GO, Barbaix E. About
311 the variability of the shape of the glenoid cavity. *Surg Radiol Anat* 2004;26:54-9
- 312 9. De Wilde LF, Berghs BM, VandeVyver F, Schepens A, Verdonk RC.
313 Glenohumeral relationship in the transverse plane of the body. *J Shoulder Elbow*
314 *Surg* 2003;12:260-7.
- 315 10. Friedman RJ, Hawthorne KB, Genez BM. The use of computerized tomography
316 in the measurement of glenoid version. *J Bone Joint Surg Am* 1992;74:1032-7
- 317 11. Gallino M, Santamaria E, Doro T. Anthropometry of the scapula: clinical and
318 surgical considerations. *J Shoulder Elbow Surg* 1998;7:284-91.
- 319 12. Habermeyer P, Magosch P, Luz V, Lichtenberg S. Three-dimensional glenoid
320 deformity in patients with osteoarthritis: a radiographic analysis. *J Bone Joint*
321 *Surg Am* 2006;88:1301-7.

- 322 13. Huysmans PE, Haen PS, Kidd M, Dhert WJ, Willems JW. The shape of the
323 inferior part of the glenoid: a cadaveric study. *J Shoulder Elbow Surg* 2006;
324 15:759-63.
- 325 14. Iannotti JP, Norris TR. Influence of preoperative factors on outcome of shoulder
326 arthroplasty for glenohumeral osteoarthritis. *J Bone Joint Surg Am* 2003;85:251-
327 8.
- 328 15. Jain N, Pietrobon R, Hocker S, Guller U, Shankar A, Higgins LD. The
329 **Relationship Between Surgeon and Hospital Volume and Outcomes for Shoulder**
330 **Arthroplasty** *J. Bone Joint Surg. Am.*, Mar 2004; 86: 496 – 50.
- 331 16. Jeske HC, Oberthaler M, Klingensmith M, Dallapozza C, Smekal V, Wambacher
332 M, et al. Normal glenoid rim anatomy and the reliability of shoulder instability
333 measurements based on intrasite correlation. *Surg Radiol Anat* 2009 Mar 28.
334 epub ahead.
- 335 17. Karelse A, Kegels L, De Wilde L. The pillars of the scapula. *Clin Anat*
336 2007;20:392-9.
- 337 18. Kebaetse M., McClure P. and Pratt N.E. Thoracic position effect on shoulder
338 range of motion, strength, and three-dimensional scapular kinematics, *Arch Phys*
339 *Med Rehabil.* 1999;80:945-50.
- 340 19. Levine WN, Djurasovic M, Glasson JM, Pollock RG, Flatow EL, Bigliani LU.
341 Hemiarthroplasty for glenohumeral osteoarthritis: results correlated to degree of
342 glenoid wear. *J Shoulder Elbow Surg* 1997;6:449-54.
- 343 20. Mallon WJ, Brown HR, Vogler JB 3rd, Martinez S. Radiographic and geometric
344 anatomy of the scapula. *Clin Orthop Relat Res* 1992;277:142-54.
- 345 21. Middernacht B, De Roo PJ, Van Maele G, De Wilde LF. Consequences of
346 scapular anatomy for reversed total shoulder arthroplasty. *Clin Orthop Relat Res*
347 2008;466:1410-8.
- 348 22. Nyffeler RW, Jost B, Pfirrmann CW, Gerber C. Measurement of glenoid version:
349 conventional radiographs versus computed tomography scans. *J Shoulder*
350 *Elbow Surg* 2003;12:493-6.

- 351 23. Nyffeler RW, Werner CML, Sukthankar A, Schmid MR, Gerber C. Association of
352 a large lateral extension of the acromion with rotator cuff tears. *J. Bone Joint*
353 *Surg Am* 2006;88:800-5.
- 354 24. Randelli M, Gambrioli PL. Glenohumeral osteometry by computed tomography in
355 normal and unstable shoulders. *Clin Orthop Relat Res* 1986;208:151-6.
- 356 25. Rispoli DM, Sperling JW, Athwal GS, Wenger DE, Cofield RH. Projection of the
357 glenoid center point within the glenoid vault. *Clin Orthop Relat Res* 2008;466:
358 573-8.
- 359 26. Book chapter : Saller K., editor. *Systematische anthropologie. Somatische*
360 *anthropologie. Lehrbuch der Anthropologie.* Stuttgart: Gustav Fisher Verlag;
361 1957. p 528-32.
- 362 27. Scalise JJ, Bryan J, Polster J, Brems JJ, Iannotti JP. Quantitative analysis of
363 glenoid bone loss in osteoarthritis using three-dimensional CT-scans. *J Shoulder*
364 *Elbow Surg* 2008;17:328-35.
- 365 28. Scalise JJ, Codsí MJ, Bryan J, Iannotti JP. The three-dimensional glenoid vault
366 model can estimate normal glenoid version in osteoarthritis. *J Shoulder Elbow*
367 *Surg* 2008;17:487-91.
- 368 29. Shrout PE, Fleiss JL. Intraclass correlations : uses in assessing rater reliability.
369 *Psychological Bulletin* 1979;86:420-28.
- 370 30. Sperling JW, Cofield RH, Rowland CM. Neer hemiarthroplasty and Neer total
371 shoulder arthroplasty in patients fifty years old or less. Long-term results. *J Bone*
372 *Joint Surg Am* 1998;80:464-73.
- 373 31. Tétreault P, Krueger A, Zurakowski D, Gerber C. Glenoid version and rotator cuff
374 tears. *J Orthop Res* 2004;22:202-7.
- 375 32. Tokgoz N, Kanatli U, Voyvoda NK, Gultekin S, Bolukbasi S, Tali ET. The
376 relationship of glenoid and humeral version with supraspinatus tendon tears.
377 *Skeletal Radiol* 2007;36:509-14.
- 378 33. Wirth MA, Tapscott RS, Southworth C, Rockwood CA Jr. Treatment of
379 glenohumeral arthritis with a hemiarthroplasty: a minimum five-year follow-up
380 outcome study. *J Bone Joint Surg Am* 2006;88: 964-73.

381 34. Yamaguchi K, Ditsios K, Middleton WD, Hildebolt CF, Galatz LM, Teefey SA.
382 The demographic and morphological features of rotator cuff disease. A
383 comparison of asymptomatic and symptomatic shoulders. J Bone Joint Surg Am.
384 2006;88:1699-704.
385

386 **Figures**

387

388 Figure 1 : Age distribution of the patients

389 Figure 2: Inferior Glenoid Plane: was determined by setting 3 points on the rim of the
390 inferior quadrants of the glenoid. An inferior (I), anterior (A) and posterior (P) glenoid
391 point.

392 Figure 3: Anterior Glenoid Plane: was determined by setting 3 points on the rim of the
393 anterior quadrants of the glenoid. An inferior (I), superior (S) and anterior (A) glenoid
394 point.

395 Figure 4: Posterior Glenoid Plane: was determined by setting 3 points on the rim of the
396 posterior quadrants of the glenoid. An inferior (I), superior (S) and posterior (P) glenoid
397 point.

398 Figure 5: Superior Glenoid Plane: was determined by setting 3 points on the rim of the
399 posterior quadrants of the glenoid. A superior (S), anterior (A) and posterior (P)
400 glenoid point.

401 Figure 6: Neutral Glenoid Plane: was determined by setting two points on the rim of
402 the superior and inferior quadrant of the glenoid. An inferior (I) and superior (S) glenoid
403 point. This plane is perpendicular to the scapular plane.

404 Figure 7: Scapular Plane: was determined by selecting three points on the scapula. A
405 lateral scapular point in the center of the glenoid (C) which is the cross point of the line
406 between the most superior (S) and inferior (I) glenoid point (Sallers line) and the line
407 between the most anterior (A) and most posterior (P) point of the glenoid, a medial
408 scapular point (MS) at the most medial point of the spina scapula and the inferior
409 scapular point (IS) at the most inferior point of the scapula.

410 Figure 8 : **2-D Glenoid** version : angle between the line from the most anterior point
411 (A) to the most posterior point (P) and the scapular plane (formed by the most medial
412 scapular point (MS) and the center of the glenoid (C)).

413 Figure 9: **2-D Glenoid** inclination (GI) :

414 according to the method of Churchill: angle between the line from superior point (S) to
415 inferior point (P) and the line between the line from the most medial scapular point
416 (MS) and the middle of the glenoid (crosspoint (C)) -90°.

417 Figure 10 : 3-D angles :

418 Figure 10-a: the *Coronal Scapular Angle (CSA)* = the angle of the scapular
419 plane and the coronal plane.

420 Figure 10-b: the *Sagittal Scapular Angle (SSA)* the angle of the scapular plane
421 and the sagittal plane as and the angle

422 Figure 10-c: the *Transversal Scapular Angle (TSA)* = the angle of the scapular
423 plane and the transversal plane

424 Figure 11 : distribution of the version of the inferior glenoid plane

425 Figure 11-a: Normal distribution of the Inferior Glenoid Version.

426 Figure 11-b: Q-Q Plot to demonstrate the normal distribution of the Inferior
427 Glenoid Version.

428

429 ***Content of Tables***

430 Table 1: Descriptive statistics of the version angles of the different glenoid planes.

431 Negative values are retroversion, positive values are anteversion.

432 Table 2: Descriptive statistics of the inclination of the glenoid planes. Negative values
433 have a caudal directed angle (downslope) and positive values have a cranial directed
434 angle (upslope).

435 Table 3: Descriptive statistics of the different glenoid plane (superior, anterior,
436 posterior, inferior and neutral) versus the coronal, sagittal and transversal plane of the
437 body.

438 Table 4: Descriptive statistics of the scapular plane versus the coronal, sagittal and
439 transversal plane of the body.

440

Figure 1 :

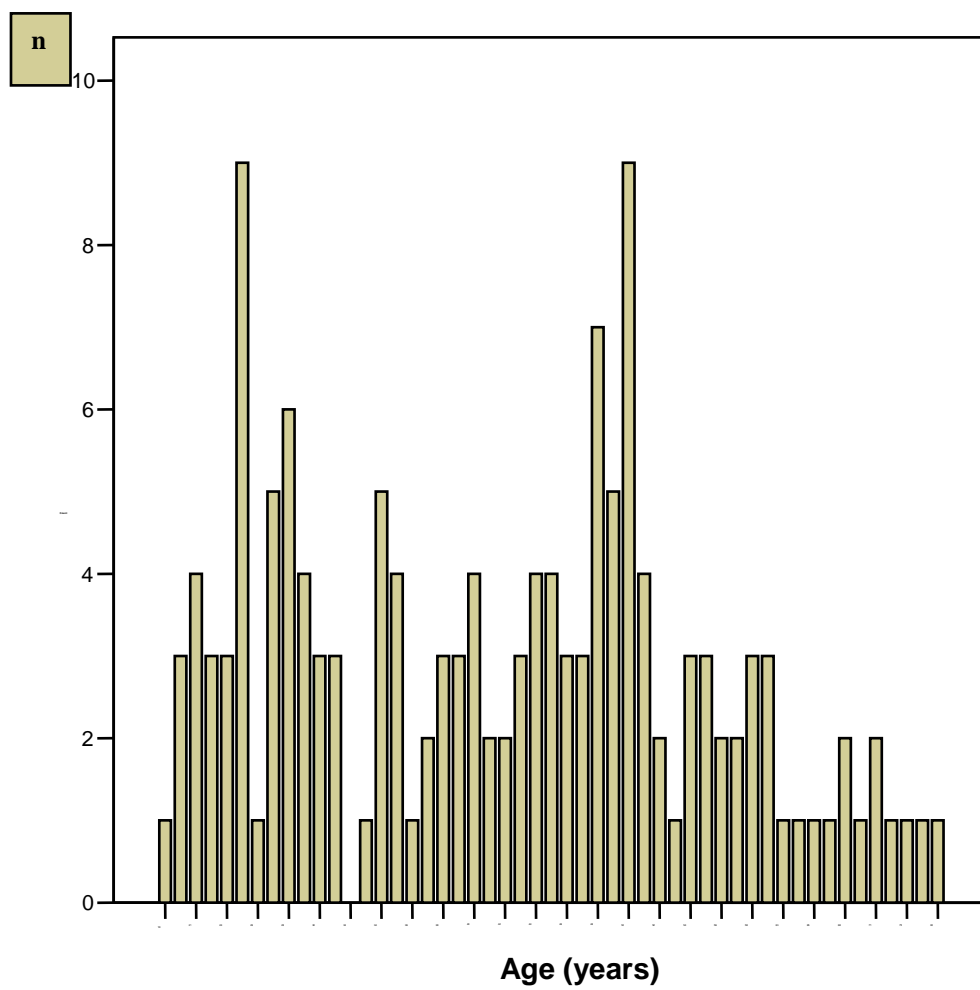


Figure 2

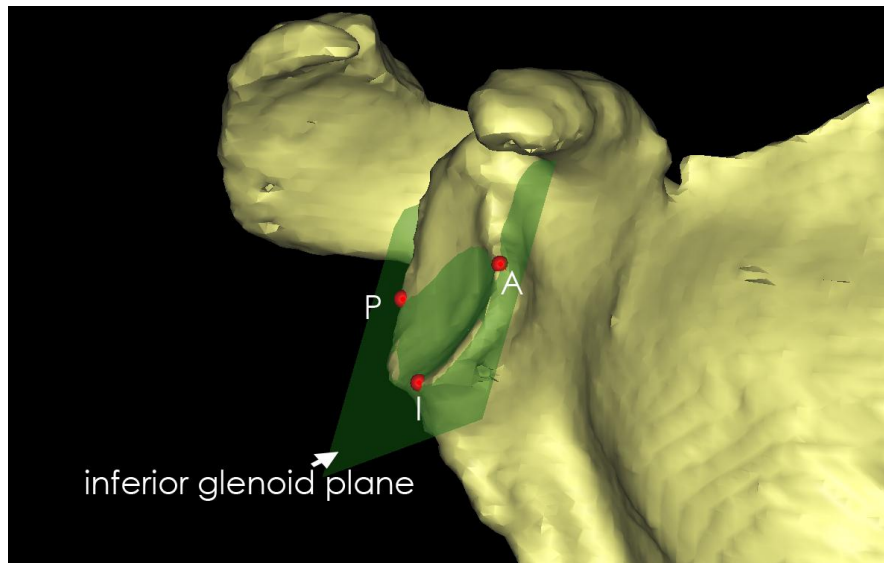


Figure 3:

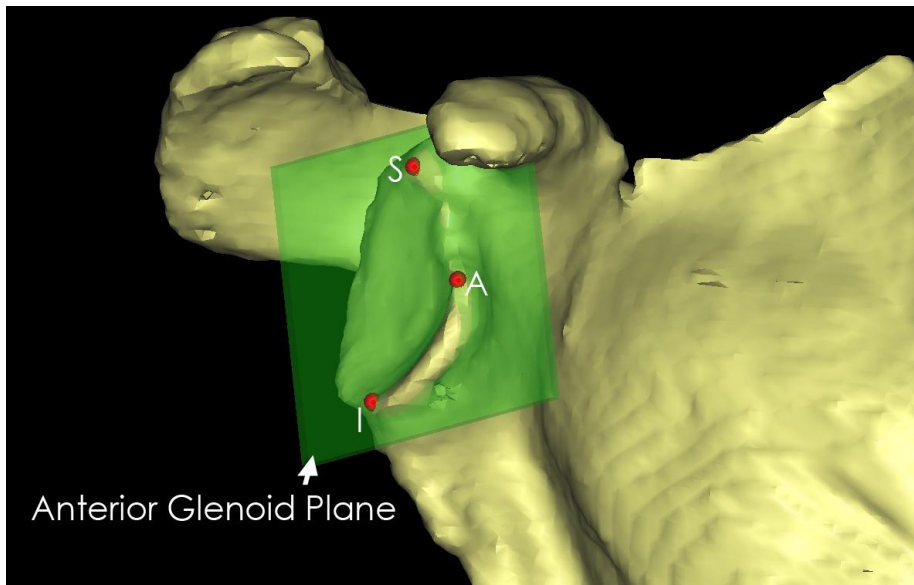


Figure 4 :

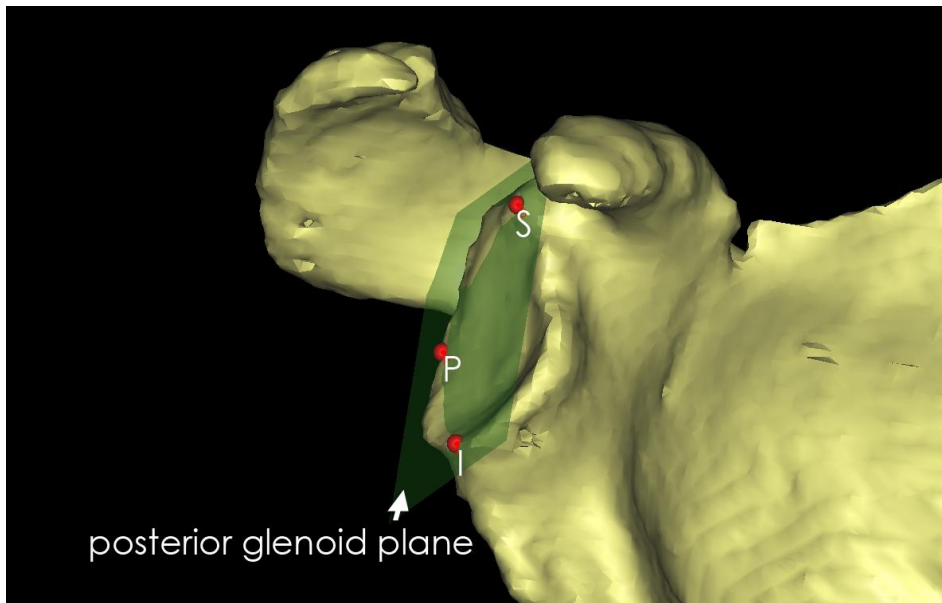


Figure 5 :

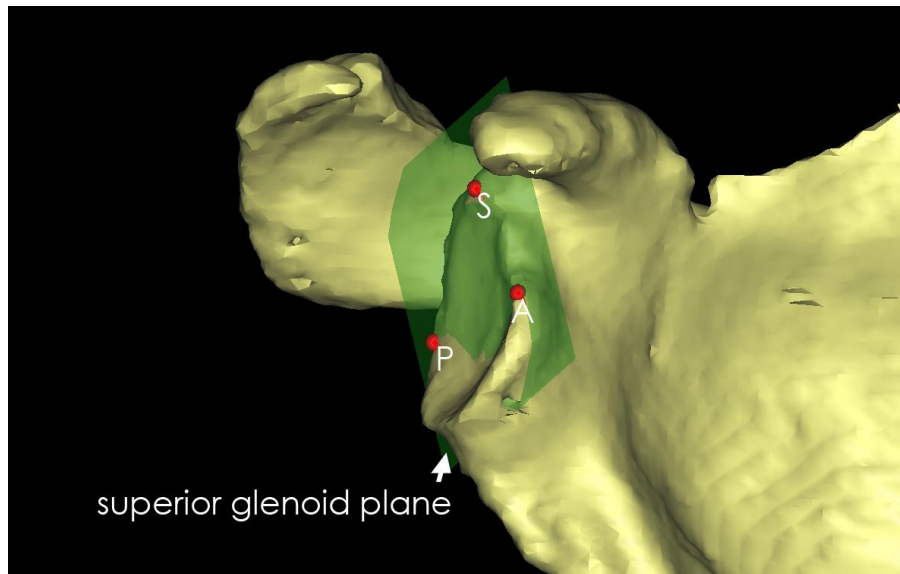


Figure 6 :

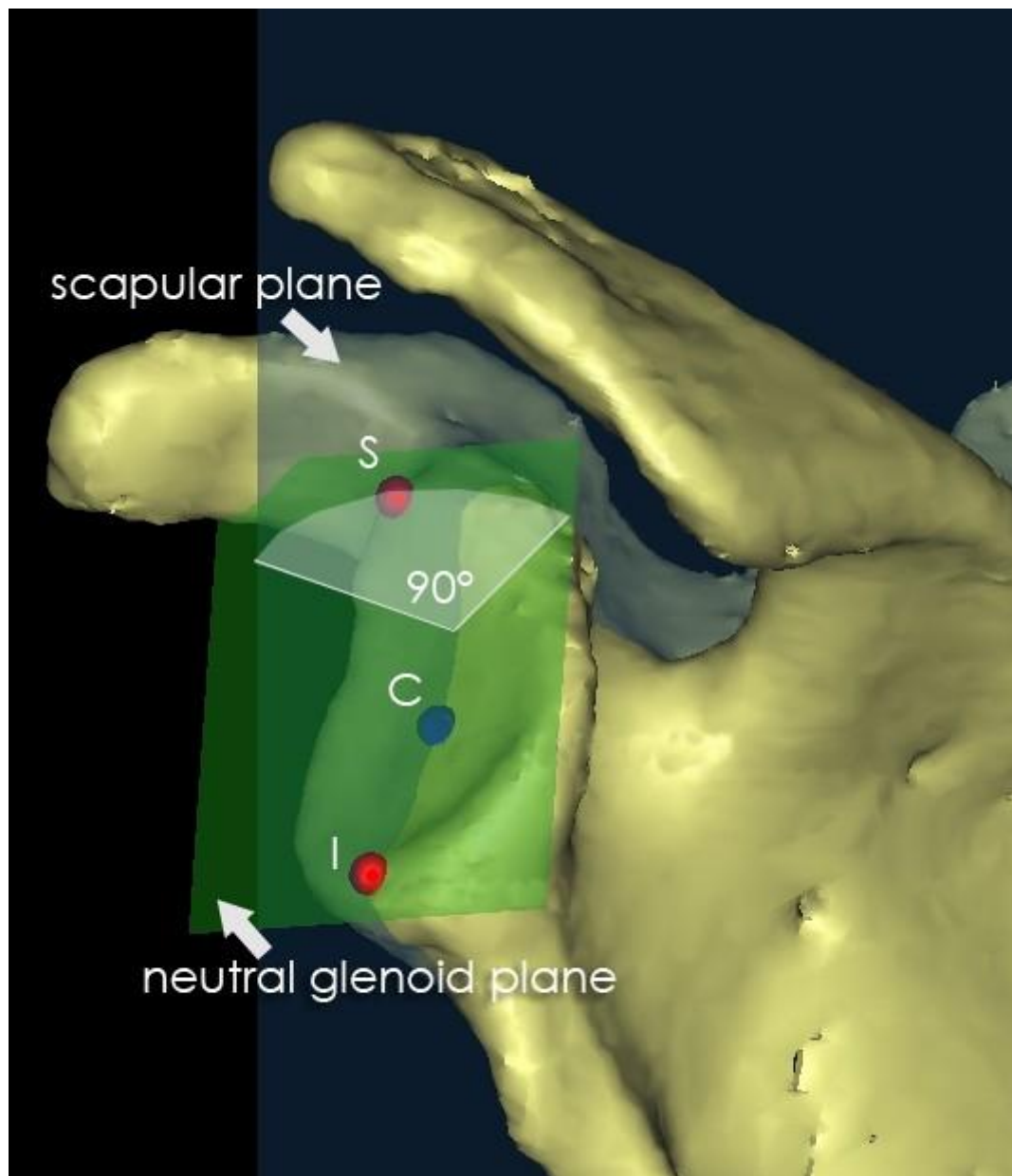


Figure 7 :

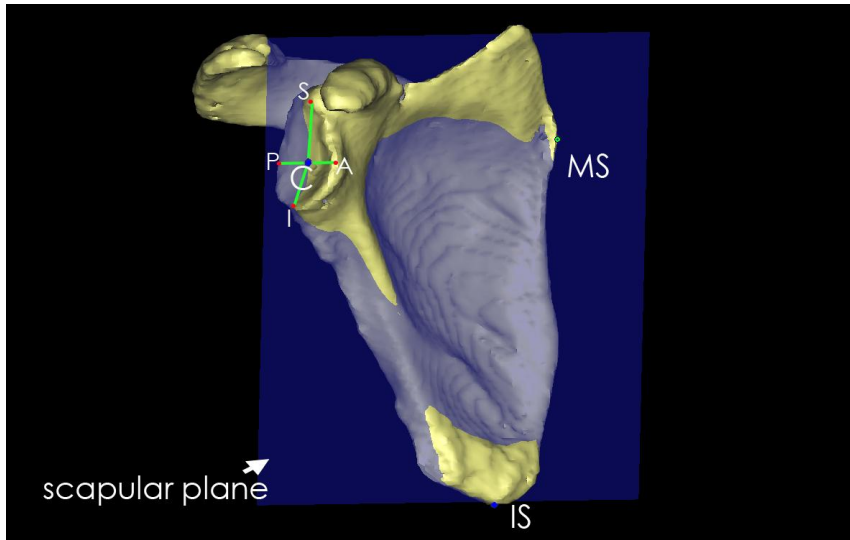


Figure 8 :

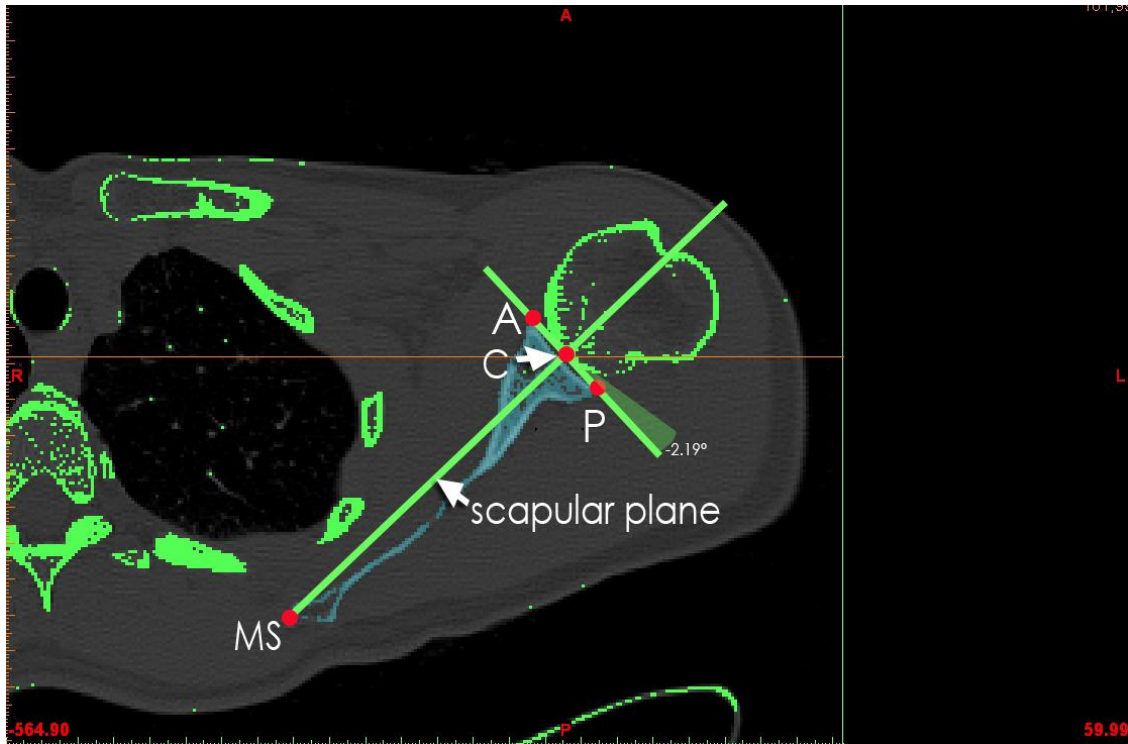


Figure 9 :

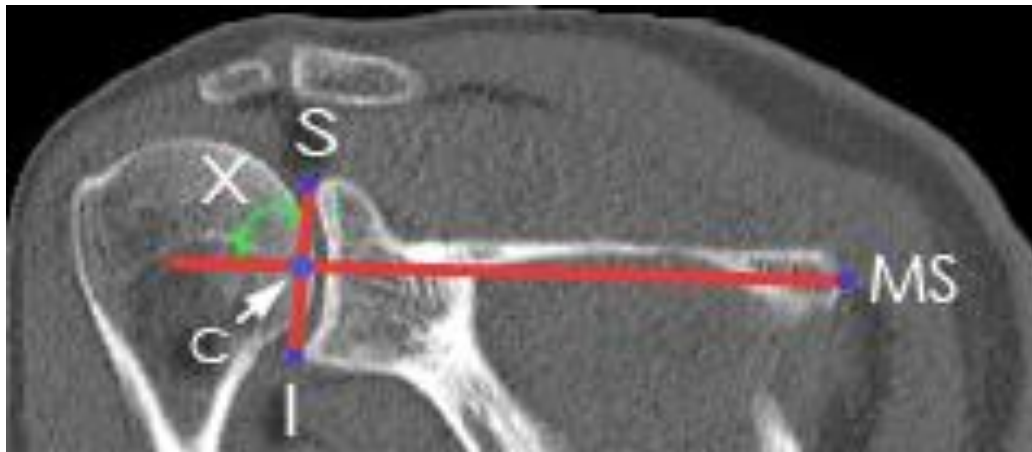


Figure 10 a :

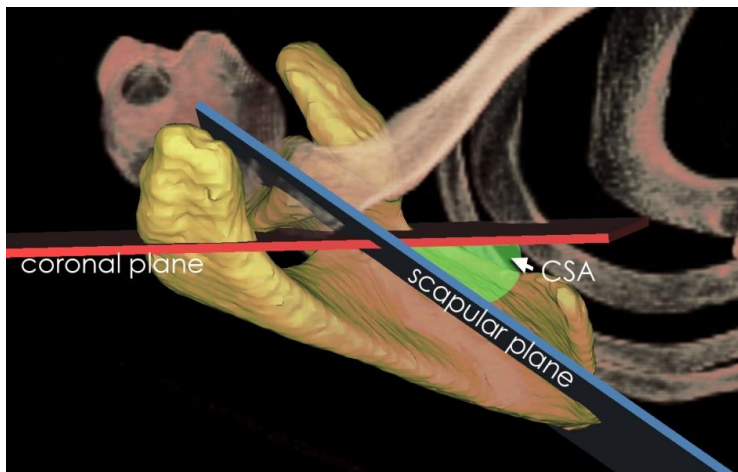


Figure 10 b :

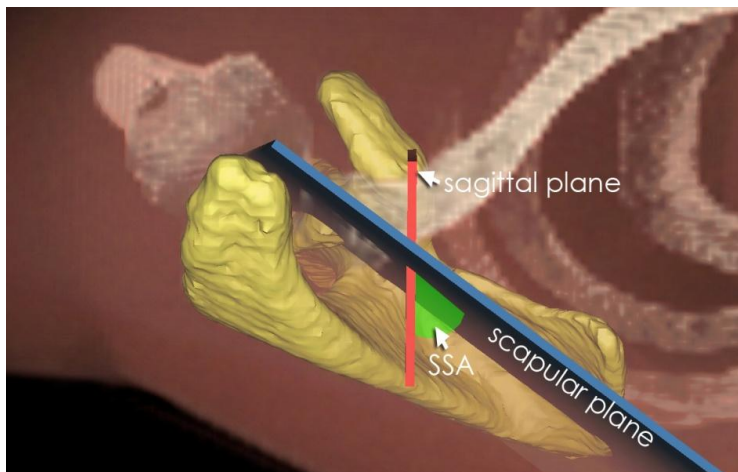


Figure 10 c :

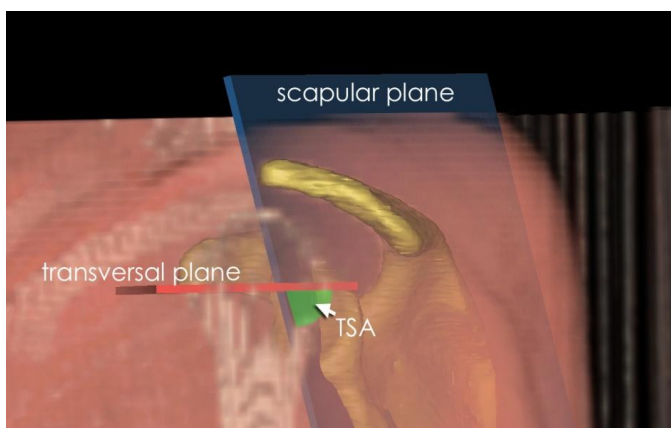


Figure 11 a :

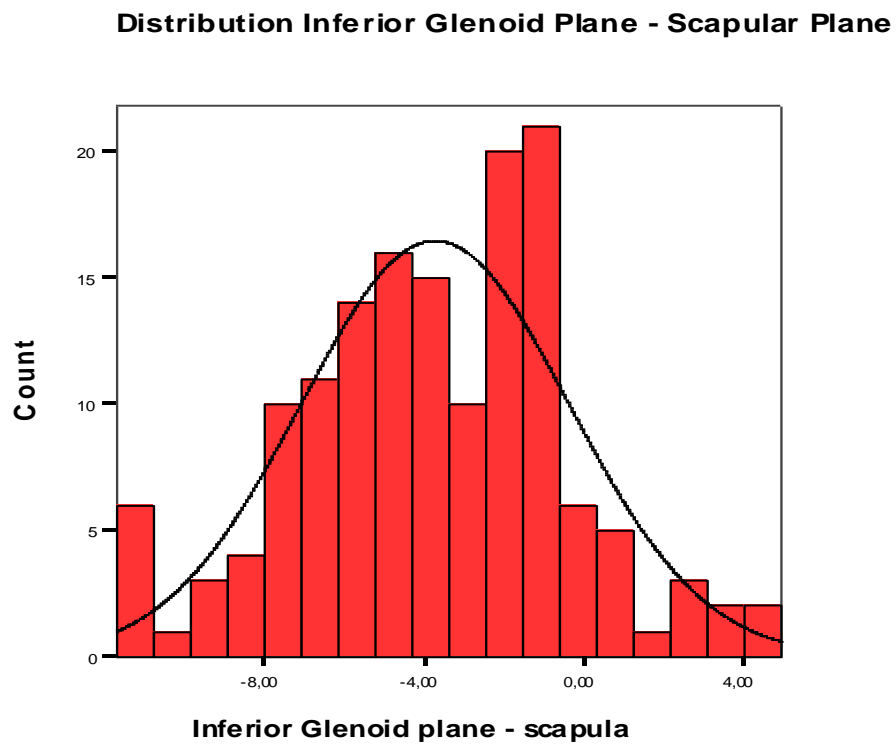


Figure 11 b :

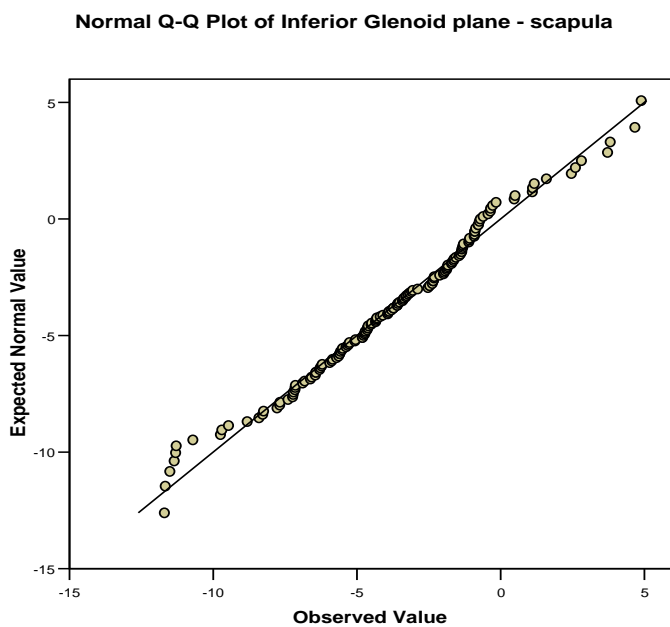


Table 1 :

Glenoid plane versus scapular plane	N	3-D Version (Degrees) Range	Minimum	Maximum	Mean	Std. Deviation
Anterior	150	28.26	.03	28.29	11.7135	5.88238
Inferior	150	16.59	-11.70	4.89	-3.7641	3.35027
Posterior	150	22.91	-25.38	-2.47	-14.0438	4.60318
Superior	150	24.27	-12.02	12.25	-2.0078	4.41418

Table 2 :

Glenoid plane versus ⊥ scapular plane	N	3-D Inclination (Degrees)	Minimum	Maximum	Mean	Std. Deviation
		Range				
Neutral	150	23.89	1.02	24.91	10.8941	4.45579
Anterior	150	25.59	.00	25.59	9.7711	4.90862
Posterior	150	26.42	.01	26.43	12.1466	4.66731
Inferior	150	31.36	5.97	37.33	21.2241	5.22018
Superior	150	25.36	-8.76	16.60	3.2625	4.80235

Table 3 :

a. Glenoid planes - Transversal plane

	N	Minimum	Maximum	Mean	Std. Deviation
Anterior glenoid vlak - transversaal vlak	150	65,6	90,0	83,054	5,0179
Inferior Glenoid vlak - transversaal vlak	150	50,3	89,7	69,202	7,1800
Posterior glenoid vlak - transversaal vlak	150	55,01	88,97	73,5167	6,90878
Superior glenoid vlak - transversaal vlak	150	69,3	90,0	83,634	4,3615
Gemiddeld glenoid vlak - transversaal	150	63,38	89,94	79,5105	6,20665
Valid N (listwise)	150				

b. Glenoid planes - Sagittal plane

	N	Minimum	Maximum	Mean	Std. Deviation
Anterior glenoid vlak - sagittaal vlak	150	31,44	78,36	54,0653	7,71738
Inferior Glenoid vlak - sagittaal vlak	150	31,7	67,3	48,254	5,8391
Posterior glenoid vlak - sagittaal vlak	150	16,75	62,14	35,3538	6,09866
Superior glenoid vlak - sagittaal vlak	150	23,27	57,88	39,0705	5,70850
Gemiddeld glenoid vlak - sagittaal	150	30,7	61,7	44,904	4,8934
Valid N (listwise)	150				

c . Glenoid planes - Coronal plane

	N	Minimum	Maximum	Mean	Std. Deviation
Anterior glenoid vlak - coronaal vlak	150	13,37	63,72	37,2932	8,00143
Inferior Glenoid vlak - coronaal vlak	150	35,79	64,83	49,8086	5,31474
Posterior glenoid vlak - coronaal vlak	150	28,28	78,97	60,6745	6,52316
Superior glenoid vlak - coronaal vlak	150	32,79	67,46	52,0086	5,84530
Gemiddeld glenoid vlak - coronaal	150	34,75	59,85	47,6495	4,66447
Valid N (listwise)	150				

Table 4 :

Angle of the Scapular plane and the coronal, sagital and transverse plane	N	Range	Minimum	Maximum	Mean	Std. Deviation
CSA	150	21.0	35.4	56.4	44.876	3.9937
SSA	150	40.33	37.72	78.05	54.4645	6.72804
TSA	150	37.97	46.59	84.56	67.6457	7.11497