

See discussions, stats, and author profiles for this publication at: <https://www.researchgate.net/publication/323537983>

Riviere 2018 EOR – SHR in OA hip patients

Article in *Open Learning* · March 2018

CITATIONS

0

READS

21

6 authors, including:



Charles Riviere

South West London Elective Orthopaedic Cen...

23 PUBLICATIONS 49 CITATIONS

SEE PROFILE



Sarah Muirhead-Allwood

1 PUBLICATION 0 CITATIONS

SEE PROFILE



Justin P Cobb

Imperial College London

200 PUBLICATIONS 3,004 CITATIONS

SEE PROFILE



Daniel Lusignan

Agence de la Santé et des Services Sociaux

8 PUBLICATIONS 325 CITATIONS

SEE PROFILE

Some of the authors of this publication are also working on these related projects:



Patient-specific techniques for joint replacement: The attractive implant positioning philosophy!

[View project](#)



resurfacing revisions [View project](#)



Spine–hip relations in patients with hip osteoarthritis

Charles Rivière^{1,2}

Stefan Lazić²

Louis Dagneaux³

Catherine Van Der Straeten⁴

Justin Cobb¹

Sarah Muirhead-Allwood⁴

- Patients with hip osteoarthritis often have an abnormal spine-hip relation (SHR), meaning the presence of a clinically deleterious spine-hip and/or hip-spine syndrome.
- Definition of the individual SHR is ideally done using the EOS[®] imaging system or, if not available, with conventional lumbopelvic lateral radiographs.
- By pre-operatively screening patients with abnormal SHR, it is possible to refine total hip replacement (THR) surgical planning, which may improve outcomes.
- An important component of the concept of kinematically aligned total hip arthroplasty (KA THA) consists of defining the optimal acetabular cup design and orientation based on the assessment of an individual's SHR, and use of the transverse acetabular ligament to adjust the cup positioning.
- The Bordeaux classification might advance the understanding of SHR and hopefully help improve THR outcomes.

Keywords: Spine–hip relation; spine–hip syndrome

Cite this article: *EFORT Open Rev* 2018;3:39-44.

DOI: 10.1302/2058-5241.3.170020

Introduction

The concept of spine-hip relation (SHR) defines the interaction between the lumbopelvic complex (LPC) and the hip joint. As the pelvis is a common anatomical structure for these two joints, changes in one joint can potentially clinically impact the other. This pathological situation is defined as the spine-hip syndrome (SHS)¹ or hip-spine syndrome (HSS),^{2,3} depending on whether the primary pathological structure is the spine or the hip, respectively. This instructional review aims to clarify and classify the SHRs that are commonly encountered in patients with hip osteoarthritis (OA).

Spino-pelvic parameters

In order to understand and define the SHR, it is important to understand the significance of the spino-pelvic parameters: sacral slope (SS), pelvic tilt (PT), pelvic incidence (PI), lumbar lordosis (LL) and the C7 plumb line (C7pl) (Fig. 1).^{4,5} SS, PT and LL are 'functional parameters', as their value varies with body position; PI is a 'morphological parameter' as it is constant for an individual; SS, PT and PI are linked by the equation $PI = SS + PT$.^{4,5} Only in health are the PI and LL usually linked ($LL = 0.54 PI + 27.6$) and the PI can be considered as a biomechanical marker to estimate the potential sagittal pelvic range of motion (ROM).⁶ Definition of an individual's sagittal balance through the assessment of these spino-pelvic parameters on standing spino-pelvic lateral images is best achieved with the EOS[®] imaging system (EOS Imaging, Biospace[®], Paris, France), or alternatively with conventional radiographs.^{1,7} The comparison of those parameters between sitting and standing lumbopelvic lateral images gives an estimate of the pelvic sagittal ROM when passing from standing to sitting position (Fig. 2).²

Abnormal SHR

A harmonious (normal) SHR occurs when a healthy flexible LPC interacts with healthy flexible hips. As soon as one of these anatomical structures becomes stiff, a clinically deleterious compensatory mechanism is often initiated by the other one. This is termed either 'spine-hip syndrome' (SHS)¹ or 'hip-spine syndrome' (HSS),^{2,3} depending on whether stiffness begins first in the lumbopelvic complex or the hip(s), respectively.

Spine-hip syndrome

The two main causes of SHS should be differentiated. One cause is ageing of the spine, which is mainly seen in the elderly, with the pelvis becoming progressively stiff and

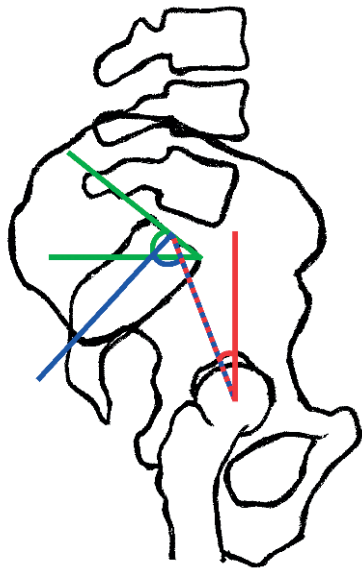


Fig. 1 The main spino-pelvic parameters: the sacral slope (green); the pelvic tilt (red); the pelvic incidence (blue).

retroverted (abnormal lumbopelvic kinematics or SHS type 2).⁸ The other involves muscular trunk imbalance, also previously described as ‘lower crossed syndrome’, and is mainly seen in young adult patients and where the pelvis displays insufficient retroversion when sitting (abnormal lumbopelvic kinematics or SHS type 1).⁹⁻¹²

Ageing of the spine, resulting mainly from degenerative disc disease and osteoporotic vertebral collapse, might affect a patient’s sagittal balance in severe cases (Fig. 3). This degenerative process causes progressive loss of lumbar lordosis and increased pelvic retroversion (SS decreases and PT increases), therefore reducing the lumbopelvic complex curvature and flexibility. In the early stages, the patient compensates for this abnormal pelvic retroversion, in the standing position, by permanently extending the hips (‘compensated stage’ with normal C7pl). However, with progressive ageing of the spine, this compensatory mechanism becomes ineffective and the patient starts to become sagittally imbalanced as shown by the excessively anterior C7pl (‘decompensated stage’).^{8,13} A sagittal imbalance substantially affects the quality of life and can be clinically deleterious¹⁴⁻¹⁶ because, when standing, the patient has to hyperextend the neck in order to keep a horizontal sightline, and the hips are at risk of OA secondary to aberrant standing functional acetabular orientation, under-coverage of the femoral head anteriorly and posterior impingement.^{17,18} With THA, implants would therefore be at a higher risk of failure, notably through complications related to edge-loading and anterior prosthetic instability.^{1,19-26} This SHS type 2 appears to be frequent (26% to 40%) in patients scheduled for primary THA.^{8,18}

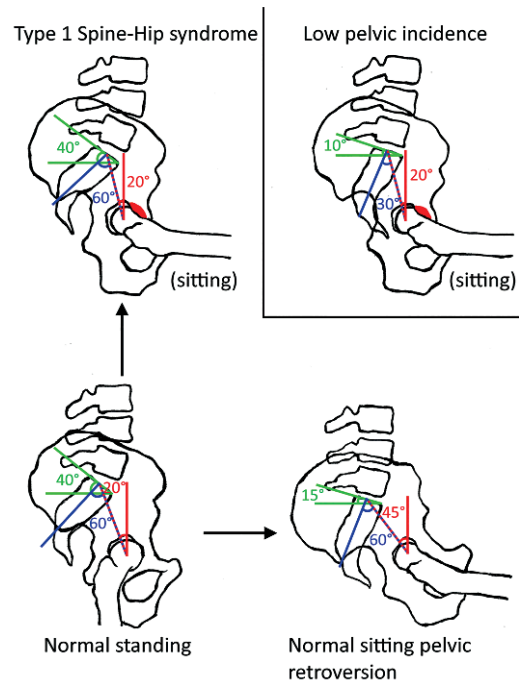


Fig. 2 The ways in which an abnormal SHR can contribute to femoro-acetabular impingement (red) due to abnormal lumbopelvic kinematics (SHS type 1, top left) or a low pelvic incidence (top right). With healthy interaction between the flexible LPC and flexible hips, femoro-acetabular impingement is less likely to occur (bottom right).

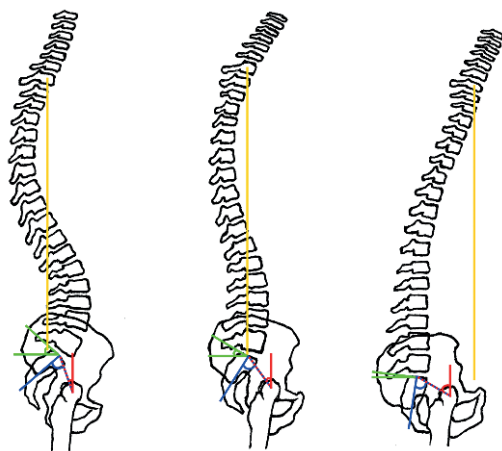


Fig. 3 Type 2 SHS resulting from ageing (from left to right) of the spine. C7 plumb line in yellow.

Muscular trunk imbalance can lead to paradoxically poor pelvic retroversion when a patient sits or squats, thus leading to an aberrant sitting functional acetabular orientation responsible for femoral head over-coverage and anterior impingement (Fig. 2).²⁷⁻²⁹ This would probably predispose to hip OA in native hips, and posterior

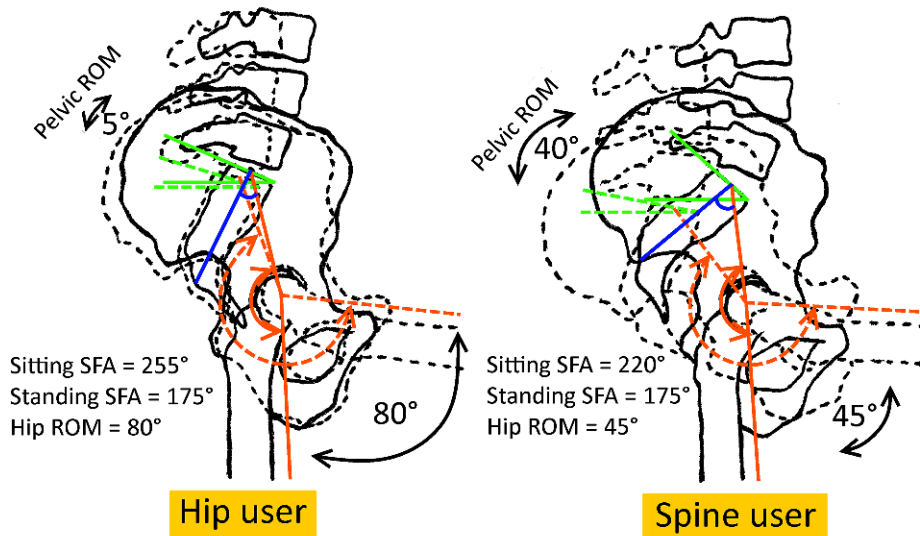


Fig. 4 Relationship between spine and kinematics. Note the larger hip cone of mobility (demonstrated with the larger sacro-femoral angle in orange) of a ‘hip user’, compared to a ‘spine user’ with a larger pelvic ROM but a smaller hip cone of mobility.

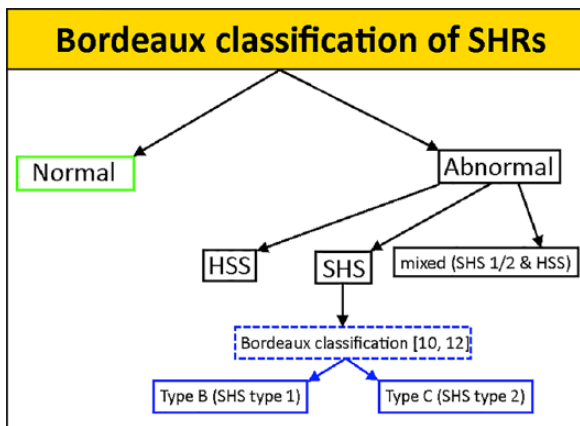


Fig. 5 The Bordeaux classification of SHRs.

instability and posterior edge-loading in prosthetic hips. The origin of these abnormal lumbopelvic kinematics is unknown. The diagnosis is made on lumbopelvic lateral images showing $< 10^\circ$ decrease in pelvic retroversion³⁰ between standing and sitting positions (Fig. 2).

In addition to the aforementioned pathological types of lumbopelvic sagittal kinematics, variation in PI can also affect THR outcomes in patients with a very small PI ($< 35^\circ$) by increasing the risk of edge-loading and instability (Fig. 2).³¹ Patients with a very small PI are considered to have a ‘patho-anatomy’ and are likely to have a small sagittal pelvic ROM when sitting or squatting, therefore making them use more of each hip’s cone of mobility (hip users, Fig. 4).^{10,12} In contrast, patients with a large PI and sagittal pelvic ROM would use less of each hip’s cone of mobility (spine users, Fig. 4). A classification of SHRs based

on the assessment of the individual PI and SHS has recently been published under the Bordeaux classification (Fig. 5).^{10,12}

Hip-spine syndrome

Hip OA is known to affect hip mobility/flexibility secondary to the generation of articular impingement through osteophytosis and/or contracture of the capsule. The lumbopelvic complex will therefore in return compensate for this hip stiffness with increasing lumbar lordosis of the spine (abnormal standing functional lordosis) in cases of fixed flexion deformity of the hip, in order to allow the patient to stand upright. This lumbopelvic compensation is likely to be clinically deleterious by causing degeneration of the spine and its associated complications (low back pain, etc.).³² HSS can be clinically tested with physical examination by performing Thomas’ test to compare both hips (the degenerated and the healthy contralateral) and a radiographic ‘extension test’ with EOS® imaging to measure the sacro-femoral angles (Fig. 4).³³ The discrepancy between degenerated and healthy hips enables the surgeon to discriminate between SHS and HSS; that is to say that both sides are likely to be affected in type 2 SHS but only one leg is likely to be affected in HSS due to unilateral OA.³⁰

The Bordeaux classification of SHRs

As illustrated in Figure 5, hip OA patients can display various SHRs that we have classified as normal or abnormal, HSS or SHS, or a combination of the two. The Bordeaux classification, aiming at classifying the SHRs with SHS has recently been published.^{10,12}

Clinical implications

SHS is a cause of hip OA, which in turn can aggravate the spine by way of a HSS. SHS and HSS are frequently seen in patients awaiting THA,^{8,18} and pre-operatively screening patients with abnormal SHR could refine the surgical planning and therefore THA outcomes. In patients with HSS, anterior capsule release could provide back pain relief and help with better hip balancing and leg length adjustment. SHS patients, by contrast, may benefit from corrective spinal surgery before the hip replacement.³⁴⁻³⁶ Patients with SHS usually present with a stiffer LPC, which makes those patients mainly 'hip users' in situations of aberrant functional acetabular orientation,^{10,12} increasing the risk of edge-loading and articular impingement (on a native or prosthetic hip). In order to face this aberrant functional acetabular orientation and prevent those complications happening, it seems reasonable to first use a higher tolerance implant (larger diameter head, dual mobility)²⁵ and second, to determine a personalised cup orientation.^{10,17,37,38} This relates to the concept of kinematically aligned total hip arthroplasty (KA THA), which has recently been promoted by Riviere et al.¹⁰ In contrast with the attractive but costly optimized positioning system[®] (Corin, Cirencester, UK),^{39,40} the authors suggest a simple, low-cost and fast way to achieve patient-specific implant positioning by defining the optimal acetabular cup design and orientation based on the individual SHR.¹⁰ In order to improve the positioning of the cup, the surgeon must first pre-operatively define an optimal cup orientation^{7,11,18,41,42} based on the assessment of the individual dynamic functional acetabular orientation,^{36,37} and second, intra-operatively precisely position the acetabular cup, ideally by simply using the transverse acetabular ligament (TAL). Aligning the cup with the TAL has been shown to be clinically safe and effective⁴³ and to lead to better standing cup orientation,⁴⁴ even in cases of hip dysplasia.⁴⁵ If needed, the TAL is also a relevant anatomical landmark with which to adjust the cup anteversion as it enables reproduction of both the anatomical and functional acetabular anteversion of an individual. This would therefore restore the individual acetabular cone of mobility and, as modern hip implants have a head-neck ratio higher than the native hip, would probably prevent articular impingement.²⁵ Regarding the cup inclination, a surgeon can adjust this by fine-tuning the position of the cup with the TAL or the length of the uncovered roof part of the cup.

Conclusions

Patients with hip OA often have an abnormal SHR, meaning the presence of clinically deleterious SHS and/or HSS. In order to refine surgical planning in THA, it is important to define the individual SHR by ideally using the EOS imaging system[®] or, alternatively, conventional spino-pelvic

lateral radiographs. This would enable screening for patients with abnormal SHR (SHS and/or HSS) for which intra-operative solutions exist. The concept of KA THA consists of defining the optimal acetabular cup design and orientation based on the assessment of the individual SHR/pelvic kinematics, and using the TAL to adjust cup positioning. The Bordeaux classification might improve the understanding of SHR and hopefully help in improving THA outcomes.

AUTHOR INFORMATION

¹MSK Lab, Imperial College London, UK.

²South West London Elective Orthopaedic Centre, UK.

³CHU de Montpellier, France.

⁴London Hip Unit, UK.

Correspondence should be sent to: C. Rivière, MSK Lab, Charing Cross Campus, Laboratory Block, Imperial College London, London W6 8RP, UK.

Email: c.riviere@imperial.ac.uk

ICMJE CONFLICT OF INTEREST STATEMENT

C. Rivière declares payment for lectures for Medacta, activity outside the submitted work. L. Dagneaux declares grant(s) from SOFCOT, activity outside the submitted work. C. Van Der Straeten declares board membership of ISTA; expert testimony for regulatory authorities, activity outside the submitted work. J. Cobb declares consultancy for Biomet-Zimmer and Mathortho; fees from Microport, activity outside the submitted work. S. Muirhead-Allwood declares royalties from Corin, DePuy, Zimmer, activity outside the submitted work.

FUNDING STATEMENT

No benefits in any form have been received or will be received from a commercial party related directly or indirectly to the subject of this article.

LICENCE

© 2018 The author(s)

This article is distributed under the terms of the Creative Commons Attribution-Non Commercial 4.0 International (CC BY-NC 4.0) licence (<https://creativecommons.org/licenses/by-nc/4.0/>) which permits non-commercial use, reproduction and distribution of the work without further permission provided the original work is attributed.

REFERENCES

- Lazennec JY, Brusson A, Rousseau MA.** Hip-spine relations and sagittal balance clinical consequences. *Eur Spine J* 2011;20(S5):686-98.
- Lazennec JY, Brusson A, Rousseau MA.** Lumbar-pelvic-femoral balance on sitting and standing lateral radiographs. *Orthop Traumatol Surg Res* 2013;99:S87-S103.
- Redmond JM, Gupta A, Hammarstedt JE, Stake CE, Domb BG.** The hip-spine syndrome: how does back pain impact the indications and outcomes of hip arthroscopy? *Arthroscopy* 2014;30:872-81.
- Legaye J, Duval-Beaupère G, Hecquet J, Marty C.** Pelvic incidence: a fundamental pelvic parameter for three-dimensional regulation of spinal sagittal curves. *Eur Spine J* 1998;7:99-103.

5. **Duval-Beaupère G, Schmidt C, Cosson P.** A Barycentremetric study of the sagittal shape of spine and pelvis: the conditions required for an economic standing position. *Ann Biomed Eng* 1992;20:451–62.
6. **LeHuec JC, Hasegawa K.** Normative values for the spine shape parameters using 3D standing analysis from a database of 268 asymptomatic Caucasian and Japanese subjects. *Eur Spine J* 2016;25:3630–7.
7. **Phan D, Bederman SS, Schwarzkopf R.** The influence of sagittal spinal deformity on anteversion of the acetabular component in total hip arthroplasty. *Bone Joint J* 2015;97-B:1017–23.
8. **Espósito CI, Miller TT, Kim HJ, et al.** Does degenerative lumbar spine disease influence femoroacetabular flexion in patients undergoing total hip arthroplasty? *Clin Orthop Relat Res* 2016;474:1788–97.
9. **Pierrepont JW, Feyen H, Miles BP, et al.** Functional orientation of the acetabular component in ceramic-on-ceramic total hip arthroplasty and its relevance to squeaking. *Bone Joint J* 2016;98-B:910–6.
10. **Rivière C, Lazennec JY, Van Der Straeten C, et al.** The influence of spine-hip relations on total hip replacement: A systematic review. *Orthop Traumatol Surg Res* 2017;103:559–68.
11. **Kanawade V, Dorr LD, Wan Z.** Predictability of acetabular component angular change with postural shift from standing to sitting position. *J Bone Joint Surg Am* 2014;96:978–86.
12. **Rivière C, Hardijzer A, Lazennec JY, et al.** Spine-hip relations add understandings to the pathophysiology of femoro-acetabular impingement: A systematic review. *Orthop Traumatol Surg Res* 2017;103:549–57.
13. **Rousseau MA, Lazennec JY, Boyer P, et al.** Optimization of total hip arthroplasty implantation: is the anterior pelvic plane concept valid? *J Arthroplasty* 2009;24:22–6.
14. **Bendaya S, Anglin C, Lazennec JY, et al.** Good vs poor results after total hip arthroplasty: an analysis method using implant and anatomic parameters with the EOS imaging system. *J Arthroplasty* 2016;31:2043–52.
15. **Ochi H, Homma Y, Baba T, et al.** Sagittal spinopelvic alignment predicts hip function after total hip arthroplasty. *Gait Posture* 2017;52:293–300.
16. **Gu M, Zhang Z, Kang Y, et al.** Roles of sagittal anatomical parameters of the pelvis in primary total hip replacement for patients with ankylosing spondylitis. *J Arthroplasty* 2015;30:2219–23.
17. **McCarthy TF, Alipit V, Nevelos J, Elmallah RK, Mont MA.** Acetabular cup anteversion and inclination in hip range of motion to impingement. *J Arthroplasty* 2016;31(suppl):264–8.
18. **Stefl M, Lundergan W, Heckmann N, et al.** Spinopelvic mobility and acetabular component position for total hip arthroplasty. *Bone Joint J* 2017;99-B(suppl A):37–45.
19. **Bedard NA, Martin CT, Slaven SE, et al.** Abnormally high dislocation rates of total hip arthroplasty after spinal deformity surgery. *J Arthroplasty* 2016;31:2884–5.
20. **Sing DC, Barry JJ, Aguilar TU, et al.** Prior lumbar spinal arthrodesis increases risk of prosthetic-related complication in total hip arthroplasty. *J Arthroplasty* 2016;31(Suppl):227–32.
21. **Barry JJ, Sing DC, Vail TP, Hansen EN.** Early outcomes of primary total hip arthroplasty after prior lumbar spinal fusion. *J Arthroplasty* 2017;32:470–4.
22. **Furuhashi H, Togawa D, Koyama H, et al.** Repeated posterior dislocation of total hip arthroplasty after spinal corrective long fusion with pelvic fixation. *Eur Spine J* 2017;26(suppl 1):100–6.
23. **Perfetti DC, Schwarzkopf R, Buckland AJ, Paulino CB, Vigdorich JM.** Prosthetic dislocation and revision after primary total hip arthroplasty in lumbar fusion patients: a propensity score matched-pair analysis. *J Arthroplasty* 2017;32:1635–40.
24. **DeSole EM, Vigdorich JM, Schwarzkopf R, Errico TJ, Buckland AJ.** Total hip arthroplasty in the spinal deformity population: does degree of sagittal deformity affect rates of safe zone placement, instability, or revision? *J Arthroplasty* 2017;32:1910–7.
25. **Miki H, Kyo T, Kuroda Y, Nakahara I, Sugano N.** Risk of edge-loading and prosthesis impingement due to posterior pelvic tilting after total hip arthroplasty. *Clin Biomech (Bristol, Avon)* 2014;29:607–13.
26. **Tezuka T, Inaba Y, Kobayashi N, et al.** Influence of pelvic tilt on polyethylene wear after total hip arthroplasty. *BioMed Res Int* 2015;2015:327217.
27. **Ng KC, Lamontagne M, Adamczyk AP, Rakhra KS, Beaulé PE.** Patient-specific anatomical and functional parameters provide new insights into the pathomechanism of cam FAI. *Clin Orthop Relat Res* 2015;473:1289–96.
28. **Lamontagne M, Kennedy MJ, Beaulé PE.** The effect of cam FAI on hip and pelvic motion during maximum squat. *Clin Orthop Relat Res* 2009;467:645–50.
29. **Bagwell JJ, Snibbe J, Gerhardt M, Powers CM.** Hip kinematics and kinetics in persons with and without cam femoroacetabular impingement during a deep squat task. *Clin Biomech (Bristol, Avon)* 2016;31:87–92.
30. **Kanawade V, Dorr LD, Wan Z.** Predictability of acetabular component angular change with postural shift from standing to sitting position. *J Bone Joint Surg Am* 2014;96:978–86.
31. **Prather H, Cheng A, Steger-May K, Maheshwari V, Van Dillen L.** Hip and lumbar spine physical examination findings in people presenting with low back pain, with or without lower extremity pain. *J Orthop Sports Phys Ther* 2017;47:163–72.
32. **Gebhart JJ, Weinberg DS, Bohl MS, Liu RW.** Relationship between pelvic incidence and osteoarthritis of the hip. *Bone Joint Res* 2016;5:66–72.
33. **Lazennec JY, Brusson A, Folinais D, et al.** Measuring extension of the lumbar-pelvic-femoral complex with the EOS® system. *Eur J Orthop Surg Traumatol* 2015;25:1061–8.
34. **Masquefa T, Verdier N, Gille O, et al.** Change in acetabular version after lumbar pedicle subtraction osteotomy to correct post-operative flat back: EOS® measurements of 38 acetabula. *Orthop Traumatol Surg Res* 2015;101:655–9.
35. **Hu J, Qian BP, Qiu Y, et al.** Can acetabular orientation be restored by lumbar pedicle subtraction osteotomy in ankylosing spondylitis patients with thoracolumbar kyphosis? *Eur Spine J* 2017;26:1826–32.
36. **Buckland AJ, Vigdorich J, Schwab FJ, et al.** Acetabular anteversion changes due to spinal deformity correction: bridging the gap between hip and spine surgeons. *J Bone Joint Surg Am* 2015;97:1913–20.
37. **Mellon SJ, Grammatopoulos G, Andersen MS, et al.** Optimal acetabular component orientation estimated using edge-loading and impingement risk in patients with metal-on-metal hip resurfacing arthroplasty. *J Biomech* 2015;48:318–23.
38. **Laffargue P, Pinoit Y, Tabutin J, et al.** Positionnement de la cupule d'une prothèse totale de hanche par navigation sans image basée sur la cinématique articulaire. *Rev Chir Orthop Reparatrice Appar Mot* 2006;92:316–25.
39. **Parratte S, Argenson JN.** Validation and usefulness of a computer-assisted cup-positioning system in total hip arthroplasty. A prospective, randomized, controlled study. *J Bone Joint Surg Am* 2007;89:494–9.
40. **Buller L, Smith T, Bryan J, et al.** The use of patient-specific instrumentation improves the accuracy of acetabular component placement. *J Arthroplasty* 2013;28:631–6.

- 41. Blizzard DJ, Nickel BT, Seyler TM, Bolognesi MP.** The impact of lumbar spine disease and deformity on total hip arthroplasty outcomes. *Orthop Clin North Am* 2016;47:19-28.
- 42. Putnis SE, Wartemberg GK, Khan WS, Agarwal S.** A literature review of total hip arthroplasty in patients with ankylosing spondylitis: perioperative considerations and outcome. *Open Orthop J* 2015;9:483-8.
- 43. Archbold HA, Mockford B, Molloy D, et al.** The transverse acetabular ligament: an aid to orientation of the acetabular component during primary total hip replacement: a preliminary study of 1000 cases investigating postoperative stability. *J Bone Joint Surg [Br]* 2006;88-B:883-6.
- 44. Meermans G, Van Doorn WJ, Koenraadt K, Kats J.** The use of the transverse acetabular ligament for determining the orientation of the components in total hip replacement: a randomised controlled trial. *Bone Joint J* 2014;96-B:312-8.
- 45. Miyoshi H, Mikami H, Oba K, Amari R.** Anteversion of the acetabular component aligned with the transverse acetabular ligament in total hip arthroplasty. *J Arthroplasty* 2012;27:916-22.