

Haemorrhagic enteritis in newborn calves associated with *Clostridium perfringens* and colostrum delivery

Bonnie R. Valgaeren,¹ Bart Pardon,¹ Stefanie Verherstraeten,² Evy Goossens,² Leen Timbermont,² Freddy Haesebrouck,² Richard Ducatelle,² Filip Van Immerseel² and Piet Deprez¹

Correspondence
Bonnie R. Valgaeren
Bonnie.Valgaeren@Ugent.Be

¹Department of Large Animal Internal Medicine, Faculty of Veterinary Medicine, Ghent University, Salisburylaan 133, B-9820 Merelbeke, Belgium

²Department of Pathology, Bacteriology and Poultry Diseases, Faculty of Veterinary Medicine, Ghent University, Salisburylaan 133, B-9820 Merelbeke, Belgium

Introduction: This report describes 13 cases of fatal haemorrhagic enteritis in newborn calves.

Case presentation: *Clostridium perfringens* type A was isolated both from the intestinal contents of seven calves and from three visibly worn and soiled bucket teats and stomach tubes used for colostrum administration. After replacement of the colostrum delivery device and introduction of hygienic measures, no new cases appeared on any of the farms.

Conclusion: The results suggested that contamination of colostrum with *C. perfringens* caused these cases of neonatal haemorrhagic enteritis.

Keywords: *Clostridium perfringens*; colostrum delivery; haemorrhagic enteritis; hygiene.

Received 3 December 2014
Accepted 1 August 2015

Clostridium perfringens is a spore-forming bacterium, and is divided into five types (A–E), based on the major toxins produced (Songer, 1996). Type A strains are predominantly isolated from calves with clostridial problems, such as haemorrhagic abomasitis in newborn calves and haemorrhagic enteritis in older calves (Roeder *et al.*, 1988; Songer & Miskimins, 2005; Miyashiro *et al.*, 2009; Valgaeren *et al.*, 2013b). In these older calves, recent experimental studies have suggested that α -toxin and perfringolysin are the primary toxins in the development of haemorrhagic intestinal lesions (Verherstraeten *et al.*, 2013). Although *C. perfringens* is an anaerobic bacterium, spores survive in the presence of oxygen, explaining its ubiquitous presence in the environment and in faeces (Songer, 1996, 2006; Van Kruiningen *et al.*, 2009). Only one author has suggested a link between clostridial abomasal disease and insufficient hygiene of colostrum and feeding utensils; however, the presence of *C. perfringens* strains on these potential carriers has not yet been provided (Songer, 2006). This case report describes colostrum contamination by the presence of *C. perfringens* in colostrum administration utensils.

Case report

Over 4 years, 13 cases of haemorrhagic enteritis in newborn calves were observed on six farms (Table 1). One case only occurred on a dairy farm in a Holstein Friesian

(HF) calf, while multiple cases occurred within a 3-week period on four of the five Belgian Blue (BB) farms. Clinical signs started 4–24 h after birth and consisted of anorexia, colic, shock, severe acidosis, apathy, pale mucosae, swollen abdomen, and melena or absence of faeces. Some calves were hypothermic, while others had fever (range 35.4–39.8 °C). All calves died within 3–30 h after onset of signs, despite treatment with penicillin in several cases. A glutaraldehyde coagulation test (Beetson *et al.*, 1985) was performed on sera of six calves from four different farms and revealed insufficient immunoglobulin levels ($<6 \text{ g l}^{-1}$) in all of them. Necropsy, performed on 10 of the 13 calves, revealed small intestinal haemorrhagic enteritis. In four cases, abomasitis was also present, and three other cases had haemorrhagic typhlocolitis. Histology confirmed necrohaemorrhagic enteritis, similar to the lesions seen in enterotoxaemia cases in older calves (Valgaeren *et al.*, 2013a) (Fig. 1). In one calf, histology revealed gas bubbles in the submucosa and lamina propria of the mucosa, as well as thrombi in the blood vessels of the submucosa. In seven calves, intestinal content was sampled between 10 min and 24 h after death. An overgrowth of *C. perfringens* ($>10^8 \text{ c.f.u. g}^{-1}$) was consistently present on Columbia agar (Oxoid) supplemented with 5 % defibrinated sheep blood. On four farms, all calves had received 2–4 l colostrum by stomach tube immediately after birth. In the other farms, calves were bucket-fed 2 l fresh colostrum from their dam immediately after birth. None of

Abbreviations: BB, Belgian Blue; HF, Holstein Friesian.

Table 1. Cases of haemorrhagic enteritis in neonatal calves

Case	Farm	Time period	Breed	Means of administration of colostrum	Necropsy results	Culture of teat	Culture of intestinal content
1	1	October 2011	BB	Stomach tube	–	–	–
2	1	October 2011	BB	Stomach tube	Haemorrhagic enteritis	–	–
3	1	October 2011	BB	Stomach tube	Necrohaemorrhagic abomasitis and enteritis	–	One strain: type A, $\beta 2^-$
4	1	November 2011	BB	Stomach tube	Haemorrhagic enterotyphlocolitis	–	One strain: type A, $\beta 2^-$
5	2	July 2012	BB	Stomach tube	Haemorrhagic enteritis	–	–
6	2	July 2012	BB	Stomach tube	Necrohaemorrhagic enteritis	Negative	Four strains: type A, $\beta 2^-$
7	3	May 2013	HF	Stomach tube	Necrohaemorrhagic abomasitis and enteritis	Five strains: type A, $\beta 2^-$	Five strains: type A, $\beta 2^-$
8	4	August 2013	BB	Bucket	–	–	–
9	4	August 2013	BB	Bucket	–	–	–
10	4	August 2013	BB	Bucket	Haemorrhagic enteritis	Five strains: type A, $\beta 2^-$	Five strains: type A, $\beta 2^-$
11	5	January 2014	BB	Bucket	Segmental haemorrhagic enteritis	–	–
12	5	January 2014	BB	Bucket	Necrohaemorrhagic abomasitis, haemorrhagic ruminitis and haemorrhagic enterotyphlocolitis	–	Five strains: type A, $\beta 2^-$
13	6	June 2014	BB	Stomach tube	Necrohaemorrhagic abomasitis and enteritis	Two strains: type A, $\beta 2^-$	20 strains: type A, $\beta 2^-$; 2 strains: type A, $\beta 2^+$

the farmers disinfected the tube or bucket teats between calves. On several farms, teats and stomach tubes were visibly contaminated with milk residues. On farms 2, 3 and 6, swabs were taken from the stomach tubes and on farm 4, swabs were taken from the bucket teat. *C. perfringens* was isolated from the feeding utensils on three out of the four farms. Forty-three strains from the abomasal and intestinal contents of seven calves on six farms and 12 strains from the tubes and teats were typed by multiplex PCR (Gholamiandekordi *et al.*, 2006) and were identified as type A *C. perfringens*. Only two strains from the intestinal content of one calf were positive for the $\beta 2$ -toxin gene. Randomly amplified polymorphic DNA analysis (Leflon-Guibout *et al.*, 1997) showed that the investigated isolates were all different strains. Apart from the tubes and teats, two colostrum samples were tested from farm 4, of which one was negative and the other was positive for *C. perfringens*. Herdsmen were advised to replace the stomach tubes and bucket teats, to clean and disinfect with 3% hydrogen peroxide between calves, and to avoid contamination of colostrum during collection and storage (in a refrigerator). No new cases occurred on any of the six farms after the implementation of these precautions.

Discussion

This report demonstrated that *C. perfringens* strains can be detected in colostrum and utensils used for colostrum

delivery. Ingested clostridial spores can become vegetative in the abomasum and intestine. The high abomasal pH and the lack of a competitive microbiota can lead to clostridial overgrowth and toxin production (Songer, 2006; Lukás *et al.*, 2007). Colostrum has a trypsin-inhibitory activity, which can protect both α -toxin and perfringolysin

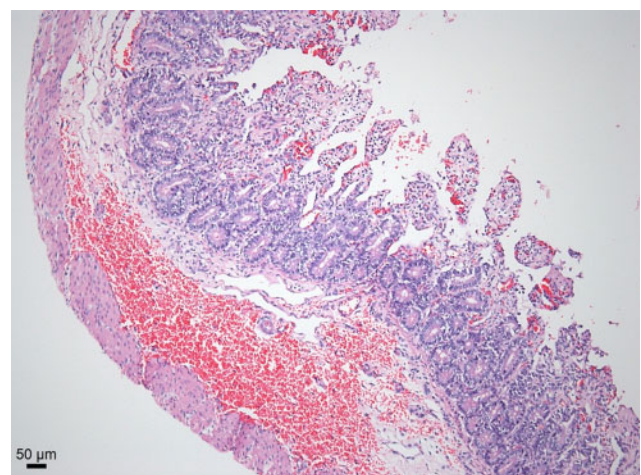


Fig. 1. Small intestine of a case of haemorrhagic enterotyphlocolitis (case 4). Haematoxylin and eosin staining. In the luminal half of the mucosa, there is necrosis, infiltration with neutrophils, hyperaemia and haemorrhage.

against enzymic degradation, possibly facilitating the development of haemorrhagic intestinal lesions (Quigley *et al.*, 1995; Uzal *et al.*, 2010; Diab *et al.*, 2012). From the 43 strains isolated from the abomasal and intestinal content of the calves, only two were positive for atypical β -toxin, and none was positive for consensus β -toxin. Consensus β -toxin has been suggested as to make an important contribution to haemorrhagic enteritis in older calves (Lebrun *et al.*, 2007). However, recent studies have shown that any *C. perfringens* strain can induce necrohaemorrhagic lesions in calves and that α -toxin and perfringolysin are probably the predominant virulence factors (Valgaeren *et al.*, 2013a; Verherstraeten *et al.*, 2013). Thus, similar to the situation in older calves, β -toxin does not seem to be of importance in neonatal haemorrhagic enteritis. There are comparable numbers of BB and HF calves in Belgium. However, only one case was seen in a HF calf, in contrast to the 12 cases seen in BB calves. On the BB farms, multiple cases occurred in a short period of time, while the HF case was solitary. This suggests that BB calves are predisposed to haemorrhagic enteritis, as has already been confirmed in the veal industry (Pardon *et al.*, 2012). The reasons for this predilection are not clear, and might be genetic, management related, feed related or some combination of these. The IgG content of the delivered colostrum was not known. Normally in BB calves, 2 l colostrum from their dams should be sufficient to provide 200 g immunoglobulins, but the five examined calves were hypogammaglobulinaemic (Hoflack *et al.*, 2004). It is possible that the disease described here decreased absorption. The problem was completely resolved after replacement and systematic cleaning and disinfection (e.g. using hydrogen peroxide) of the tubes and teats used for colostrum feeding (Venczel *et al.*, 1997). The present observations suggest that the uptake of *C. perfringens* from the use of contaminated teats or tubes is a cause of abomasitis and haemorrhagic enteritis. The strains isolated from the feeding utensils were not identical to those isolated from the intestines of diseased calves. The required number of strains that should be examined in order to be 95 % confident that all strains present have been covered is not known. Possibly, and probably, too few strains were tested. Further work is necessary to elaborate the means of transfer of clostridial strains to neonates.

In conclusion, the present report demonstrated *C. perfringens* in colostrum and utensils used for colostrum delivery, suggesting a possible source of infection for neonatal haemorrhagic enteritis. More work on a larger number of strains isolated from the intestines of cases and from colostrum delivery devices is necessary to definitively confirm the current observations. Experimental infection of newborn calves through administration of *C. perfringens*-contaminated colostrum is necessary to definitively confirm this route of infection. Based on the observations in these cases, to avoid haemorrhagic enteritis in newborns, we suggest that attention should be paid to hygienic administration of colostrum and proper disinfection of colostrum tubes and teats.

Acknowledgements

The authors acknowledge the help of the supporting staff from the laboratories of pathology, bacteriology and internal medicine, as well as the role of the farmers and field veterinarians in providing us with the calves, used teats and tubes, and case information.

References

- Beetson, S. A., Hilbert, B. J. & Mills, J. N. (1985). The use of the glutaraldehyde coagulation test for detection of hypogammaglobulinaemia in neonatal foals. *Aust Vet J* **62**, 279–281.
- Diab, S. S., Kinde, H., Moore, J., Shahriar, M. F., Odani, J., Anthenill, L., Songer, G. & Uzal, F. A. (2012). Pathology of *Clostridium perfringens* type C enterotoxaemia in horses. *Vet Pathol* **49**, 255–263.
- Gholamiandekhordi, A. R., Ducatelle, R., Heyndrickx, M., Haesebrouck, F. & Van Immerseel, F. (2006). Molecular and phenotypical characterization of *Clostridium perfringens* isolates from poultry flocks with different disease status. *Vet Microbiol* **113**, 143–152.
- Hoflack, G., Laureyns, J., Dewulf, J., Opsomer, G. & de Kruijff, A. (2004). Colostrum quality and quantity in Belgian Blue cows and the subsequent maternal immunity. In *Poster Abstracts of the 23rd World Buiatrics Congress*, Quebec City, Canada.
- Lebrun, M., Filée, P., Mousset, B., Desmecht, D., Galleni, M., Mainil, J. G. & Linden, A. (2007). The expression of *Clostridium perfringens* consensus (2 toxin is associated with bovine enterotoxaemia syndrome. *Vet Microbiol* **120**, 151–157.
- Leflon-Guibout, V., Pons, J. L., Heym, B. & Nicolas-Chanoine, M. H. (1997). Typing of *Clostridium perfringens* strains by use of random amplified polymorphic DNA (RAPD) system in comparison with zymotyping. *Anaerobe* **3**, 245–250.
- Lukás, F., Koppová, I., Kudrna, V. & Kopečný, J. (2007). Postnatal development of bacterial population in the gastrointestinal tract of calves. *Folia Microbiol (Praha)* **52**, 99–104.
- Miyashiro, S., Baldassi, L. & Nassar, A. F. C. (2009). Genotyping of *Clostridium perfringens* associated with sudden death in cattle. *J Venom Anim Toxins Incl Trop Dis* **15**, 491–497.
- Pardon, B., De Bleeker, K., Hostens, M., Callens, J., Dewulf, J. & Deprez, P. (2012). Longitudinal study on morbidity and mortality in white veal calves in Belgium. *BMC Vet Res* **8**, 26.
- Quigley, J. D. III, Martin, K. R. & Dowlen, H. H. (1995). Concentrations of trypsin inhibitor and immunoglobulins in colostrum of Jersey cows. *J Dairy Sci* **78**, 1573–1577.
- Roeder, B. L., Chengappa, M. M., Nagaraja, T. G., Avery, T. B. & Kennedy, G. A. (1988). Experimental induction of abdominal tympany, abomasitis, and abomasal ulceration by intraruminal inoculation of *Clostridium perfringens* type A in neonatal calves. *Am J Vet Res* **49**, 201–207.
- Songer, J. G. (1996). Clostridial enteric diseases of domestic animals. *Clin Microbiol Rev* **9**, 216–234.
- Songer, J. G. (2006). Bovine enteritis and enterotoxaemia. In *Clostridia in Medical, Veterinary and Food Microbiology, Diagnosis and Typing*, pp. 51–57. Edited by J. Mainil, C. Duchesnes, P. E. Granum, M. G. Menozzi, M. Peck, S. Pelkonen, M. Popoff, E. Stackebrandt & R. Titball. Brussels, Belgium: European Commission, Directorate-General for Research, Directorate E- Biotechnology, Agriculture and Food.
- Songer, J. G. & Miskimins, D. W. (2005). Clostridial abomasitis in calves: case report and review of the literature. *Anaerobe* **11**, 290–294.

Uzal, F. A., Vidal, J. E., McClane, B. A. & Gurjar, A. A. (2010). *Clostridium perfringens* toxins involved in mammalian veterinary diseases. *Open Toxinology J* 2, 24–42.

Valgaeren, B., Pardon, B., Goossens, E., Verherstraeten, S., Schauvliege, S., Timbermont, L., Ducatelle, R., Deprez, P. & Van Immerseel, F. (2013a). Lesion development in a new intestinal loop model indicates the involvement of a shared *Clostridium perfringens* virulence factor in haemorrhagic enteritis in calves. *J Comp Pathol* 149, 103–112.

Valgaeren, B. R., Pardon, B., Verherstraeten, S., Goossens, E., Timbermont, L., Haesebrouck, F., Ducatelle, R., Deprez, P. R. & Van Immerseel, F. (2013b). Intestinal clostridial counts have no diagnostic value in the diagnosis of enterotoxaemia in veal calves. *Vet Rec* 172, 237.

Van Kruiningen, H. J., Nyaoke, C. A., Sidor, I. F., Fabis, J. J., Hinckley, L. S. & Lindell, K. A. (2009). Clostridial abomasal disease in Connecticut dairy calves. *Can Vet J* 50, 857–860.

Venczel, L. V., Arrowood, M., Hurd, M. & Sobsey, M. D. (1997). Inactivation of *Cryptosporidium parvum* oocysts and *Clostridium perfringens* spores by a mixed-oxidant disinfectant and by free chlorine. *Appl Environ Microbiol* 63, 1598–1601.

Verherstraeten, S., Goossens, E., Valgaeren, B., Pardon, B., Timbermont, L., Vermeulen, K., Schauvliege, S., Haesebrouck, F., Ducatelle, R. & other authors (2013). The synergistic necrohemorrhagic action of *Clostridium perfringens* perfringolysin and alpha toxin in the bovine intestine and against bovine endothelial cells. *Vet Res* 44, 45.