

CASE REPORT

A case of Chronic Recurrent Multifocal Osteomyelitis associated with Crohn's disease

Christi van Ommen^{1,2}, Joke Dehoorne³, Frans De Baets³, Saskia Vande Velde³, Myriam Van Winckel², Stephanie Van Biervliet⁴

(1) Groene Hart Ziekenhuis Pediatrice, Gouda Netherlands ; (2) University Hospital of Ghent Pediatrics, Ghent, Belgium ; (3) Pediatric Gastro-enterology, University Hospital ; (4) Paediatric gastroenterology and nutrition, Ghent University Hospital, Ghent, Belgium.

Abstract

Chronic recurrent multifocal osteomyelitis (CRMO) is an auto-inflammatory bone disease of unknown etiology, most commonly affecting the metaphysis of long bones, especially the tibia, femur and clavicle. The clinical spectrum varies from self-limited uni- or multi-focal lesions to chronic recurrent courses. Diagnosis is based on clinical, radiologic and pathological findings, is probably underdiagnosed due to poor recognition of the disease. A dysregulated innate immunity causes immune cell infiltration of the bones with subsequent osteoclast activation leading to sterile bone lesions. The molecular pathophysiology is still incompletely understood but association with other auto-inflammatory diseases such as inflammatory bowel disease (IBD), psoriasis, Wegener's disease, arthritis and synovitis, acne, pustulosis, hyperostosis and osteitis (SAPHO) syndrome is interesting. CRMO can precede the symptoms of the associated disease by several years. The bone remodeling caused by CRMO can cause permanent disability. We report the case of a 10-year-old boy with CRMO in association with Crohn's disease. (Acta gastroenterol. belg., 2015, 78, 000-000).

Key words : chronic recurrent multifocal osteomyelitis, inflammatory bowel disease, Crohn's disease, non-bacterial osteomyelitis.

Abbreviations : CRMO, Chronic recurrent multifocal osteomyelitis ; CRP, C-reactive protein ; ESR, Erythrocyte sedimentation rate ; IBD, inflammatory bowel disease ; MRI, magnetic resonance imaging ; NSAID, nonsteroidal anti-inflammatory drug

Introduction

Giedion described chronic recurrent multifocal osteomyelitis (CRMO) as "an unusual form of multifocal bone lesions with subacute and chronic symmetrical osteomyelitis" in 1972 (1). Kahn reported the association of CRMO with inflammatory bowel disease (2). This non-infectious autoinflammatory disease of the skeleton affects predominantly children and adolescents but often remains a diagnosis by exclusion.

Patients are affected by recurrent episodes of osteomyelitis. Laboratory results demonstrate elevated erythrocyte sedimentation rate (ESR) and C-reactive protein (CRP), with sterile blood cultures. Lesions can be visualized using radiography or bone scintigraphy (3) but whole body magnetic resonance imaging (MRI) increases the number of lesions detected (4). Empiric antibiotic therapy does not improve the clinical picture. Although the majority of children with CRMO improve with non-steroidal analgesics or short courses of steroids, a

protracted course lasting several years, which can lead to permanent deformations, is typical. CRMO can precede the symptoms of other auto-inflammatory diseases such as inflammatory bowel disease, therefore physicians following these patients should be attentive for new symptoms during the disease evolution in order to detect other associated auto-inflammatory diseases.

Case report

A 10 year-old boy, presented with a painful left foot and low-grade fever of 1 month duration, without a history of trauma, tick bite or foreign travel. There was no calor, rubor or tumor and radiography as well as ultrasound were normal. Pain persisted despite immobilization. Magnetic Resonance Imaging (MRI) of the ankle showed bone edema of the left malleolus lateralis suggestive of osteomyelitis. Blood test showed a normal blood count, a CRP of 13.8 mg/L (normal, 0-10 mg/L), and an ESR of 74 mm/hour (normal, 0-13 mm/h). The boy was hospitalized for intravenous antibiotic treatment (flucloxacillin) and intermittent nonsteroidal anti-inflammatory drugs (NSAID). Blood cultures remained negative. Meanwhile, the clinical picture expanded with right hip and knee pain, anorexia, weight loss, and intermittent vomiting and bloody diarrhea. Repeat MRI showed persisting edema of the left lateral maleolus, the distal epiphysis of the right knee and the metadiaphysis of the right femur. Bone biopsy showed no evidence of malignancy or suppurative infection. Additional bone marrow aspirate was normal. Antibiotic switch to ceftriaxone was unsuccessful and the boy was transferred to our clinic. He had lost 20% of his original weight, his body mass index (BMI) was -3.8 SD and he displayed complete oral food intolerance with persisting vomiting and diarrhea. The bone pain was less profound at that time but fever persisted. Stool samples revealed toxine positive *Clostridium difficile*, which was treated with

Correspondence to: Christi van Ommen, University Hospital of Ghent Pediatrics, De Pintelaan 185, 9000 Ghent, Belgium.
E-mail : christivanommen@hotmail.com

Submission date : 19/11/2014
Acceptance date : 05/02/2015

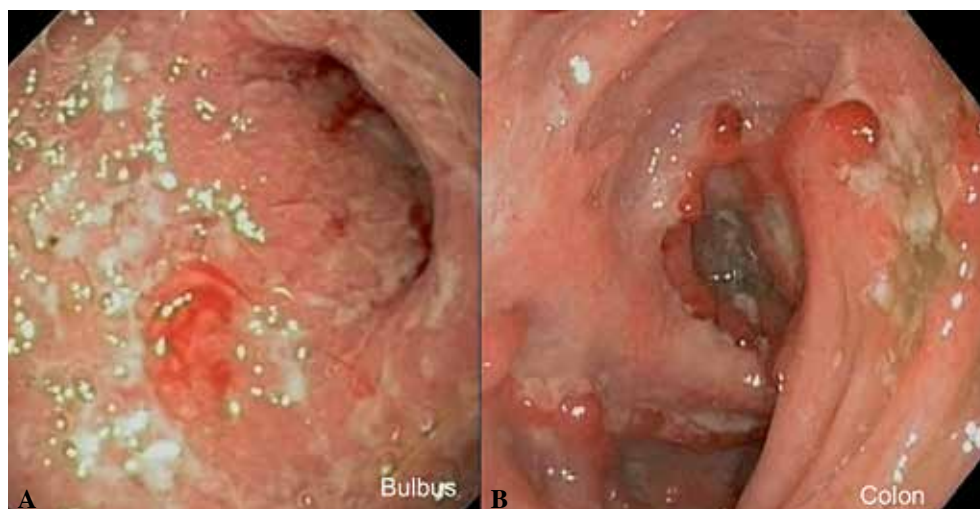


Fig. 1. — Endoscopic view of the bulbus and colon of the patient revealing erosions and ulcerations.

metronidazole without effect on the overall clinical picture.

The aseptic bone lesions unresponsive to antibiotic treatment associated with symptoms suggestive of IBD led to endoscopic examination. Upper endoscopy revealed important bulbar erosions (Fig. 1A) with a narrow pylorus and colonoscopy was limited due to the severity of the ulcerations to a left colonoscopy (Fig. 1B). Histology confirmed chronic active granulomatous inflammation of the bulbus and colon, suggestive for Crohn's disease. Due to the severity of the picture the patient was started on a combined therapy of exclusive enteral feeding (Modulen®) and prednisolone (2 mg/kg/d). Resolution of gastrointestinal symptoms, fever as well as the bone pain was seen within days. Azathioprin (2 mg/kg/d) was associated while tapering the steroid therapy. However, bone symptoms as well as diarrhea reappeared while still receiving 1,6 mg/kg/d prednisolone. Stools were negative for *Clostridium difficile*. Infliximab (5 mg/kg) was started with a classical induction scheme (0, 2, 6 weeks) followed by maintenance therapy every 8 weeks. The association of Infliximab allowed to taper and stop the steroids and the boy continued this treatment regimen (Infliximab and azathioprine) without experiencing any relapses for one year.

Discussion

The diagnosis of CRMO starts with a high level of clinical awareness based upon night bone pain eventually associated with low-grade fever and sometimes swelling and warmth over the affected area. The multiple bone lesions diagnosed clinically and/or using imaging have a prolonged and fluctuating course of recurrent episodes in atypical infectious osteomyelitis sites. Most are localized in the metaphysis of the long bones, the clavicle, spine and mandibula. The absence of microorganisms as well as the unresponsiveness to antibiotic treatment should

raise the suspicion. Infectious osteomyelitis and malignancy are the most important components of the differential diagnosis. Laboratory and histopathological findings are nonspecific although mildly elevated acute phase markers are usually present.

Although plain radiography can reveal osteolytic lesions with surrounding sclerosis, whole body MRI can reveal more lesions (4). The study of Falip *et al.* describes false negative plain radiographs in 39% of cases. Bone scintigraphy is able to show the multifocal localization but has difficulties discerning physiological metaphyseal uptake from disease lesions. Whole body MRI therefore is not only able to reveal more extensive inflammation, but also subclinical lesions as well as metaphyseal lesions. This results in a disclosure of a multifocal involvement in 80% of cases (4). Falin *et al.* propose a diagnostic strategy where whole body MRI with short tau inversion recovery (STIR) is used, early in the diagnostic workout.

CRMO is probably not a single disease but a sign compatible with different diagnoses. The pathology is not completely understood but since symptoms appear by seemingly unprovoked inflammation without auto-reactive T cells or auto-antibodies, it is classified as an autoinflammatory disorder. A disturbed regulation of the innate immunity by cytokine imbalances will cause immune cell infiltration, activation of the osteoclasts and osteolysis and bone remodeling as a result (5). Inherited forms as in Majeed Syndrome (6) or interleukin-1 receptor antagonist deficiency (7) are monogenic. There is, however, also a sporadic type, which is associated with several inflammatory disorders such as inflammatory bowel disease and psoriasis. Although no definite disease causing mutations have been identified in this context, the increased incidence of CRMO and other inflammatory disease in first-degree relatives of patients with CRMO pleads for a significant genetic contribution (8,9). For the clinician it is important to remember that CRMO

Table 1. — Overview of all reported cases of chronic recurrent multifocal osteomyelitis (CRMO) associated with inflammatory bowel disease (IBD)

Reference	N	Sex	IBD	Age (yr)	Presenting picture	Time to diagnosis (m) (time with combined complaints)	Time (m) between 2 clinical pictures	Treatment CRMO	Treatment IBD
von Kalle (21)	1		CD						
Kim (20)	1	M	UC	41	IBD	1	8	NSAID, Steroids, Pamidronate, MTX	ASA, Colectomy
Morbach (19)	1	M	CD	12	CRMO & IBD	1 (1)			
	1	F	UC	15	CRMO & IBD	6 (1)			
	1	M	CD	15	CRMO	36	36		
	1	F	CD	10	CRMO	3	5		
Jansson (17)	5		2 CD 3 UC						
Girschick (18)	1	F	CD	9	CRMO	4	15	NSAID, ASA, steroids, corset	Steroids, ASA, Azathioprine
E. Carpenter (f)	1	F	CD	9	CRMO	5	19	NSAID	Steroids, Metronidazole, 6-MP, Azathioprine, Infliximab
Schilling (15)	1	F	CD	53	CRMO	1	48	NSAID	ASA
	1	M	CD	33	CRMO			NSAID	ASA
	1	F	UC	38	CRMO		180	NSAID	ASA
	1	F	CD	20	CRMO		48	NSAID	ASA, Steroids
	1	F	CD	9	CRMO		48	NSAID, steroids, calcitonin	ASA, Steroids, MTX, Azithromycin
Huber (14)	3								
Bazrafshan (13)	1	F	CU	12	CRMO	24		NSAID	ASA, Steroids, Colectomy
Bousvaros (10)	1	F	CD	10	CRMO		60	Steroids	Sulfasalazine
	1	M	CD	8	CRMO	36	60		Steroids, ASA
	1	F	CD	8	CRMO	36	3	NSAID	Steroids, ASA
	1	F	CD	13	CRMO		6		Steroids, Azathioprine
	1	M	CD	10	CRMO		36	NSAID	Steroids, ASA
	1	F	CD	10	CRMO		18		Steroids, ASA, MTX
Bognar (11)	1	M	CD	43	CRMO & IBD	0,1 (0,1)		NSAID	Steroids, ASA
Omidi (12)	1	F	UC	12	CRMO	36	5	Steroids	
TOTAL	30	14F/7M	8 UC/ 19 MC	12 (8-53)	IBD first 1 CRMO first 17 Comined 3	5 (0,1-36)	19 (3-180)		

Reference gives first author and reference list number, number of cases reported, gender: F female, M male, Type of IBD diagnosed: CD Crohn's disease, UC ulcerative colitis, Age at diagnosis in years (yr), presenting clinical picture, duration of symptoms before diagnosis in months (m), time gap between the 2 diagnoses in months, treatment for CRMO and IBD: ASA aminosalicilates, MTX methotrexate, 6-MP 6-mercaptopurine, Steroids corticosteroids, NSAID non-steroidal anti-inflammatory drugs.

symptoms often precede the symptoms of inflammatory bowel disease (IBD), as was the case in our patient (10). Table 1 gives an overview of all reported patients with both CRMO and IBD (10-21). CRMO is not an innocent problem as potentially permanent deformities can occur as result of bone remodeling of vertebral fractures (22).

There are no placebo-controlled studies available for the treatment of CRMO. Different NSAIDs have been

reported to improve symptoms in the majority of patients (23). It is postulated that blocking of the cyclooxygenase pathway will inhibit the prostaglandin synthesis and therefore decrease the bone lesions (23). In case of treatment failure with NSAID, steroids have been tried, however, relapses can be expected when steroids are tapered (24). Biphosphonates were used with success in some cases where NSAIDs caused insufficient pain

control, although the mechanism of action remains unknown (25). Infliximab, a chimeric monoclonal antibody against tumour necrosis factor alpha, has been reported successful in a minority of very resistant patients (26). However, probably patients with associated Crohn's disease will respond better, as is the case in our patient with a complete disease control of more than 1 year (16). Controlling the Crohn's disease will improve the bone symptoms in most of these patients, as was the case in our patient (10).

Conclusion

CRMO is a clinical entity, which needs a high degree of suspicion for its diagnosis. It can be a first sign of other underlying diseases, demanding persistent awareness of the physician. Treatment is mandatory as it can cause permanent bone alterations, but most patients will respond to NSAIDs.

References

- GIEDION A., HOLTHUSEN W., MASEL L.F., VISCHER D. Subacute and chronic symmetrical osteomyelitis. *Ann. Radiol.*, 1972, **15** : 329-342.
- KAHN M.F. Chronic recurrent multifocal osteomyelitis : association with vertebralplana. *J. Bone Joint Surg. Am.*, 1990, **72** : 305-306.
- KHANNA G., SATO T.S., FERGUSON P. Imaging of chronic recurrent multifocal osteomyelitis. *Radiographics*, 2009, **29** : 1159-1177.
- FALIP C., ALISON M., BOUTRY N., JOB-DESLANDRE C., COTTON A., AZOULAY R., ADAMSBAUM C. Chronic recurrent multifocal osteomyelitis (CRMO) : a longitudinal case series review. *Pediatr. Radiol.*, 2013, **43** : 355-375.
- HEDRICH C.M., HOFMANN S.R., PABLIK J., MORBACH H., GIRSCHICK H.J. Autoinflammatory bone disorders with special focus on chronic recurrent multifocal osteomyelitis (CRMO). *Ped. Rheumatol. Online J.*, 2013, **11** : 47 (doi : 10.1186/1546-0096-11-47).
- MAJEED H.A., KALAABI M., MOHANTY D., TEEBI A.S., TUNJEKAR M.F., AL-GHARBAWY F., MAJEED S.A., AL-GAZZAR A.H. Congenital dyserythropoietic anemia and chronic multifocal osteomyelitis in three related children and the association with Sweet syndrome in two siblings. *J. Pediatr.*, 1989, **115** : 730-734.
- REDDY S., JIA S., GEOFFREY R., LORIER R., SUCHIM., BROECKEL U., HESSNER M.J., VERBSKY J. An autoinflammatory disease due to homozygous deletion of the IL 1 RN locus. *N. Engl. J. Med.*, 2009, **360** : 2438-2444.
- FERGUSON P.J. Current understanding of the pathogenesis and management of chronic recurrent multifocal osteomyelitis. *Curr. Rheumatol. Rep.*, 2012, **14** : 130-41.
- RODERICK M.R., RAMANAN A.V. Chronic recurrent multifocal osteomyelitis. *Adv. Exp. Med. Biol.*, 2013, **764** : 99-107.
- BOUSVAROS A., MARCON M., TREEM W., WATERS P., ISSENMAN R., COUPER R. *et al.* Chronic recurrent multifocal osteomyelitis associated with chronic inflammatory bowel disease in children. *Dig. Dis. Sci.*, 1999, **44** : 2500-2507.
- BOGNAR M., BLAKE W., AGUDELO C. Chronic recurrent multifocal osteomyelitis associated with Crohn's disease. *Am. J. Med. Sci.*, 1998, **315** : 133-135.
- OMIDI C.J., SIEGFRIED E.C. Chronic recurrent multifocal osteomyelitis preceding pyoderma gangrenosum and occult ulcerative colitis in a pediatric patient. *Pediatr. Dermatol.*, 1998, **15** : 435-438.
- BAZRAFSHAN A., ZANJANI K.S. Chronic recurrent multifocal osteomyelitis associated with ulcerative colitis : a case report. *J. Pediatr. Surg.*, 2000, **35** : 1520-1522.
- HUBER A.M., LAM P.Y., DUFFY C.M., YEUNG R.S., DITCHFIELD M., LAXER D., COLE W.G., KERR GRAHAM H., ALLEN R.C., LAXER R.M. Chronic recurrent multifocal osteomyelitis : clinical outcomes after more than five years of follow-up. *J. Pediatr.*, 2002, **141** : 198-203.
- SCHILLING F., MÄRKER-HERMANN E. Chronic recurrent multifocal osteomyelitis in association with chronic inflammatory bowel disease : enteropathic CRMO. *Z. Rheumatol.*, 2003, **62** : 527-538.
- CARPENTER E., JACKSON M.A., FRIESEN C.A., SCARBROUGH M., ROBERTS C.C. Crohn's - associated chronic recurrent multifocal osteomyelitis responsive to infliximab. *J. Pediatr.*, 2004, **144** : 541-544.
- JANSSON A., RENNER E.D., RAMSER J., MAYER A., HABAN M., MEINDL A., GROTE V., DIEBOLD J., JANSSON V., SCHNEIDER K., BELOHRADSKY B.H. Classification of non-bacterial osteitis : retrospective study of clinical, immunological and genetic aspects in 89 patients. *Rheumatology*, 2007, **46** : 154-160.
- GIRSCHICK H.J., ZIMMER C., KLAUS G., DARGE K., DICK A., MORBACH H. Chronic recurrent multifocal osteomyelitis : what is it and how should it be treated ? *Nat. Clin. Pract. Rheumatol.*, 2007, **3** : 733-738.
- MORBACH H., DICK A., BECK C., STENZEL M., MÜLLER-HERMELINK H.K., RAAB P., GIRSCHICK H.J. Association of chronic non-bacterial osteomyelitis with Crohn's disease but not with CARD15 gene variants. *Rheumatol. Int.*, 2010, **30** : 617-621.
- KIM Y.S., LEE J., KIM H.S. Sternocostal involvement in chronic recurrent multifocal osteomyelitis associated with ulcerative colitis. *Rheumatol. Int.*, 2013, **33** : 2889-2892.
- VON KALLE T., HEIM N., HOSPACH T., LANGENDÖRFER M., WINKLER P., STUBER T. Typical patterns of bone involvement in whole-body MRI of patients with chronic recurrent multifocal osteomyelitis (CRMO). *Rofo.*, 2013, **185** : 655-661.
- DUFFY C.M., LAM P.Y., DITCHFIELD M., ALLEN R., GRAHAM H.K. Chronic multifocal osteomyelitis : review of orthopaedic complications at maturity. *J. Pediatr. Orthop.*, 2002, **22** : 501-505.
- SCHULTZ C., HOLTERHUS P.M., SEIDEL A., JONAS S., BARTHEL M., KRUSE K. *et al.* Chronic recurrent multifocal osteomyelitis in children. *Pediatr. Infect. Dis. J.*, 1999, **18** : 1008-1013.
- GIRSCHICK H.J., KRAUSPE R., TSCHAMMLER A., HUPPERTZ H.I. Chronic recurrent osteomyelitis with clavicular involvement in children : diagnostic value of different imaging techniques and therapy with non-steroidal antiinflammatory drugs. *Eur. J. Pediatr.*, 1998, **157** : 28-33.
- ISHIKAWA-NAKAYAMA K., SUGIYAMA E., SAWAZAKI S., TAKI H., KOBAYASHI M., KOIZUMI F., FURUTA I. Chronic recurrent multifocal osteomyelitis showing marked improvement with corticosteroid treatment. *J. Rheumatol.*, 2000, **27** : 1318-1319.
- GLEESON H., WITSHIRE E., BRIODY J., HALL J., CHAITOW J., SILENCE D., COWELL C., MUNNS C. Childhood chronic recurrent multifocal osteomyelitis : pamidronate therapy decreases pain and improves vertebral shape. *J. Rheumatol.*, 2008, **35** : 707-712.