

Treatment of necrotizing fasciitis using negative pressure wound therapy in a puppy

Behandeling van necrotiserende fasciitis met negatieve druktherapie bij een puppy

¹E. Abma, ¹A. M. Kitshoff, ¹S. Vandenabeele, ¹T. Bosmans, ²E. Stock, ¹H. de Rooster

¹Department of Medicine and Clinical Biology of Small Animals, Faculty of Veterinary Medicine, University of Ghent, Salisburylaan 133, B-9820 Merelbeke, Belgium

²Department of Medical Imaging and Orthopedics of Small Animals, Faculty of Veterinary Medicine, University of Ghent, Salisburylaan 133, B-9820 Merelbeke, Belgium

eline.abma@ugent.be

ABSTRACT

A two-month-old German shepherd dog was presented with anorexia, lethargy and left hind limb lameness associated with swelling of the thigh. Clinical findings combined with cytology led to the presumptive diagnosis of necrotizing fasciitis (NF). Extensive debridement was performed and silver-foam-based negative pressure wound therapy (NPWT) was applied. During the first 48 hours, a negative pressure of -75 mmHg was used. Evaluation of the wound demonstrated no progression of necrosis and a moderate amount of granulation tissue formation. A new dressing was placed and a second 48-hour cycle of NPWT was initiated at -125 mmHg. At removal, a healthy wound bed was observed and surgical closure was performed.

The prompt implementation of NPWT following surgical debridement led to accelerated wound healing without progression of necrosis in this case of canine NF. Negative pressure wound therapy could become an integral part of the management strategy of canine NF, improving the prognosis of this life-threatening disease.

SAMENVATTING

Een Duitse herder van twee maanden oud werd aangeboden met anorexie, lethargie, kreupelheid en een pijnlijke zwelling aan de linkerachterpoot. De bevindingen op het lichamelijk en cytologisch onderzoek leidden tot een vermoedelijke diagnose van necrotiserende fasciitis (NF). Alle aangetaste weefsels werden chirurgisch verwijderd en negatieve druktherapie met een zilverschuumverband werd opgestart. Gedurende de eerste 48 uur werd een negatieve druk van -75 mmHg ingesteld. Bij de evaluatie van de wonde werd een matige hoeveelheid granulatieweefsel vastgesteld en er was geen verdere uitbreiding van de necrose aanwezig. Het verband werd vernieuwd en een tweede negatieve drukcyclus van 48 uur werd ingesteld, ditmaal op -125 mmHg. Na het verwijderen van het verband zag het wondbed er gezond uit en werd een chirurgische sluiting van de wonde uitgevoerd.

In dit geval leidde onmiddellijke implementatie van negatieve druktherapie na chirurgische debridement tot een versnelde wondheling en verhinderde het verdere uitbreiding van de necrose. Negatieve druktherapie kan een integraal onderdeel worden van de behandelingsstrategie van caniene NF en kan de prognose van deze levensbedreigende aandoening verbeteren.

INTRODUCTION

Necrotizing fasciitis (NF) is an uncommon but life-threatening disease in dogs that manifests as a rapidly progressive bacterial infection of the fascia, blood vessels, nerves, and subcutaneous tissues (Jenkins et al., 2001; Naidoo et al., 2005; Kulendra and Corr, 2008; Csiszer et al., 2010). The clinical manifestation of the disease in dogs is strikingly similar

to NF in humans but in human patients *Streptococcus pyogenes* is mostly isolated (Burge and Watson, 1994; Wong et al., 2003). The most commonly isolated bacterium in dogs is *Streptococcus canis*, a β -hemolytic, Lancefield group G streptococcus classified as a commensal and opportunistic pathogen of the skin and mucous membranes (Miller et al., 1996; DeWinter et al., 1999; Jenkins et al., 2001; Naidoo et al., 2005; Kulendra and Corr, 2008). Dogs become infected by

subcutaneous inoculation of bacteria through penetrating wounds or minor trauma, although in some patients no inciting cause can be identified (Prescott et al., 1997; Jenkins et al., 2001). Exotoxins produced by *S. canis* may result in systemic states, such as systemic inflammatory response syndrome, disseminated intravascular coagulation, or streptococcal toxic shock syndrome (Miller et al., 1996; DeWinter et al., 1999; Brady and Otto, 2001). Mortality rates for NF in dogs are poorly documented but seem to be slightly lower than in humans, about 8% (Abma et al., 2013).

A presumptive diagnosis of NF is based on the clinical findings, surgical appearance, and a positive bacteriological culture result. Confirmation by histopathology is mandatory (Naidoo et al., 2005). In humans, early diagnosis and correct treatment within 24 hours after diagnosis can halve the mortality rate compared to delayed treatment (Freischlag et al., 1985). Management of NF in both humans and dogs requires early aggressive surgical debridement of all necrotic tissue, appropriate wound management as well as initiation of broad-spectrum antimicrobial therapy (Naidoo et al., 2005; Edlich et al., 2010).

This case report describes the successful wound management in a dog with NF, using a combination of surgical debridement and prompt negative pressure wound therapy (NPWT).

CASE REPORT

A two-month-old intact female German shepherd dog, weighing 8.9 kg, was presented with anorexia, lethargy and left hind limb lameness associated with swelling of the thigh that was non-responsive to treatment with meloxicam (Metacam®, Boehringer, Brussels, Belgium) and marbofloxacin (Marbocyl®, Vétotoquinol, Magny Vernois, France) of 2 days duration.

On presentation (day 0), a general physical examination revealed a recumbent, lethargic dog with a painful, ill-defined, diffuse soft-tissue swelling of the left hind limb extending from the greater trochanter to the stifle joint (Figure 1). Mild pitting edema was

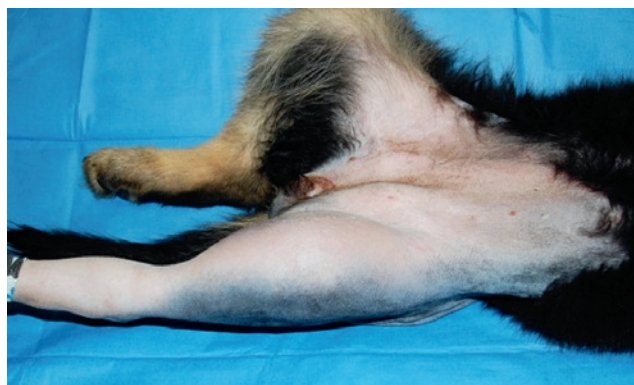

Figure 1. Photograph of the affected left hind limb of a German shepherd puppy at presentation. Painful, ill-defined and diffuse soft tissue swelling, extending from the greater trochanter to the stifle joint.

present on the proximal hind limb, extending from the greater trochanter to the stifle. The patient was pyrexia (40.6 °C), tachycardic (226 beats per minute) and tachypneic (64 breaths per minute). Orthopedic and neurologic examinations of the affected hind limb were normal. Complete blood count and electrolytes revealed a mild, non-regenerative, microcytic anemia (Hct 24%, reference range 37.3-61.7%), mild thrombocytopenia ($128 \times 10^3/\mu\text{L}$, reference range 148-848 $\times 10^3/\mu\text{L}$), mild monocytosis ($2.31 \times 10^9/\text{L}$, reference range $0.16\text{-}1.12 \times 10^9/\text{L}$), mild neutrophilia ($12.05 \times 10^9/\text{L}$, reference range $2.95\text{-}11.64 \times 10^9/\text{L}$) and mild hyponatremia (139 mmol/L, reference range 145-157 mmol/L). Serum biochemistry and coagulation times (prothrombin time and activated partial thromboplastin time) were within normal limits.

Orthogonal radiographs of the left hind limb showed a diffuse, poorly circumscribed soft-tissue opacification in the region of the lateral and caudolateral femoral diaphysis, extending from the greater trochanter to the stifle. An ultrasonographic (iU22 xMATRIX, Philips, Amsterdam, the Netherlands) examination was subsequently performed on the affected hind limb, using a linear array multifrequency probe (L12-3 Broadband linear array, Philips, Amsterdam, the Netherlands) operated at a frequency of 12-13 MHz. There was a $5 \times 4 \times 12$ cm well-delineated cavity at the lateral and caudolateral aspect of the femur, containing anechoic fluid with multiple small (< 1 mm) hyperechoic specks (Figure 2). The cavity extended to the physis of the greater trochanter 1 cm proximally and distally to 3 cm proximal to the distal femoral physis. The popliteal lymph node was enlarged, rounded and hypoechoic, consistent with an inflammatory lymphadenopathy. The perimuscular

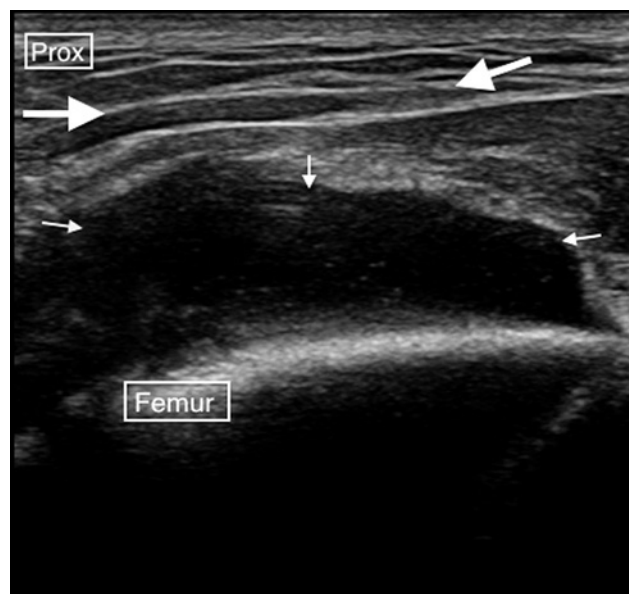

Figure 2. Transverse ultrasonographic view of the affected hind limb. Note the fluid-filled cavity containing anechoic fluid with multiple hyperechoic specks (small white arrows), and the inflammation and edema of the perimuscular tissues (big white arrows).

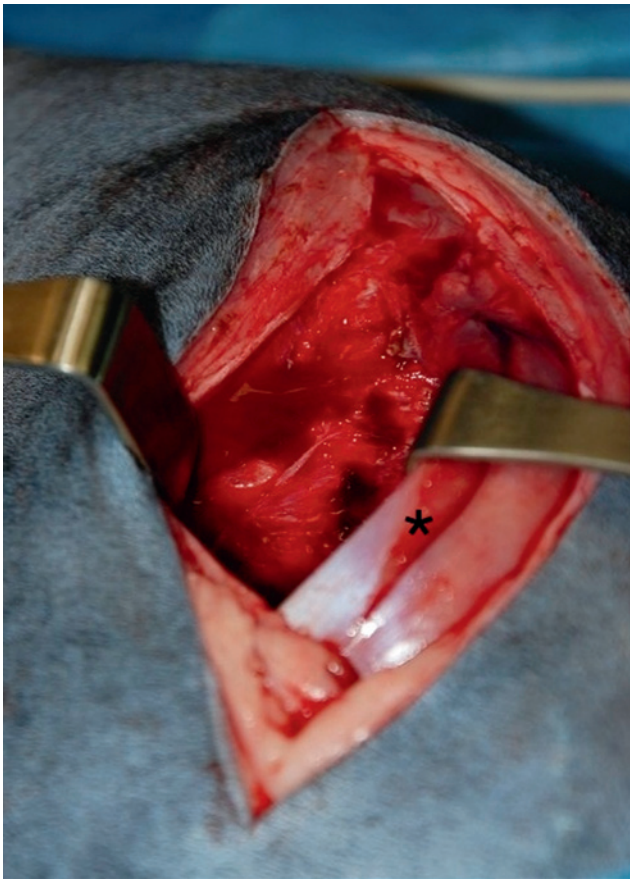


Figure 3. Photograph of the affected hind limb during surgery on day 1. An incision was made into the superficial leaf of the fascia lata. Retraction of the biceps femoris muscle revealed a fluid-filled pocket extending along the lateral and caudolateral aspect of the femur. A 5 cm fasciotomy was made in the biceps femoris muscle (asterisk).

tissues caudolateral of the femur had a diffuse hyperechoic appearance interlaced with hypoechoic strands indicative for inflammation and edema. The fluid in the cavity was aspirated under ultrasonographic guidance, and fine-needle aspirates were taken of the perimascular tissue. Cytology and bacterial culture and sensitivity testing were performed. The cytological findings from both locations were consistent with a suppurative inflammatory process consisting of degenerative neutrophils with chains of cocci both intra- and extracellularly.

A presumptive diagnosis of NF was made. The patient was hospitalized and received isotonic crystalloid (Hartmann®, B-Braun, Brussels, Belgium) fluid therapy and colloids (Tetraspan®, B-Braun, Brussels, Belgium) at 10 mL/kg/hour and 1 mL/kg/hour respectively. Pain was managed with the administration of methadone (Comfortan®, Dechra, Heusden-Zolder, Belgium) (0.2 mg/kg IV q 4h), and amoxicilline-clavulanate (Augmentin®, GSK, London, United Kingdom) (20 mg/kg IV q 8h) as well as clindamycin (Antirobe®, Pfizer, Zaventem, Belgium) (13 mg/kg PO q 12h) were administered, while awaiting the bacterial culture results.

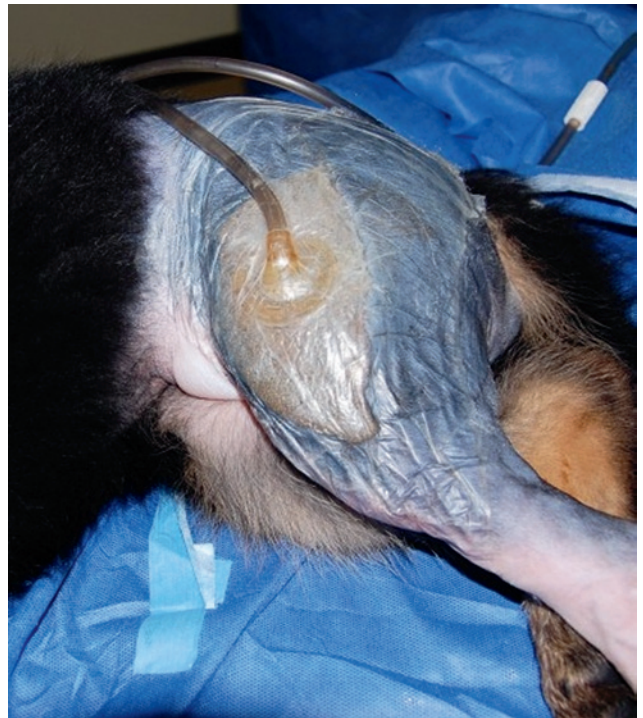

Figure 4. Photograph after application of a NPWT device. A silver-impregnated polyurethane foam dressing was placed inside the wound (including the associated cavity) and covered with a polyurethane adhesive drape. An interface pad and extension tubing were then applied onto the drape over a 2 cm-diameter opening created in the drape, and connected to the negative pressure source.

Surgical exploration of the swelling was done within 24 hours, when the patient was stable for anesthesia (day 1). The patient was premedicated with methadone (0.2 mg/kg IV) and subsequently induced 15 minutes later using propofol (Propovet®, Abbot, Berkshire, United Kingdom) administered to effect (total dose of 6 mg/kg IV). After endotracheal intubation, anesthesia was maintained with isoflurane (Isoflor®, Abbot, Berkshire, United Kingdom) vaporized in 100% oxygen using a rebreathing system. The patient was positioned in right lateral recumbency, clipped and aseptically prepared for surgery. A standard lateral approach to the femoral diaphysis was performed with the skin incision made craniolateral to the femoral diaphysis, extending from the level of the greater trochanter to 2 cm proximal to the stifle joint. After incision into the superficial leaf of the fascia lata and caudal retraction of the biceps femoris muscle, a large fluid filled cavity extending along the lateral and caudolateral aspect of the femur, and the lateral aspect of the adductor magnus muscle, became evident (Figure 3). The sciatic nerve was exposed caudolaterally in the surgical wound. About 80 mL of red brown fluid was drained from the cavity by suction. The fascia overlying the vastus lateralis and adductor magnus et brevis muscles was slightly yellow in color with a frayed appearance, and it easily disrupted under digital palpation. The biceps femoris muscle belly was

macroscopically normal but moderately distended and, compared to the other muscles in the region, it was turgid on digital palpation. A 5-cm fasciotomy was performed on the lateral aspect. Muscle and fascial biopsies were collected for histopathological analysis. All macroscopically affected tissues were subsequently debrided surgically, and the wound was flushed extensively with sterile saline (NaCl 0.9%®, B-Braun, Brussels, Belgium).

A nanocrystalline silver-coated dressing (Acticoat®, Smith&Nephew, Hull, England) was placed between the exposed sciatic nerve and the wound cavity to prevent contact between the nerve and the foam dressing during NPWT. A silver-impregnated polyurethane foam (V.A.C. GranuFoam Silver®, KCI, Brussels, Belgium) cut to shape was placed inside the surgical wound and associated cavity, and covered with a polyurethane adhesive drape (V.A.C. Drape®, KCI, Brussels, Belgium). The polyurethane adhesive drape engaged at least 5 cm of skin around the wound. A 2-cm diameter opening was created in the drape at the centre of the wound. An interface pad and extension tubing (Sensa T.R.A.C. -pad connector, Brussels, Belgium) was applied onto the polyurethane adhesive drape over the opening. The extension tubing was then connected to the negative pressure source (V.A.C. ATS Therapy Unit®, KCI, Brussels, Belgium) and continuous negative pressure was initiated at -75 mmHg (Figure 4). Postoperative pain was managed with the administration of methadone (0.2 mg/kg IV q 4h). Fluid therapy consisted of a crystalloid maintenance solution and an isotonic solution (Sterofundin-B®, B-Braun, Brussels, Belgium) (2 mL/kg/h and 4 mL/kg/h respectively). Blood glucose levels were monitored every four hours, and antibiotic therapy was continued.

Forty-eight hours after submitting the samples, the bacteriological culture results indicated a pure culture of β -hemolytic *Streptococcus canis* of Lancefield group G, sensitive to the administered antibiotics. These laboratory results supported the diagnosis of NF.

After 48 hours of consecutive continuous negative pressure at -75 mmHg, a total amount of 200 mL fluid was present in the collection canister. The patient was anesthetized a second time, as described previously, to renew the dressing (day 3). The polyurethane foam and nanocrystalline silver-coated dressing were removed after cutting the polyurethane drape along the edges of the wound with a scalpel. The polyurethane drape that was attached to the skin was left in place. The defect had partly filled with granulation tissue with no visible signs of additional necrosis. Cytology of the wound bed was repeated. There were no signs of inflammation or bacteria. The wound was flushed with sterile saline. The distal half of the caudal border of the incision in the superficial leaf of the fascia lata was sutured to the lateral aspect of the vastus lateralis muscle to provide a protective layer over the sciatic nerve. A new silver-impregnated polyurethane foam

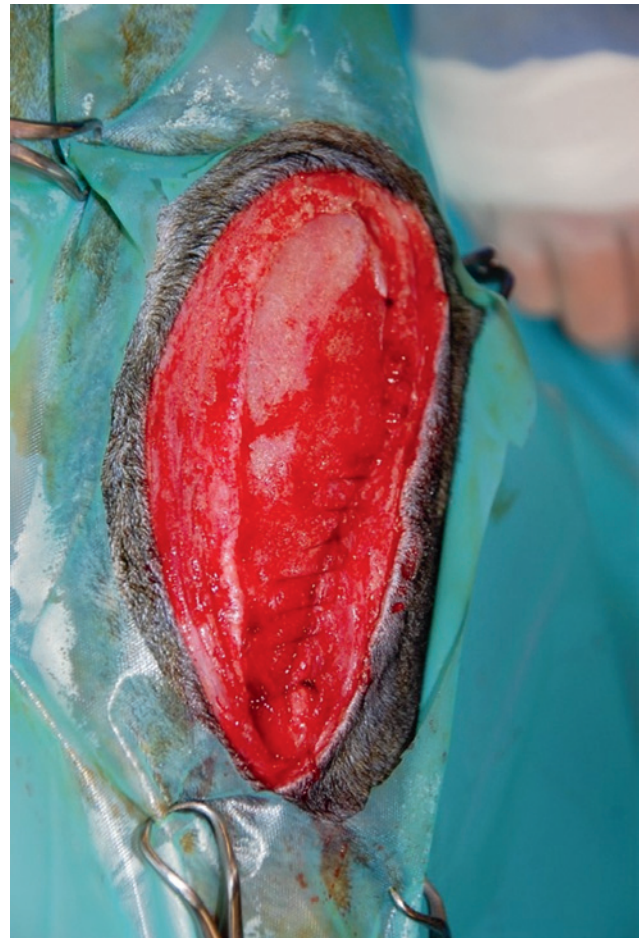


Figure 5. Photograph of the wound on day 5, after two 48-hour cycles of NPWT. The wound bed appeared healthy with extensive granulation tissue formation on all surfaces, allowing surgical wound closure.

and an adhesive polyurethane drape were applied as mentioned previously except that the drape was allowed to attach to the surface of the old one. A second 48-hour session of continuous negative pressure was started, this time at -125 mmHg. During this cycle, about 250 mL of fluid was drained. After discontinuation of the NPWT, the adhesive drape and wound dressing were removed as described previously after the administration of methadone (0.2 mg/kg IV) (day 5). The wound bed appeared healthy with extensive granulation tissue formation on all surfaces (Figure 5). Anesthesia was subsequently induced and maintained as described previously. The polyurethane adhesive drape was removed from the surface of the skin and the patient was routinely prepared for surgical closure of the wound. The skin edges were debrided, and the wound was sutured in three layers using poliglecaprone 25 (3/0 Monocryl®, Johnson&Johnson/Ethicon, Diegem, Belgium). First, the cranial edge of the incision of the superficial fascia lata was sutured to the caudal edge in the proximal half of the incision, and then the distal half was sutured in the same manner. Subsequently, the subcutaneous tissue was sutured in a simple continuous suture pattern and the skin was sutured intradermally. The bacteriological culture re-

sults of tissue biopsies obtained during this procedure were negative.

The histopathology results of the muscle and fascia biopsies collected at the time of the initial surgical debridement revealed a multifocal neutrophilic myositis and extensive necrosis, respectively.

The patient was discharged seven days after admission, with oral medication consisting of tramadol (Tramadol HCL®, Ecuphar, Oostkamp, Belgium) (2.5 mg/kg q 8-12h) for five days and an antibiotic treatment consisting of clindamcyne (11 mg/kg q 12h) for two weeks.

The dog was followed-up for 1.5 years. The owners reported that the lameness had disappeared gradually within two months post discharge, and that the dog had been doing very well ever since. Follow-up radiographs were declined, but orthopedic and neurologic examination of the affected hind limb demonstrated no abnormalities.

DISCUSSION

Necrotizing fasciitis is a life-threatening soft-tissue infection, associated with rapidly progressive inflammation and necrosis of subcutaneous fascial tissues; in dogs, generally caused by *Streptococcus canis* (Miller et al., 1996; Jenkins et al., 2001; Naidoo et al., 2005; Kulendra and Corr, 2008). In canine patients the extremities are more commonly affected than other areas of the body (Jenkins et al., 2001; Naidoo et al., 2005). Patients may present with fever, edema and intense pain that is disproportionate to the findings on physical examination (Miller et al., 1996; Jenkins et al., 2001; Gerdin and Pintar, 2003; Naidoo et al., 2005; Kulendra and Corr, 2008; Csiszer et al., 2010; Abma et al., 2013).

In addition to stabilization and the initiation of broad-spectrum antimicrobial therapy, early, aggressive, and repeated debridement is considered of the utmost importance for the survival of both human and veterinary patients affected by NF (Miller et al., 1996; Majeski and Majeski, 1997; Prescott et al., 1997; Andreassen et al., 2001; Naidoo et al., 2005; Wong and Wang, 2005; Edlich et al., 2010). Devitalized tissue may potentiate infection and toxin release, leading to vasoconstriction and secondary thrombosis of the supplying vessel with consequently progressive tissue necrosis and poor antibiotic penetrance (Childers et al., 2002; Naidoo et al., 2005). Reassessment, re-exploration and debridement of the affected area within 48 hours are warranted and should be continued until the infection is cleared (Wong and Wang, 2005; Edlich et al., 2010), as tissues that appear viable during the first surgical exploration may become devitalized (Andreassen et al., 2001).

In the veterinary literature, reports on the surgical treatment of NF in dogs are rare. In six cases, surgical management consisted of aggressive debridement, followed by conventional wound care with passive or

active drains (Jenkins et al., 2001; Gerdin and Pintar, 2003; Kulendra and Corr, 2008; Csiszer et al., 2010; Abma et al., 2013). In four of these cases, additional full-thickness skin necrosis appeared within 48 hours after the first surgical debridement (Jenkins et al., 2001; Gerdin and Pintar, 2003; Kulendra and Corr, 2008; Abma et al., 2013). The use of NPWT in the treatment of NF has been recently described in two dogs (Maguire et al., 2014). However, there is some concern about the diagnosis of NF in those canine cases. In the first case a successful treatment only initiated six days after admission is described, although prompt surgical debridement is of the utmost importance to improve prognosis after NF (Naidoo et al., 2005). In the second case, a differential diagnosis of cellulitis or an abscess at the level of the implant could not be ruled out based on the clinical history. In the present case report, a combination treatment of surgical debridement and NPWT is described in a dog diagnosed with NF based on histopathology and bacteriology results.

Negative pressure wound therapy is used in human NF patients with favorable outcomes, with most notably, the absence of additional wound necrosis, decrease in wound size, improvement of the wound quality and decreased length of hospitalization (De Geus and Van der Klooster, 2005; Phelps et al., 2006). Implementing NPWT in the treatment strategy of canine NF might be equally advantageous.

Although NPWT might reduce the need for repeated debridement in NF patients, it should be emphasized that the application of negative pressure is not a replacement for initial aggressive debridement (Argenta and Morykwas, 1997). During NPWT, a continuous or intermittent negative pressure is applied to the wound, using open-pore foam and an airtight, adhesive seal (Morykwas et al., 1997). Wound exudate is continuously removed, circulation is enhanced fourfold, and increased rates of granulation tissue formation and lowered bacterial counts are noted (Morykwas et al., 1997; Ben-Amotz et al., 2007). In the current case, samples for cytology and bacterial culture were obtained during every wound inspection and were negative at 48 and 96 hours after surgical debridement and initiation of the NPWT. It must be taken into account that a silver-impregnated foam was selected and the antimicrobial effects of the silver may have contributed to the infection control (Birke-Sorensen et al., 2011). A study in human patients with infected wounds reported negative bacterial cultures in 100% of the patients treated with silver-foam-based NPWT; all of which had positive bacterial cultures at the onset of therapy (Gerry et al., 2007). Although no such studies exist in dogs, the application of silver-impregnated foam in this patient seemed a sensible strategy.

The negative pressures often used in human and veterinary medicine range from -75 to -125 mmHg, with -125 mmHg being the optimal for new tissue formation and wound cleansing (Argenta and Mo-

rykwas, 1997; Ben-Amotz et al., 2007; Spillebeen et al., 2013). When major vessels or nerves are exposed, transposition of local tissues or muscle flaps over the vessel or nerve should be attempted (Argenta and Morykwas, 1997). If a layer of natural tissue is not available or surgically possible, a non-adherent dressing material may be considered as an alternative (Argenta and Morykwas, 1997). In the patient described, the ischiatic nerve was exposed in the wound. The transposition of natural tissue before commencing NPWT was not possible due to the concerns for ineffective drainage of the wound bed in combination with the presence of infection. Therefore, a nanocrystalline silver-coated dressing was placed over the nerve and an initial pressure setting of -75 mmHg was selected. After the first 48 hours of NPWT, it was possible to suture fascial tissue over the ischiatic nerve so that it was no longer exposed, and thus the pressure could be increased to -125 mmHg.

It has been reported in dogs with NF that the wound often becomes edematous and produces excessive wound exudate after debridement (Jenkins et al., 2001; Gerdin and Pintar, 2003; Abma et al., 2013). This excess fluid may serve as both physical and chemical deterrents to wound healing (Fay, 1987; Morykwas et al., 1997). The local microvasculature and lymphatic system are compressed by localized peripheral edema and exudate (Fay, 1987). The active removal of excess interstitial fluid by NPWT leads to decompression of the small blood vessels, restoring the flow and resulting in a higher supply of oxygen and vital nutrients needed for tissue regeneration (Morykwas et al., 1997). In the described case, 200 mL was produced during the first 48 hours and 250 mL during the next 48 hours, clearly indicating the system's effectiveness in fluid drainage from the wound. In most cases of veterinary NF so far, a passive (penrose) drain or an active closed suction (Jackson-Pratt) drain was placed in the wound (Jenkins et al., 2001; Gerdin and Pintar, 2003; Kulendra and Corr, 2008; Csiszer et al., 2010; Abma et al., 2013). In contrast to the use of passive drains, with NPWT, the amount of fluid produced can be measured accurately. There is no drain exit site that can cause skin maceration, and there is no potential risk for wound contamination via retrograde bacterial migration (Fay, 1987; Durai and Ng, 2010). Active drains are effective in fluid removal. However, they become ineffective if the vacuum is lost, which can go unnoticed; in contrast to an audible alarm when loss of negative pressure occurs during NPWT (Durai and Ng, 2010). In addition to its local effect on the wound, NPWT offers the surgeon the advantage of inspecting the wound at the time of dressing change and the possibility of performing additional surgical debridement if necessary.

In the patient described, the wound bed appeared healthy with extensive amounts of granulation tissue on all surfaces, the bacterial culture was negative, and it was possible to perform secondary wound closure as soon as 96 hours after NPWT initiation.

CONCLUSION

Immediate implementation of NPWT following surgical intervention proved to be successful in the management of NF. The absence of progressive necrosis and the swift uncomplicated wound healing observed in this case suggest that NPWT is a valuable modality in the treatment of canine NF. This case description might stimulate veterinary surgeons to consider the prompt use of NPWT if NF is suspected; potentially leading to decreased morbidity and improved prognosis for the affected dogs.

REFERENCES

- Abma E., Vandenabeele S., Campos M., Bosmans T., Stock E., de Rooster H. (2013). Necrotizing fasciitis in a dog. *Vlaams Diergeneeskundig Tijdschrift* 82, 134-142.
- Andreasen T. J., Green S. D., Childers B. J. (2001). Massive infectious soft-tissue injury: diagnosis and management of necrotizing fasciitis and purpura fulminans. *Plastic and Reconstructive Surgery* 107, 1025-1034.
- Argenta L. C., Morykwas M. J. (1997). Vacuum-assisted closure: a new method for wound control and treatment: clinical experience. *Annals of Plastic Surgery* 38, 563-577.
- Ben-Amotz R., Lanz O. I., Miller J. M., Filipowicz D. E., King M. D. (2007). The use of vacuum-assisted closure therapy for the treatment of distal extremity wounds in 15 dogs. *Veterinary Surgery* 36, 684-690.
- Birke-Sorensen H., Malmso M., Rome P., Hudson D., Krug E., Bruhin A., Caravaggi C., Chariker M., Depoorter M., Dowsett C., Dunn R., Duteille F., Ferreira F., Francos Martinez J. M., Grudzien G., Ichioka S., Ingemansson R., Jeffery S., Lee C., Vig S, Runkel N., Martin R., Smith J. (2011). Evidence-based recommendations for negative pressure wound therapy: treatment variables (pressure levels, wound filler and contact layer) – steps toward an international consensus. *Journal of Plastic, Reconstructive and Aesthetic Surgery* 64, 1-16.
- Brady C. A., Otto C. M. (2001). Systemic inflammatory response syndrome, sepsis and multiple organ dysfunction. *Veterinary Clinics of North America: Small Animal Practice* 31, 1147-1161.
- Burge T., Watson J. (1994). Necrotising fasciitis. *British Medical Journal* 308, 1453-1454.
- Childers B. J., Potyondy L. D., Nachreiner R. (2002). Necrotizing fasciitis: a fourteen year retrospective study of 163 consecutive patients. *American Journal of Surgery* 68, 109-116.
- Csiszer A. B., Towle H. A., Daly C. M. (2010). Successful treatment of necrotizing fasciitis in the hind limb of a great Dane. *Journal of the American Animal Hospital Association* 46, 433-438.
- De Geus H. R., Van der Klooster J. M. (2005). Vacuum-assisted closure in the treatment of large skin defects due to necrotizing fasciitis. *Intensive Care Medicine* 31, 601.
- DeWinter L. M., Low D. E., Prescott J. F. (1999). Virulence of *Streptococcus canis* from canine streptococcal toxic shock syndrome and necrotizing fasciitis. *Veterinary Microbiology* 70, 95-110.
- Durai R., Ng P. C. (2010). Surgical vacuum drains: types, uses and complication. *AORN Journal* 91, 266-271.

- Edlich R. F., Cross C. L., Dahlstrom J. J., Long W. B. (2010). Modern concepts of the diagnosis and treatment of necrotizing fasciitis. *Journal of Emergency Medicine* 39, 261-265.
- Fay M. F. (1987). Drainage systems: their role in wound healing. *AORN Journal* 46, 442-450.
- Freischlag J., Ajalat G., Busuttil R. W. (1985). Treatment of necrotizing soft tissue infections: the need for a new approach. *American Journal of Surgery* 149, 751-755.
- Gerdin J., Pintar J. (2003). Necrotizing fasciitis: a canine case study. *Senior Seminar Paper, Cornell College of Veterinary Medicine*, 1-13.
- Gerry R., Kwei S., Bayer L., Breuing K. H. (2007). Silver-impregnated vacuum-assisted closure in the treatment of recalcitrant venous stasis ulcers. *Annals of Plastic Surgery* 59, 58-62.
- Jenkins C. M., Winkler R., Rudloff E., Kirby R. (2001). Necrotizing fasciitis in a dog. *Journal of Veterinary Emergency and Critical Care* 11, 299-305.
- Kulendra E., Corr S. (2008). Necrotizing fasciitis with subperiosteal *Streptococcus canis* infection in two puppies. *Veterinary and Comparative Orthopaedics and Traumatology* 21, 474-477.
- Maguire P., Azagrar J., Carb A. (2014). The successful use of negative-pressure wound therapy in two cases of canine necrotizing fasciitis. *Journal of the American Animal Hospital Association*, DIO: 10.5326/JAAHA-MS-6033 [Epub ahead of print].
- Majeski J., Majeski E. (1997). Necrotizing fasciitis: improved survival with early recognition by tissue biopsy and aggressive surgical treatment. *Southern Medical Journal* 90, 1065-1068.
- Miller C. W., Prescott J. F., Mathews K. A., Betschel S. D., Yager J. A. Guru V., DeWinter L., Low D. E. (1996). Streptococcal toxic shock syndrome in dogs. *Journal of the American Veterinary Medicine Association* 8, 1421-1426.
- Morykwas M. J., Argenta L. C., Shelton-Brown E. I., McGuirt W. (1997). Vacuum-assisted closure: a new method for wound control and treatment: animal studies and basic foundation. *Annals of Plastic Surgery* 38, 553-562.
- Naidoo S. L., Miller L. M., Nicastro A. (2005). Necrotizing fasciitis: a review. *Journal of the American Animal Hospital Association* 41, 104-109.
- Phelps J. R., Fagan R., Pirela-Cruz M. A. (2006). A case study of negative pressure wound therapy to manage acute necrotizing fasciitis. *Ostomy Wound Management* 52, 54-59.
- Prescott J. F., Miller C. W., Mathews K. A., Yager J. A., De Winter, L. (1997). Update on canine streptococcal toxic shock syndrome and necrotizing fasciitis. *The Canadian Veterinary Journal* 38, 241-242.
- Spillebeen A. L., Or M., Van Goethem B., De Rooster H. (2013). Negatieve druktherapie ter bevordering van de wondheling bij gezelschapsdieren. *Vlaams Diergeneeskundig Tijdschrift* 82, 191-200.
- Wong C., Chang H., Pasupathy S. (2003). Necrotizing fasciitis: clinical presentation, microbiology, and determinants of mortality. *The Journal of Bone and Joint Surgery* 85, 1454-1460.
- Wong C., Wang Y. (2005). The diagnosis of necrotizing fasciitis. *Current Opinion in Infectious Diseases* 18, 101-106.