

Small bowel capsule endoscopy: Where are we after almost 15 years of use?

Cedric Van de Bruaene, Danny De Looze, Pieter Hindryckx

Cedric Van de Bruaene, Danny De Looze, Pieter Hindryckx, Department of Gastro-enterology, University Hospital Ghent, 9000 Ghent, Belgium

Author contributions: Van de Bruaene C, De Looze D and Hindryckx P analyzed data; Van de Bruaene C and Hindryckx P wrote the paper; Van de Bruaene C, De Looze D and Hindryckx P revised the paper.

Conflict-of-interest: The authors declare that they have no competing interests.

Open-Access: This article is an open-access article which was selected by an in-house editor and fully peer-reviewed by external reviewers. It is distributed in accordance with the Creative Commons Attribution Non Commercial (CC BY-NC 4.0) license, which permits others to distribute, remix, adapt, build upon this work non-commercially, and license their derivative works on different terms, provided the original work is properly cited and the use is non-commercial. See: <http://creativecommons.org/licenses/by-nc/4.0/>

Correspondence to: Pieter Hindryckx, MD, Department of Gastro-enterology, University Hospital Ghent, de pintelaan 185, 1K12, 9000 Ghent, Belgium. hindryckx@ugent.be

Telephone: +32-9-3322371

Fax: +32-9-2404984

Received: August 29, 2014

Peer-review started: August 29, 2014

First decision: September 30, 2014

Revised: October 16, 2014

Accepted: December 3, 2014

Article in press: December 10, 2014

Published online: January 16, 2015

Almost fifteen years have passed since the release of the small bowel capsule. The purpose of this review is to offer the reader a brief but complete overview on small bowel CE anno 2014, including the technical and procedural aspects, the possible complications and the most important indications. We will end with some future perspectives of CE.

Key words: Capsule endoscopy; Small bowel; Preparation; Procedure; Technology; Complications; Features; Enhancements; Indications; Future

© The Author(s) 2015. Published by Baishideng Publishing Group Inc. All rights reserved.

Core tip: This review covers all the relevant aspects of small bowel capsule endoscopy anno 2014. The current techniques, procedures, analyses, indications and future perspectives are discussed thoroughly. Easy-to-use flowcharts are provided to help the readers in their decision-making when confronted with small bowel pathology.

Van de Bruaene C, De Looze D, Hindryckx P. Small bowel capsule endoscopy: Where are we after almost 15 years of use? *World J Gastrointest Endosc* 2015; 7(1): 13-36 Available from: URL: <http://www.wjgnet.com/1948-5190/full/v7/i1/13.htm> DOI: <http://dx.doi.org/10.4253/wjge.v7.i1.13>

Abstract

The development of capsule endoscopy (CE) in 2001 has given gastroenterologists the opportunity to investigate the small bowel in a non-invasive way. CE is most commonly performed for obscure gastrointestinal bleeding, but other indications include diagnosis or follow-up of Crohn's disease, suspicion of a small bowel tumor, diagnosis and surveillance of hereditary polyposis syndromes, Nonsteroidal anti-inflammatory drug-induced small bowel lesions and celiac disease.

INTRODUCTION

Wireless Video capsule endoscopy (CE) was invented by Gavriel Iddan^[1] in the mid-1990s. Being able to visualize the entire small bowel in a noninvasive, well-tolerated way, CE has closed the diagnostic gap between conventional gastroduodenoscopy and colonoscopy. Since the official release of CE in 2001, almost 15 years have passed, and CE has revolutionized the diagnosis and treatment of

various small intestinal diseases. This review aims to provide state of the art on CE in gastrointestinal diseases. Both the evolution in technique and in indications will be discussed.

TECHNICAL PRINCIPALS, PROCEDURE AND ANALYSIS

Capsule definition

The wireless CE system consists of 4 main parts: (1) the single-use wireless Video Capsule; (2) sensor arrays or a sensor belt attached to the patient; (3) the data recorder attached to the belt; and (4) the computer workstation with the application software^[2-4] as can be seen in Figure 1 by Pan *et al*^[4].

The capsule weighs less than 4 g and measures about 11 mm in diameter × 26 mm in length. It is made of plastic, biocompatible and resistant to digestive fluids. The capsule contains a short focal lens and a miniature video camera: a charge-coupled device or Complementary Metal Oxide Semiconductor, which focuses the image. The gastrointestinal tract is illuminated by white light LEDs. The capsule is powered by two mercury free silver oxide batteries with a life span of 8-12 h. More than 5000 images are transmitted during this battery life at a rate of 2-6 fps. Capsule features have evolved since the release of the first capsule and nowadays standards are a 156-170° field of view, a high resolution and sharpness with a minimum size of detection of 0.07 mm, a 1:8 magnification, a more homogenous light exposure and a depth of view of at least 20-30 mm^[5]. The captured data are sent to the sensor arrays and belt worn by the patients by either ultra-high frequency band radio telemetry or human body communications, using the human body as conductor.

At present, there are three main companies supplying wireless CE systems by approval of the FDA. Given Imaging (Ltd, Yoqneam, Israel) supplying the PillCam® SB 3, Olympus America (Inc, Center Valley, Pennsylvania) supplying the EndoCapsule® and Intromedic Company (Ltd, Seoul, South Korea) manufacturing the MiroCam®. Although not approved by the FDA, another Chinese company, Jianshan Science and Technology (Group) Co., Ltd., Chongqing, has developed its own capsule: the OMOM capsule. The capsule has been approved by the State Food and Drug Administration of the People's Republic of China in March 2004 and is since then being used in China, Southeast Asia and some European countries^[6]. The first large clinical trials have reported a yield and completion rate similar to the PillCam, but the major advantage of the OMOM capsule is without doubt its price, which could be reduced by fifty percent^[6,7] (Table 1 and Figure 2).

Even though the three main capsules approved by the FDA differ in technical specifications, several trials have shown that they offer a comparable diagnostic yield, image quality and completion rate, as was stated in the systematic review by Koulaouzidis *et al*^[8].

Small bowel preparation

To ensure a clear view on CE, the patient is asked to start fasting 12 h before the small bowel CE procedure^[2,3]. However, due to bubbles, small intestinal fluid and biliary secretions coming from the major duodenal papilla, the visualization by the VCE can deteriorate. Furthermore, limited battery life span can hamper a complete intestinal examination in patients with delayed gastric emptying and small bowel transit, which necessitates the use of additional small bowel preparation^[3]. However, not all patients are eligible for small bowel cleaning. The 2012 Consensus guidelines for the safe prescription and administration of oral bowel-cleansing agents^[9] states that small bowel preparation is contraindicated in patients with gastrointestinal obstruction, perforation, ulceration, ileus, gastric retention or inflammatory bowel diseases (IBD), in patients with a reduced level of consciousness, swallowing disorders, hypersensitivity to the used agent and in patients having an ileostomy. The use of small bowel cleansing agents is relatively contraindicated in patients with chronic kidney disease or undergoing dialysis, in patients with a renal transplant, congestive heart failure, liver cirrhosis or ascites and in patients taking Renin-angiotensin blockers, diuretics or nonsteroidal anti-inflammatory drugs (NSAIDs). In these patients the utility of small bowel cleaning should be reconsidered and the choice of cleaning agent is of main importance: polyethylene glycol (PEG) is normally preferred over Sodium Phosphate. Patients taking Renin-angiotensin blockers, diuretics or NSAIDs are advised to discontinue their medication temporarily and their hydration and electrolyte status should be checked prior to the small bowel preparation. In a recent systematic review, Kotwal *et al*^[10] compared the results of various randomized-controlled trials regarding improvement of vision quality (VQ), diagnostic yield (DY) and completion rate (CR) by small bowel preparation. In this review, administration of 2L polyethylene glycol (PEG) the evening before VCE was found to be superior to two doses of 45 mL Sodium Phosphate before VCE regarding VQ and DY improvements. Another study by Kantianis *et al*^[11] showed that 2 L as well as 4 L PEG did not differ in small bowel cleansing and CR. Therefore 2 L should be preferred as regimen before VCE. Furthermore Kotwal *et al*^[10] stated that simethicone, an antifoaming agent, significantly improved the VQ by decreasing the bubbles without implications on CR. Yet no significant improvement in VQ and DY were observed by combining Simethicone with PEG. After meta-analysis prokinetics did not show a significant improvement in CR, so they are not recommended.

Procedure

After bowel preparation, the patient gets eight sensor arrays attached to his body and a sensor belt fastened around his waist. The data recorder is attached to the belt before capsule ingestion. The capsule is ingested with a glass of water and fluid restriction is needed till 2

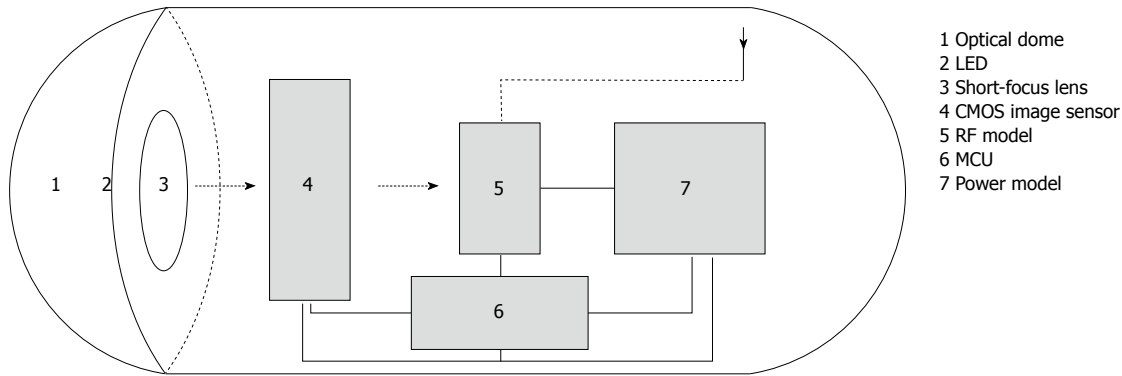


Figure 1 Main parts of the wireless capsule endoscope.

Table 1 Comparison between commercially available capsule endoscopy devices

Capsule	PillCam [®] SB 3 Given Imaging	EndoCapsule [®] Olympus America	MiroCam [®] Intromedic Company	OMOM [®] Jianshan Science and Technology
Size	Length: 26.2 mm Diameter: 11.4 mm	Length: 26 mm Diameter: 11 mm	Length: 24.5 mm Diameter: 10.8 mm	Length: 27.9 mm Diameter: 13 mm
Weight	3.00 g	3.50 g	3.25-4.70 g	6.00 g
Battery life	8 h or longer	8 h or longer	11 h or longer	6-8 h or longer
Resolution	340 x 340	512 x 512	320 x 320	640 x 480
	30% better than SB2			
Frames per second	2 fps or 2-6 fps	2 fps	3 fps	2 fps
Field of view	156°	145°	170°	140°
Communication	Radio Frequency Communication	Radio Frequency Communication	Human Body Communication	Radio Frequency Communication
FDA approval	Yes	Yes	Yes	No
Price per capsule	\$500	\$500	\$500	\$250

h after ingestion. After 4 h, fasting can be stopped. Daily activities do not need to be interrupted during CE.

Capsule propulsion needs to be followed by real-time viewing during the first hour to make sure the capsule passes the stomach. If not, gastroscopy is performed to deposit the capsule in the duodenum.

The sensor arrays and belt are removed once the capsule has been expelled into the colon (as verified by real-time viewing), or when the battery life has expired. Images can be downloaded from the recorder to the workstation. The capsule itself passes naturally with bowel movement and is usually excreted within 24 to 72 h.

Analysis

After downloading the data from the recorder to the workstation, images can be reviewed by gastroenterologists using the application software. Reading time and interpretation are around 40-120 min^[2,12] which can be, compared to conventional endoscopy, a time-consuming activity. A solution to this problem might be to train nonphysicians in pre reading the images. A study by Bossa *et al*^[12] found that a nurse with expertise in endoscopy might be able to shorten the time needed by the endoscopist to read a capsule. Moreover the pre reading of the CE by the nurse endoscopist led to a more careful approach of the physician in the flagged areas, which enhanced the accuracy of the CE

investigation. Another recent study by Dokoutsidou *et al*^[13] confirmed these findings and stated that despite a longer reading time, a nurse is perfectly capable of pre reading and subsequently flagging aberrant images. However, another possibility to lower reading time is the use of special software to select aberrant images, which can be revised afterwards. With the introduction of Quickview by Given Imaging, reading time could be reduced significantly. The Quickview software samples sites of interest for review at a chosen rate, but unfortunately missed lesions occur far more often, which is unacceptable^[14]. However, in certain clinical settings, such as overt obscure gastrointestinal bleeding (OGIB) in an urgent inpatient setting and suspected Crohn Disease or occult OGIB in outpatient setting, Koualouzidis *et al*^[15] found that Quickview could be used confidently without clinical consequences. To enhance the yield of CE, virtual chromoendoscopy was developed by adding colour filters to the images. Fuji Intelligent Colour Enhancement (FICE) was seen to be superior in detecting small bowel lesions and in particular angioectasias compared to conventional CE^[16]. In another trial by Krystallis *et al*^[17] Blue Mode (BM) was found superior to FICE in detecting lesions of the small bowel. Adding BM to Quickview studies however did not show any diagnostic advantage and is therefore not recommended^[15].




Figure 2 Types of small bowel capsule endoscopes. A: PillCam SB 3 (Given Imaging, Yoqneam, Israel); B: MiroCam (IntroMedic, Seoul, South Korea); C: Endo Capsule (Olympus America, Center Valley, PA); D: OMOM (Jinshan Science and Technology, Chongqing, China).

COMPLICATIONS AFTER CE

Capsule retention

Although very popular for its non-invasive character, CE can be the cause of unnecessary treatment due to complications. One of the most feared complications is capsule retention. It is defined as the presence of the capsule in the bowel lumen for a minimum of 2 wk after ingestion, or when the capsule is retained for an unspecified period of time unless targeted medical, endoscopic or surgical intervention is started^[18].

According to a systematic review by Liao *et al*^[19] overall retention rates are as low as 1.4%, which makes the procedure acceptable, regarding the high overall diagnostic yield of 59.4%. Furthermore, the retention rate differs according to the underlying pathology, with up to 2.6% in known Crohn's disease (CD) and 2.1% in patients with Neoplastic Lesions^[19]. This can be explained by the fact that capsule retention is usually caused by masses, strictures and stenotic areas resulting from neoplastic lesions, CD, NSAID consumption or post-operative adhesions, which narrow the small bowel lumen and favors retention^[20]. In this regard, known small bowel obstruction, strictures and extensive CD are a contraindication for CE^[21]. In a large study by Höög *et al*^[22] risk factors for capsule retention were identified. OGIB and suspected CD were associated with the lowest chance of capsule retention, whereas known CD and small bowel tumors had a higher chance of retention. These findings were also confirmed by other authors^[19,23].

Most of the time, retained capsules are asymptomatic, but intestinal obstruction, partial or complete, may occur, especially in case of known CD or neoplastic lesions. In the 2009 consensus by the European Society of Gastrointestinal Endoscopy it is recommended with a grade B evidence level to precede the CE by small bowel imaging or a patency capsule (PC) (cf. *infra*) in patients with suspected or established CD to rule out potential strictures. As said earlier, known small bowel obstruction is a contraindication for CE and patients at risk for a small bowel obstruction should therefore be carefully investigated by their physician before a CE procedure^[24].

Evacuation of the retained capsule can be spontaneously, medically or by surgery. The latter is unfortunately the most frequent intervention, but is on the other hand safe and can be seen as a required diagnostic and therapeutic tool for treating the underlying small bowel condition. With the surgery, not only the capsule is removed, but also the responsible lesion can be resected, which relieves the patient's symptoms. However retention can also lead to unnecessary surgery of lesions caused by, *e.g.*, NSAID or CD, for which a medical solution would also have been an option^[25].

In recent years, an endoscopic approach of capsule retention has become more popular as a less invasive alternative for surgery. Before capsule retrieval a radiographic localization of the capsule is done to determine whether an upper or lower gastro-intestinal and a standard (gastroduodenoscopy, Push Enteroscopy or colonoscopy) or advanced endoscopic approach

(device assisted enteroscopy) is needed. In this regard, surgery can be considered when endoscopic approaches did not manage to retrieve the capsule or when the patient presents with symptoms of toxicity^[26]. In a study by Van Weyenberg *et al*^[27] DBE showed to be an adequate tool to retrieve a retained capsule. Moreover the DBE was capable to aid in pre-operative staging by histological sampling. In conclusion DBE can prevent unnecessary surgery as well as determine the cause of the capsule retention before the operation, which is beneficial both for physician and patient.

Capsule perforation

Another yet very rare complication is perforation of the small bowel. Usually it results from capsule retention. In the few cases that are reported, CD was the most frequent underlying pathology causing the perforation^[20,28-31]. In a study by Repici *et al*^[28] a possible explanation for this complication is given. CD affects the tissue of the small bowel wall and makes it vulnerable. By the complete luminal occlusion due to the entrapment of the capsule and the high peristaltic activity the fragile tissue of the small bowel wall distends just above the capsule and leads to fissuration and possible perforation of this area. One study by Gonzalez Carro *et al*^[32] reported perforation after CE in a patient with a history of surgery with subsequent adhesions. Because of the major implications, perforation should be acknowledged as a possible complication after CE in patients with known or suspected CD.

Capsule interference

One of the relative contra-indications for CE is the presence of implantable cardiac devices, such as pacemakers, ICDs, pulsatile and nonpulsatile LVADs. Interference may arise during the CE procedure resulting in an alteration of atrial or ventricular assistance^[33]. This is however a theoretical assumption without clinical significance, because few studies show actual interference between cardiac devices and CE. Moreover, previous studies have already suggested that CE can be used safely in patients with these devices^[34-41]. Only one study by Dubner *et al*^[42] reported oversensing of an ICD due to interference with the CE procedure, which resulted in an inappropriate shock by the cardiac device. In another case report by Guyomar *et al*^[37] interference between pacemaker and video capsule occurred, resulting in a failure of recording by the capsule when close to the pulse generator. Harris *et al*^[43] found similar results in a 2013 study: all implantable devices proved to be safe for the patient, but LVAD had the tendency to interfere with image capture and therefore a CE lead position as far away from the LVAD as possible is required. On the other hand, in the article by Cuschieri *et al*^[40] no loss of images was observed. In conclusion, close monitoring is recommended in patients with implantable cardiac devices but the risk for complications seems to be extremely low.

Capsule aspiration

Some cases have reported the existence of bronchial aspiration of the capsule. It is a very rare complication, which occurs in one out of every 800 investigations and can be asymptomatic^[44]. CE aspiration can resolve spontaneously^[45], but often necessitates immediate radiological investigations to localize the capsule, followed by bronchoscopy to retrieve it with the aid of a Roth Net^[44]. To prevent this unnecessary invasive procedure, screening for patients at risk should be done. Risk factors include aging, neurological or swallowing disorders and patients with a weak or absent cough^[46,47]. Direct placement of the capsule in the gastrointestinal tract should be considered in these patients^[44-46,48]. If not, the Real Time Viewer should be used during the ingestion of the capsule to make sure that the capsule reaches the gastrointestinal tract^[46-48].

Until now, only one fatality has been reported due to intracerebral haemorrhage resulting from capsule aspiration^[47]. The reason for this low mortality rate is hypothesized in a study by Lucendo *et al*^[44] stating that the size of the capsule is not capable to block the total lumen of the trachea and therefore still allows adequate oxygenation after capsule aspiration. However Koulaouzidis *et al*^[49] found that the CE size might be correlated with the chance of aspiration.

ADDITIONAL FEATURES AND ENHANCEMENTS IN THE FIELD OF CE

Suspected blood indicator

In 2003 Given Imaging introduced the Suspected Blood Indicator (SBI) as an aid in diagnostics. The new feature highlights images suspected for redness or blood, which makes it easier for physicians to identify possible bleeding sites accurately. The software is activated when the capsule has reached the duodenum and operates only during its stay in the small bowel^[50].

Sensitivity of the SBI software is determined by the presence of active bleeding. In studies, sensitivity ranges from 20% to 56.4% and increases up to 58.3% to 93% in case of active bleeding^[50-52]. However, sensitivity and specificity of SBI remains too low, so complete review by a gastroenterologist is still required and the SBI only serves as rapid screening tool for actively bleeding lesions^[51,52].

The detection rate of the SBI is affected by background color of the small bowel as by velocity of the capsule^[50]. This is also a possible explanation for the variation in sensitivity observed among different studies. The background of the small bowel differs according to patient's condition and small bowel preparation^[50]. In experimental small intestine models, a very pale magenta background showed the highest detection rate, followed by burnt sienna and yellow. Lowest detection rates were observed in small bowel sites with colors significantly different from the normal small bowel color or when the capsule reached a high velocity. In an interesting study by

Buscaglia *et al*^[53] SBI was found to be an inferior screening tool for sites of potential bleeding with a sensitivity below 60% even in active bleeding. Yet they found that in CD the SBI could be used as a screening tool for detection of aberrant mucosa with high sensitivity. Another study by D'Halluin *et al*^[54] also rejected the SBI software as a useful tool for screening the small bowel stating that the detection rate was poor, independent of the type of lesion. Furthermore they found that the SBI missed certain lesions while tagging few others and that irrelevant flagging might unnecessarily prolong the reading time of the CE. However, in a recent study Tal *et al*^[55] stated that SBI is a reliable aid in excluding active bleeding or major lesions, but that the role of the endoscopist could not be neglected. In summary we can conclude that SBI might improve the interpretation and thereby the yield of CE by tagging areas for a second review, but can certainly not replace the gastroenterologist's review.

PC

To address the problem of capsule retention, the Agile PC was developed by Given Imaging. The PC with the same size as a video capsule, serves as dummy to assess the patency of the small bowel prior to CE examination. As one of the major contraindications for CE is suspicion of small bowel stenosis, routine administration of PCs could enable safe CE use in a larger patient population by ruling out possible stenoses^[56]. The PC system consists of two main parts: the capsule itself with a radiofrequency identification tag (RFID tag) and an external detector system to capture radio-frequency signals.

The PC is made of lactose and 10% barium, which dissolves when coming into contact with intestinal fluids through the window at the edge of the capsule, also known as timer plug. To insure that the timer plug is not blocked by capsule impaction in a stricture, the second generation PCs consist of two timer plugs. If excretion does not occur, dissolution starts at 30 h. After 35 h, 38 percent of the capsules are dissolved and all are dissolved within 72 h^[57]. After dissolution, the remains of the capsule encounter no difficulties to pass the small bowel strictures.

The detector system receives the radio-frequency signals coming from the RFID tag and reconstructs the exact capsule position. This can also be done by using radiography, which visualizes the PC by its radiopaque RFID tag or 10% barium^[56]. Localization can be complicated by overlap of intestines so subsequent fluoroscopy or CT scan can be warranted. One drawback of the RFID tag system is the probability of impaction in a stricture, which can lead to small bowel ileus^[58]. Recently a new tag-less PC was developed by Given Imaging to overcome this issue and proved its usefulness as found by Nakamura *et al*^[58].

The PC procedure is not as strict as the CE procedure. The capsule can be swallowed without previous food restrictions. If the capsule is not excreted in 33 h,

further examination is warranted to localize the PC and make a distinction between a small bowel and a colonic localization. The latter is still an indication for VCE. The subsequent CE has to be done quickly after PC so a possible change of stricture status and subsequent capsule retention is avoided^[56].

The use of the PC still remains controversial. Although some authors have reported its utility^[59-61], others have found that the capsule was not capable of confirming stenoses, which were found on CT or small bowel follow through^[62]. In conclusion, patients still benefit from a CT investigation prior to CE to exclude possible stenosis and strictures.

CapsoCam capsule

Over the last decade, a new player entered the field of CE. CapsoCam by Capsovision renewed the concept of CE by offering a capsule with a 360° view and on-board storage, which enables the retrieval of images wire-free after interception of the capsule in the feces. The capsule contains four cameras, which offer high resolution images and a frame rate up to 20 fps max. Furthermore, two new technologies were developed, Smart Motion Sense Technology and Auto Illumination Technology. Smart Motion Sense Technology enables the capsule to activate its cameras only during capsule motion. When the capsule is stationary, a sensor is used to compare the current frame with the previous frame to control reactivation. Auto Illumination Technology controls the 16 white LEDs to provide the optimal level of illumination. When the capsule is located nearby the walls, a low light intensity is optimal to capture the best images. A position further away from the wall necessitates a higher light intensity. By adding these software features, battery life is sustained up to 15 h. The first clinical trial that used the CapsoCam accepted it as a safe and efficient tool in small bowel evaluation^[63]. In a recent French study by Pioche *et al*^[64] the concordance between the PillCam SB2 and CapsoCam was evaluated in terms of diagnostic yield and image quality. A kappa value of 0.63 was obtained, which confirms the good concordance between the two capsules. Although the reading time of the CapsoCam was longer, the CapsoCam detected significantly more lesions in a per lesion analysis.

Three-dimensional representation

In recent years, three-dimensional representation is becoming a hot issue. By reproducing the depth information lost by camera recording, diagnosis can be facilitated, because the texture and the abnormalities of the mucosa are highlighted. 3-D rendering can be software- or hardware-based. The latter is limited by the technological possibilities of the capsule, so software based 2-D to 3-D conversion is used^[65,66]. Software-based 3-D rendering uses algorithms to recreate the third dimension. In a study by Karargyris *et al*^[67] four Shape-from-Shading (SfS) algorithms were compared. The Tsai's SfS algorithm excelled the other algorithms in

visualization improvements, but we may not forget that the evaluation criterion was subjective in origin. However, the Tsai's SFS algorithm is especially adapted to bright and round surfaces, therefore perfectly applicable in small bowel endoscopy.

Lesion localization

Apart from the image quality, accurate lesion localization is one of the key elements of CE, because further therapeutic steps, non-invasive and invasive, can depend on the exact localization of the lesion^[68]. Lesion localization is currently estimated according to the transit time and the use of pylorus and caecum as landmarks, but lacks precision.

Exact localization can be determined by using a capsule emitting a magnetic field or electromagnetic waves. Both methods have their advantages and drawbacks. Magnetic-field-strength-based localization is not attenuated by the human body and the capsule does not have to be aligned with the detectors to be detected. As a drawback, interference of the magnetic fields for capsule localization and the magnetic fields for active capsule movement in the future (cf. *infra*) may occur. On the other hand electromagnetic waves localization, such as the previously mentioned RFID tag, is based on radio-frequency waves, which are attenuated by the human body and therefore may lose precision. A promising step forward in capsule localization is the development of a new software by Olympus Medical Systems Corporation (Tokyo, Japan), which uses a 3D-triangulation. The exact capsule position is calculated by determining its distance from the 6 radiofrequency sensors using radiofrequency signal strength. In the study by Marya *et al*^[69] an average localization error of 13.26 cm³ by attenuation was observed, especially in patients with an increased BMI.

Finally, in 2010 the Capsule-odometer, a conceptual CE design, was proposed by Karargyris *et al*^[70] which in theory offers a more accurate lesion localization. The capsule has two protruding wheels attached to a spring-mechanism, so the wheels can adapt to the diameter of the intestinal lumen, serving as a micro-odometer with subsequent accurate lesion localization, calculated from the onset of the capsule investigation. This design also offered a greater stability, avoiding non-forward movement through the gastrointestinal tract. Further experiments and research are needed on this subject.

MAJOR INDICATIONS FOR SMALL BOWEL CE

CE has been approved for various indications. These include (1) overt and occult obscure gastrointestinal bleeding; (2) suspected CD; (3) surveillance in patients with polyposis syndromes and detection of small bowel tumors; (4) screening and evaluation of NSAID side-effects; and (5) suspected malabsorptive syndromes such as celiac disease. These indications will be explained further on in this paper. Relative contra-indications

for CE include, like mentioned before: (1) known or suspected GI obstruction, strictures or fistulas; (2) cardiac devices; (3) swallowing disorders; and also (4) pregnancy.

Obscure gastrointestinal bleeding

Obscure gastro intestinal bleeding (OGIB) is defined as bleeding of unknown origin that persists or recurs following a bidirectional negative endoscopic evaluation of the gastrointestinal tract. OGIB is a common problem encountered by gastroenterologists, and accounts for approximately 5% of all GI bleedings^[71]. OGIB can be overt (melena, hematochezia, hematemesis) or occult (iron-deficiency anaemia, IDA, with or without a positive fecal occult blood test). OGIB is mostly caused by a lesion located in the small bowel, but can also originate from a lesion in the other parts of the GI tract as well, missed with conventional endoscopy because of intermittent bleeding or by human error^[72]. The underlying pathology is age dependent. Under the age of 40, the most frequently detected lesion is a small bowel tumor, followed by Meckel's diverticulum, Dieulafoy's lesion and CD. Above the age of 40, vascular lesions such as angiodysplasia are most frequently observed, counting for up to 40% of the underlying lesions. NSAID-induced lesions (cf. *infra*) are the second most frequent finding on CE^[71].

Since its development in 2000, CE has mainly been used for the indication of OGIB, accounting for 60%-70% of the patients^[8]. CE has proven superiority to all other diagnostic modalities in OGIB, such as barium contrast radiology, small bowel computed tomography (CT), magnetic resonance imaging (MRI), push enteroscopy and angiography, as can be seen in Table 2. The American Society for Gastrointestinal Endoscopy (ASGE) confirmed these findings in their guidelines presented in 2007^[71]. Before using CE as a diagnostic tool, at least one gastroduodenoscopy and ileocolonoscopy have to be performed to rule out upper and lower gastrointestinal tract abnormalities. Repeating gastroscopies or colonoscopies immediately prior to CE in patients who have not had endoscopic investigations for more than 6 mo, tends to have a low diagnostic yield and is not cost-effective^[73]. Therefore, CE is recommended as the first-line investigation after negative bidirectional endoscopies. Younger patients however have a higher chance of IBD or tumours and a CT abdomen is indicated prior to CE to rule out stenosis^[20]. A gynaecological etiology has to be considered in young females.

The overall yield of CE is between 35% and 83% for OGIB^[19,71,72,74-80] with its mean around 60%^[81,82]. Diagnostic yield is influenced by the type of bleeding. Patients with ongoing overt bleeding usually present with a higher diagnostic yield than patients with obscure-occult bleeding, presenting as IDA^[72,83]. More factors associated with a higher diagnostic yield have been identified, including low hemoglobin measurements, transfusion need, older age and a short interval of less

Table 2 Comparison of different diagnostic modalities in obscure gastrointestinal bleeding

Ref.	Country	Design	No. of patients	Comparator	Yield of CE, (%)	Yield of Comparator, (%)	Significant difference? (yes/no)	CE superior? (yes/no)	Other
Triester <i>et al</i> ^[80]	United States	Meta-analysis and Systematic review	396	PE	63	28	Yes	Yes	NNT = 3 to yield one additional clinically significant finding with CE
			88	SB radiography (barium contrast and enteroclysis)	67	8	Yes	Yes	NNT = 3 to yield one additional clinically significant finding with CE
Leighton <i>et al</i> ^[82]	United States	Meta-analysis and Systematic review	396	PE	63	28	Yes	Yes	Yield of significant findings: CE = 56% vs PE = 26%, NNT = 3 to yield one additional clinically significant finding with CE
			88	Barium radiography	67	8	Yes	Yes	Yield of significant findings: CE = 42% vs SB barium radiography = 6%, NNT = 3 to yield one additional clinically significant finding with CE
			42	Intraoperative enteroscopy	83	83	No	No	
			17	Mesenteric angiography	47	53	No	No	
Chen <i>et al</i> ^[205]	China	Meta-analysis and Systematic review	277	DBE	61	56	No	No	CE was superior if no combination of oral + anal approach <-> DBE was superior when a combination of the two insertion approaches was done
Pasha <i>et al</i> ^[95]	United States	Meta-analysis and Systematic review	397	DBE	24	24	No	No	CE should be the initial diagnostic test for determining insertion route of DBE
Arakawa <i>et al</i> ^[76]	Japan	Retrospective Study	162	DBE	54	64	No	No	
Teshima <i>et al</i> ^[77]	Canada, The Netherlands	Meta-analysis and Systematic review	651	DBE	62	56	No	Yes	Yield of DBE after positive CE = 75.0% <-> yield after negative CE = 27.5%
Leung <i>et al</i> ^[206]	China	RCT	60	Mesenteric angiography	53	20	Yes	Yes	No significant difference in the long-term outcomes (transfusion need, hospitalization for rebleeding, mortality)
Wang <i>et al</i> ^[207]	China	Meta-analysis and Systematic review	279	CT	53	34	Yes	Yes	Complementary role to CE and can be used as a triage tool prior to DBE in evaluating OGIB

PE: Push enteroscopy; CE: Capsule endoscopy; SB: Small bowel; NNT: Number needed to treat; DBE: Double balloon enteroscopy; RCT: Randomized controlled trial.

than 3 d between admission and the CE procedure^[84-88]. CE is recommended in all cases of OGIB because of its diagnostic value and its impact on further management. A study by Albert *et al*^[75] found that CE was able to determine the therapy in 66% of the cases and led to an alteration in management in 32.3% of the cases. This is in line of previous studies, which reported that CE could alter subsequent management in 23%-66% of the cases^[79,85,89-91]. Sidhu *et al*^[84] found that this management alteration could be predicted by patient comorbidity or angiodysplasia findings on CE.

The reason why CE has been recommended as first-line examination tool over DBE after initial negative upper and lower endoscopies is its noninvasive nature and

ease of use, which makes it well-tolerated and feasible in an outpatient setting^[92]. Furthermore its ability to visualize the whole small bowel in more than 80%-85% of the cases^[93,94] and the ability to determine the initial DBE approach makes it a helpful tool in OGIB diagnostics^[92,95]. However, CE often fails to visualize lesions in the proximal small bowel, in a Roux-en-y loop and in patients presenting with diverticula^[76].

If necessary, a CE procedure can be followed by a double balloon enteroscopy (DBE) procedure^[72]. DBE is the only diagnostic tool showing a similar diagnostic yield for OGIB as VCE, as can be seen in Table 2. However, the DBE procedure is more invasive, can be time-consuming, requires training, needs sedation or general

anesthesia and can have a complication rate of up to 4.3% in therapeutic procedures as was reported by Mensink *et al.*^[96]. Moreover DBE is not always able to visualize the whole small bowel. A completion rate of only 62.5% was achieved in DBE, compared to 90.6% in CE as reported by Nakamura *et al.*^[94]. Yet, DBE is preferred over CE in patients requiring a biopsy or a therapeutic intervention such as argon plasma coagulation (APC). Also DBE tends to have an acceptable yield in patients with an initial negative CE and suspicion of a small bowel lesion^[95,97], although it has been reported being much lower than the yield of DBE following a positive CE, respectively 28% and 75%^[77].

Not only clinically, but also economically is CE recommended as first line investigation of OGIB. It has shown to be more cost-effective than DBE when only visualization of the small bowel is needed^[98]. Negative CE investigations usually do not require further diagnostic work-up, which saves money in the long term, because reimbursement for CE is less than for DBE^[93]. A mean cost-saving of €1738.07 was reported by Marmo *et al.*^[99] when CE was preferred over other modalities in OGIB and turned out to be positive. However, only reimbursement costs were evaluated, so the cost of the hospital and the personnel was not taken into account.

If a therapeutic intervention is needed with a probability of more than 25%, gastroenterologists should consider the use of DBE as initial therapeutic option to minimize costs^[93]. Furthermore, cost equalization of DBE and CE was reached at 100 procedures for diagnostic DBE and 79 procedures for therapeutic DBE, which suggests that DBE is especially cost-effective in large-scale hospitals, with a substantial number of DBE procedures per year. Another study by Gerson *et al.*^[100] found that, regardless of the cost, DBE procedure was more cost-effective than CE-guided DBE procedure, because no additional costs were charged regarding further examinations and therapy could be given instantly. However, the workload for physicians would significantly increase if an initial DBE would be done and we may not forget that DBE is correlated with a higher rate of complications compared to CE. CE-guided DBE was associated with better outcomes in the long term because of fewer potential complications and fewer utilization of endoscopic resources. This can be explained by the high negative predictive value of CE, which leads to a reduction in the subsequent DBE procedures^[92,100].

When CE is negative, the chance of rebleeding is low, so that further investigations can be deferred, even when a second test might be diagnostic^[101-103]. Rebleeding was reported to be higher in CE-positive patients and patients using anticoagulants^[103]. Nonetheless, gastroenterologists should consider close monitoring, alternative modalities in suspicious cases because the chance of rebleeding has been reported up to 28.4% and 35.3% during a median follow-up of respectively 23.7 mo and 31.7 mo^[104,105]. Repeating the CE procedure however should only be considered if the bleeding presentation switches from

occult to overt bleeding or the hemoglobin level drops with more than 4 g/dL^[106]. Diagnostic yield of a repeated CE was reported to be between 35% and 75% and a subsequent management change was reported in 39% to 62.5% of the patients^[107,108].

To conclude this chapter about OGIB, we have made a flow-chart to represent the current knowledge in this field. For this purpose we included the reviewed articles in previous flow charts^[18,109] (Figure 3).

CD

Non-stricturing CD is the second main indication for CE. CD is a type of chronic IBD which may affect the whole gastrointestinal tract and lead to mucosal and transmural damage. Categorization of patients with CD is done based on the disease presentation: solely the small bowel (30%-35% of the patients), the small bowel and the large bowel (45%-50%) or only the large bowel (20%)^[110]. So even though it primarily affects the terminal ileum, the ileocecal region and the large bowel, one third of the patients presents with only small bowel inflammation which challenges gastroenterologists to diagnose the disease. Traditionally small bowel involvement was diagnosed by radiological procedures, small bowel barium radiography, CT, colonoscopy with ileoscopy or enteroscopy. But with the invention of CE, new possibilities in CD diagnostics have become available.

CE can be very helpful in the diagnosis of new cases of Crohn and in the evaluation of known CD, with regard to the activity and extent of the disease. CE is reserved however for cases with unexplained symptoms, when other investigations remain inconclusive or when CE would affect the management of the patient^[111]. So both in suspected as established CD, CE usually is performed third after a negative colonoscopy and ileoscopy, thereby replacing the traditional modalities. CE is considered positive for CD when more than 3 ulcerations are identified in the absence of NSAID use^[111-113] or when 4 or more obvious clear ulcers, erosions, or a region with clear exudate and mucosal hyperemia and edema are seen^[114].

Like in OGIB, CE also has shown a superior yield for detecting early inflammatory lesions in the small bowel comparing to all other modalities as can be seen in Table 3. The yield of CE in non-stricturing CD has been reported to be between 18% and 96%^[81,95,115-119]. Triester *et al.*^[81] only found a significant difference in yield between CE and other modalities for diagnosing non-stricturing small bowel CD. However, a distinction should be made between suspected and established CD. The reported superior yield was only significant for evaluating established CD and was not reported for diagnosis of small bowel CD in patients with a suspected initial presentation of the disease. This was contradicted by Dionisio *et al.*^[115], who found that CE has a superior yield compared to small bowel radiography (SBR), CT enterography (CTE) and colonoscopy with ileoscopy in the diagnosis of suspected CD patients. Although the

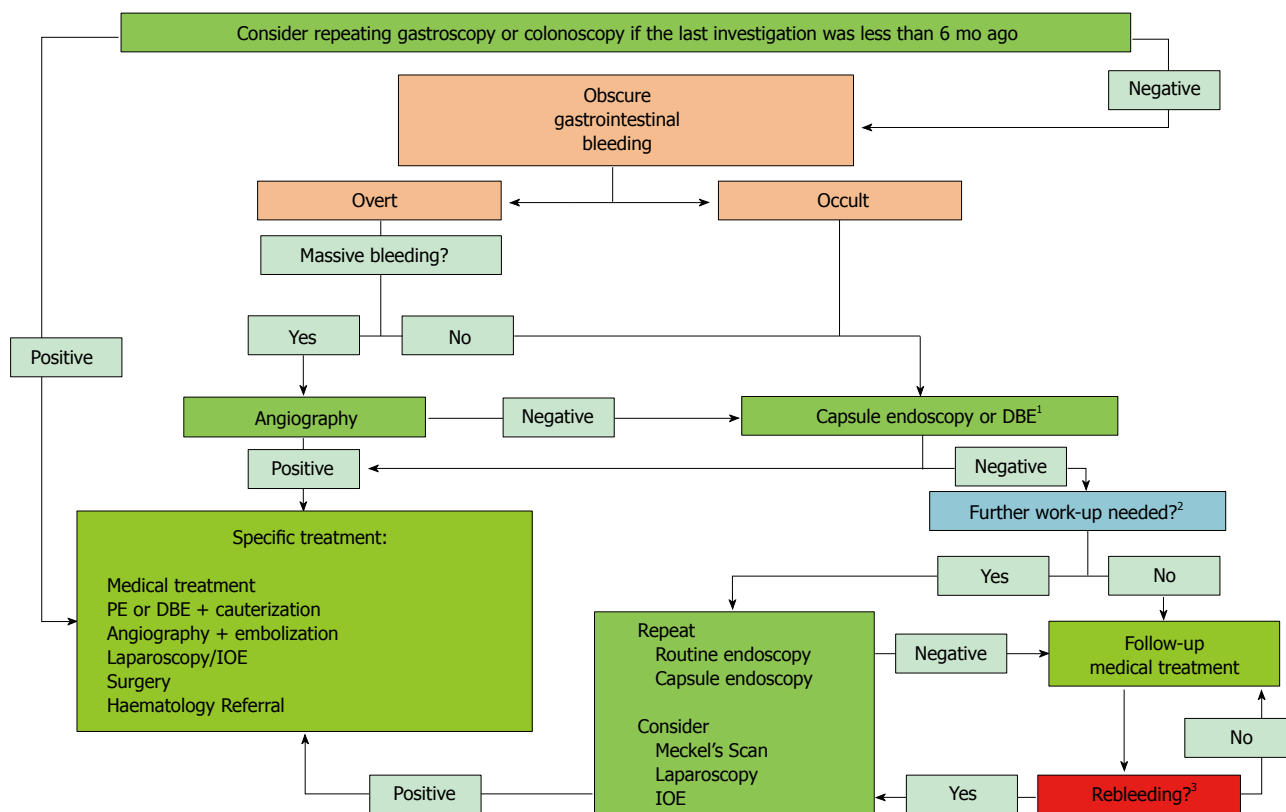


Figure 3 Recommended approaches for diagnosis and treatment of obscure gastrointestinal bleeding. ¹DBE is recommended in (1) patients requiring a biopsy or a therapeutic intervention (2) patients with an initial negative CE and suspicion of a small bowel lesion (3) large scale hospitals or (4) hospitals where CE is not available; ²If a lesion is suspected, further work-up is needed; ³Rebleeding was defined as a change from occult to overt bleeding or a hemoglobin level drop more than 4 g/dL. DBE: Double balloon enteroscopy; PE: Push enteroscopy; IOE: Intraoperative enteroscopy; Routine endoscopy: Uni/bidirectional endoscopy.

yield of CE in CD is high, the proportion of CD patients diagnosed with CE is rather low (0%-4%). Only in young patients presenting with abdominal pain plus diarrhea a 30% chance of diagnosing CD was achieved^[114]. In established CD patients, CE was reported to be superior compared to SBR, CTE and PE, which was the same according to previous findings^[115]. When compared to CT enterography and MR enterography, CE shows superior yields in the first two-thirds of the small bowel, but loses this superiority in the last portion of the small bowel by showing a yield similar to the comparators^[120,121]. However, we may not forget that MR enterography is also capable of visualizing the small bowel surroundings, so that transmural and extra-intestinal manifestations can be diagnosed^[122]. A recent study by Leighton *et al*^[123] found that a combination of colonoscopy with ileoscopy and CE achieved a far more high yield than patients investigated with a combination of colonoscopy with ileoscopy and small-bowel follow-through (SBFT). They confirmed the role of CE as valuable third diagnostic option in diagnosis of suspected CD, when colonoscopy and ileoscopy turned out to be negative or inconclusive.

In patients with suspected CD, Girelli *et al*^[119] found that, presuming a pre-test probability of CD of 50%, a positive CE was capable to raise the post-test probability up to 85% and if the CE was negative, it was capable to lower the probability to only 5%. In patients with

established CD, the use of small bowel CE in monitoring therapy response is still a controversial issue. Many reports found that the clinical and biological response to treatment is not correlated with mucosal healing, which is monitored on CE, so it has not proven useful in this respect^[124].

Caution should be taken when evaluating CEs positive for small bowel lesions. Because of the potential of CE to detect early lesions, CD-induced lesions are often non-specific and can be confused with NSAID-induced lesions. Both CD and NSAID-induced small bowel injury show endoscopically similar lesions and because of the inability of CE to take biopsies, the differential diagnosis remains inconclusive. Pathognomonic however for NSAID-induced lesions are the concentric diaphragmatic strictures in the ileum seen on endoscopy, which can lead to small bowel obstruction^[125]. According to Doherty *et al*^[126] the problem of false positive capsules also overestimates the incremental yield of CE compared to other modalities, necessitating a diagnostic golden standard to overcome the problem of premature CD diagnoses. Currently, there are two scores available to assess and monitor mucosal disease activity on CE. The CE CD Activity Index (CECDAI or Niv score) and the Lewis score are only recently developed and still have to prove their usefulness in standardizing the diagnosis of CD on CE before being widely accepted in clinical

Table 3 Comparison of different diagnostic modalities in Crohn's disease

Ref.	Country	Design	No. of patients	Comparator	Yield of CE, (%)	Yield of Comparator, (%)	Significant difference? (yes/no)	CE superior? (yes/no)	Other
Marmo <i>et al</i> ^[117]	Italy	RCT	31	SB radiography (enteroclysis)	71	26	Yes	Yes	Terminal ileum: yield 89% <i>vs</i> 37% Proximal SB: yield only 46% <i>vs</i> 13%
Chong <i>et al</i> ^[208]	Australia	Blinded prospective trial	43	SB enteroclysis PE	77 77	19 14	Yes Yes	Yes Yes	Results are in patients with a history of CD
Triester <i>et al</i> ^[81]	United States	Meta-analysis and Systematic review	250	SB barium radiography	63	23	Yes	Yes	NNT = 3 to yield one additional diagnosis with CE
			114	Colonoscopy with ileoscopy	61	46	Yes	Yes	NNT = 7 to yield one additional diagnosis with CE
			93	CT enterography/CT enteroclysis	69	30	Yes	Yes	
			84	PE	46	8	Yes	Yes	
			18	MR enterography	72	50	No	Yes	
Solem <i>et al</i> ^[118]	United States	Blinded prospective trial	41	CT enterography	83	83	No	No	Specificity of CE (53%) was significantly lower than the other tests
				Colonoscopy with ileoscopy	83	74	No	Yes	
				Small bowel follow-through	83	65	No	Yes	
Pasha <i>et al</i> ^[95]	United States	Meta-analysis and Systematic review	343	DBE	18	16	No	No	
Dionisio <i>et al</i> ^[115]	United States	Meta-analysis and Systematic review	428	SB barium radiography	52	16	Yes	Yes	
			236	Colonoscopy with ileoscopy	47 (71) ¹	25 (36)	Yes	Yes	Suspected CD (Established CD)
			119	CT enterography	68 (71)	21 (39)	Yes	Yes	Suspected CD (Established CD)
			102	PE	66	9	Yes	Yes	Established CD
			123	MR enterography	55 (70)	45 (79)	No	Yes (no)	Suspected CD (Established CD)
Lu <i>et al</i> ^[116]	China	Retrospective Study	50	Colonoscopy with ileoscopy	96	66	Yes	Yes	Combination of two methods showed a higher yield, but no significant differences were reported between each two examinations
			34	CT enterography	96	85	Yes	Yes	
			39	Small bowel follow-through	96	67	Yes	Yes	

¹Extra information between brackets is specific for Established Crohn's disease. PE: Push enteroscopy; CE: Capsule endoscopy; SB: Small bowel; NNT: Number needed to treat; DBE: Double balloon enteroscopy; RCT: Randomized controlled trial.

practice as an objective tool of mucosal inflammation measurement^[127,128]. Although the yield of CE has been questioned by these diagnostic problems, CE still remains a valuable tool in the diagnosis of CD: a recent study by Hall *et al*^[129] found a very high negative predictive value in the long term despite the questioned yield in patients with suspected CD, which makes it capable of safely ruling out suspected CD.

As mentioned before, capsule retention is especially feared in patients with CD because of possible strictures and stenosis. The reported 2.6% by Sharaf *et al*^[130] has

made small bowel imaging a standard exam previous to the CE procedure^[19]. MR is a useful tool to assess patency of the small bowel^[131]. Another possibility is the use of the previously discussed Pillcam PC (Given Imaging, Yoqneam, Israel), which indicates patency if the capsule is excreted intact or the scan has lost the RFID tag signal 30 h after ingestion^[132], so the CE procedure can be done to evaluate the mucosal surface of the small bowel.

Cost analyses for CE in CD have been made and showed that colonoscopy with ileoscopy followed by a CT enterography was the most cost-effective choice

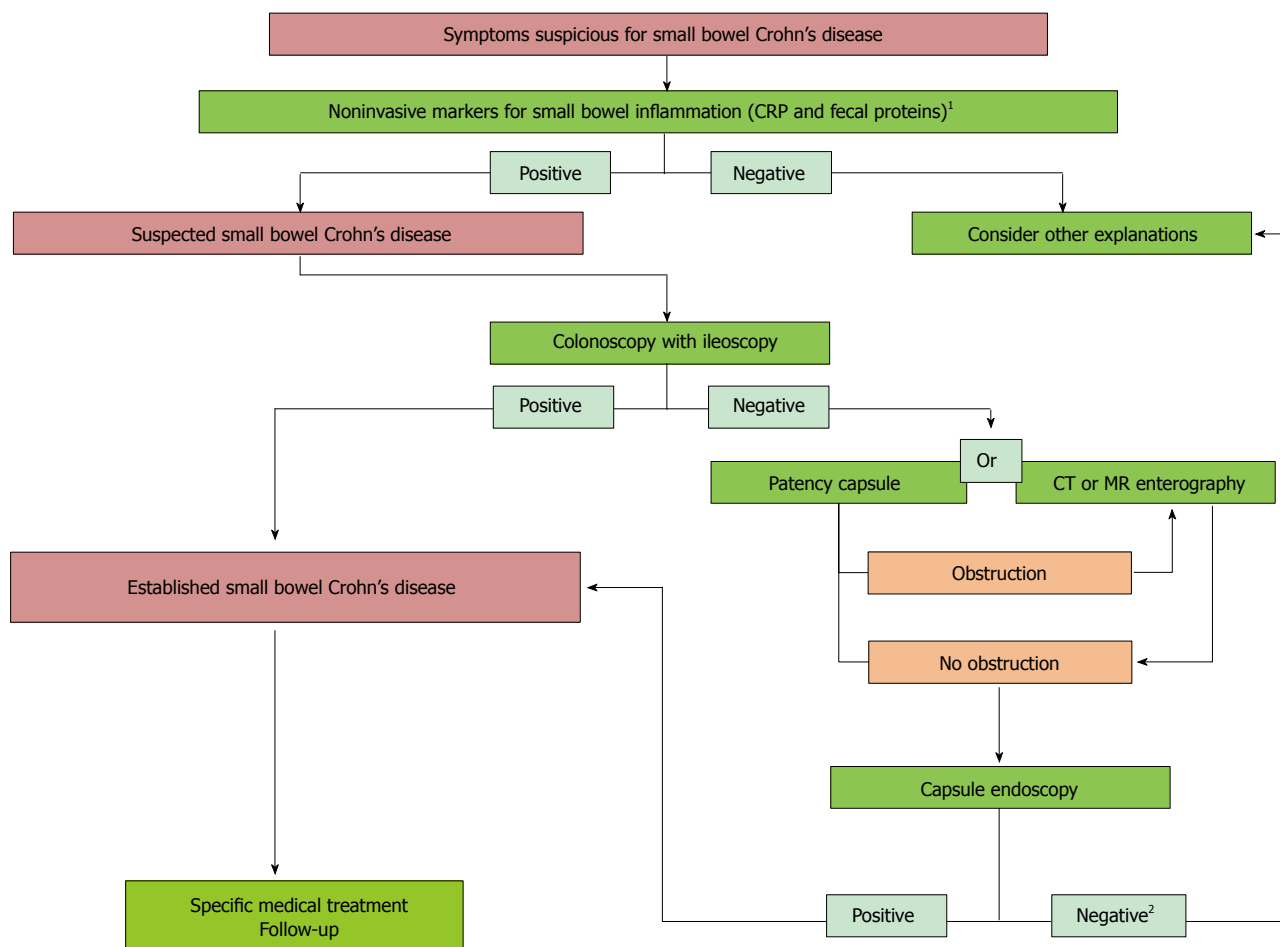


Figure 4 Recommended approaches for diagnosis and treatment of Crohn's disease. ¹Non-invasive markers have proven to be useful in giving baseline information about the presence of small bowel inflammation; ²If capsule endoscopy (CE) is negative, Crohn's disease can be ruled out due to the high negative predictive value of CE. In that case, other explanations should be considered. CRP: C reactive protein.

among the different diagnostic options in patients suspected of CD^[133]. Moreover, CE was proven to be not cost-effective as third diagnostic option, because of the high false positive rate, the diagnostic yield and the low pre-test probability of CD. Sharaf *et al*^[130] confirmed these findings and concluded that CE is not a valuable option in patients with suspected CD. However, Leighton *et al*^[134] found that CE did play a significant role in early diagnostics of CD, because it did not necessitate repeated procedures, physician visits and hospital stays, so direct costs could be reduced. Further investigation on this matter is needed.

In summary, CE has a superior diagnostic yield when compared to other modalities in suspected as well as established small intestinal CD. However, the question if this superior yield is due to false positive results remains unanswered. With the development of two scoring systems, this problem might be solved in the near future. Still, CE is a promising tool in CD diagnostics because of its capability to early diagnose small bowel lesions. We conclude with a flow chart based on the ICCE flowchart^[131] and Mergener *et al*^[109] with incorporation of new evidence^[124,129] (Figure 4).

Surveillance of polyposis syndromes and detection of small bowel tumors

Small bowel tumors make up only 3%-6% of the gastrointestinal neoplasm cases despite the 90% of the gastrointestinal tract surface the small bowel covers, which makes it a difficult entity to diagnose^[135,136]. The most frequently observed tumors are adenocarcinoma, gastrointestinal stromal tumor, carcinoid, lymphoma and sarcoma^[137-140]. Symptoms are rather unspecific and include anaemia or overt OGIB and later abdominal pain, nausea, vomiting, weight loss and anorexia^[141,142]. Thereby tumors are mostly found on CE or DBE when investigating patients with OGIB^[80,139,140,143]. A study by Singeap *et al*^[137] reported a detection rate for small bowel tumors of 4.9% in patients presenting with OGIB or other nonspecific symptoms. Other studies have found a tumor detection rate of 6%-12% on CEs done for OGIB^[144]. The insidious process often is responsible for the delayed diagnosis of a patient, which impacts the further management of the patient^[145]. Fast tumor detection is therefore very important, since management can be changed accordingly and outcomes can be improved even in malignant lesions if metastasis is

absent^[146]. Small bowel tumors can be benign, potentially malignant, malignant or metastatic. However the majority, 60%, of these tumors are malignant^[144], and differentiation between benignant and malignant cannot be made on CE. Tumors mostly appear as masses or polyps, but also can present as ulcers and stenoses in a minority of the cases. Hereditary polyposis syndromes like Familial Adenomatous Polyposis (FAP) and Peutz-Jeghers Syndrome (PJS), are another entity and apart from the colon polyposis, patients often develop benignant small bowel pathology with a high tendency to evolve into cancer^[147].

CE was evaluated for small bowel tumors and hereditary polyposis syndromes and turned out to be a valuable diagnostic tool^[148,149]. The pooled detection rate of CE was 55.9%^[19]. Therefore, In patients with suspected small bowel tumors, CE can be the first choice in diagnostics^[137]. In a study by Schulmann *et al*^[147] it was stated that CE was capable of detecting small bowel polyposis, located in the distal jejunum and ileum beyond the reach of PE. These polyps could subsequently be removed by DBE, so surgery was avoided. However, most FAP patients with distal polyposis also presented with proximal polyposis, which was equally detected by CE as well as PE. Proximal jejunal polyposis is significantly correlated with the presence and severity of duodenal disease, which is one of the main locations for adenocarcinoma and subsequent mortality. Because CE was capable of detecting proximal small bowel polyposis and given its superior sensitivity and non-invasive nature, it was recommended as a surveillance tool in a subgroup of FAP patients with severe duodenal polyposis^[147]. Duodenal polyposis itself is difficult to detect by CE, due to the rapid transit of the capsule in this part of the gastrointestinal tract. Another study by Plum *et al*^[150] confirmed the superiority of CE compared to other modalities such as PE, ileoscopy and enteroclysis in patients with FAP. However, they also stressed on the fact that CE did not replace the other modalities, because CE sometimes missed lesions and did not manage to precisely localize the small bowel lesions. Also a study by Wong *et al*^[151] confirmed the fact that CE could underestimate the number of small bowel polyps in FAP and a review by Koornstra^[152] stated that CE cannot totally replace standard endoscopy in the surveillance of the proximal small bowel. A tool to overcome missed lesions might be the recently developed CICE tool, which enhances the contrast of the CE images and thereby improves the visibility in patients with small bowel polyposis. Although further evaluation is needed, a first trial showed that half of the adenomatous polyps could be better visualized and hamartomatous polyposis was better visible^[153].

In PJS, CE was capable of detecting lesions with direct impact on further management. CE is the most accurate diagnostic tool to detect small bowel polyposis throughout the whole small bowel and can be seen as a safe alternative for the traditional modalities, such as PE and MR enteroclysis used in PJS and FAP^[147].

The superiority of CE over MR enterography was also confirmed by Liao *et al*^[19] who found that CE was capable of detecting smaller small bowel lesions. Urgesi *et al*^[143] stated that CE could detect more lesions than the traditional endoscopy and radiological imaging in patients suspected for small bowel tumors. They concluded that CE played an important role in the diagnostic work-up of these patients^[143]. Similarly another very recent study by Urquhart *et al*^[154] found that CE was able to identify significantly more small bowel polyps compared with MRE in patients with PJS. Furthermore, Rahmi *et al*^[155] found that CE was also useful in planning the DBE approach in patients in need of polypectomy. DBE, which achieves a similar yield as CE, is useful when biopsy, exact pre-operative localization or local therapy, such as stenting or balloon dilatation is needed^[156].

CE also has its limitations in the detection of small bowel tumors. First of all it is not useful in an emergency setting, such as obstruction and peritonitis, because of the risk of capsule retention^[145]. Furthermore, CE is not capable of treating locally or taking biopsies, needed to differentiate between benignant and malignant^[157]. Finally CE is not able to differentiate a mucosal bulge from a smooth-walled tumor. To overcome the latter problem, the scoring system SPICE (Smooth, Protruding lesion Index on CE) has been developed. A score greater than 2 is suggestive of small bowel malignancy, but further validation is needed^[158].

Just like in CD, the risk of capsule retention is present. Yet the rate is lower in patients with intestinal tumors compared to patients with CD^[19]. Moreover, Bailey *et al*^[146] stated that obstructions due to neoplasms were a positive complication because, since the tumor anyway needed to be treated by enteroscopy or surgery, the impacted capsule could serve as a guide. Like in CD, if the patient is suspicious for obstruction, imaging should be done before CE. Management of malignant small bowel tumors is primarily surgical. In selected cases, this can be performed laparoscopically. Adjuvant chemotherapy and radiotherapy may be needed, depending on the histology of the tumor^[155].

We can conclude by stating that CE is a diagnostic tool with a big value regarding its yield in diagnosis and surveillance of small bowel tumors/polyps. However, it is complementary to the traditional modalities and can not substitute them. CE is recommended third after negative bidirectional endoscopy in patients with OGIB or other unspecific symptoms indicating a possible small bowel tumor. It can be used first as a complementary diagnostic tool in patients with established hereditary polyposis syndromes. We summarized the evidence in two flow-charts based on the Consensus statements for small-bowel CE, 2006/2007 by Mergener *et al*^[109] and a study by Plum *et al*^[150] (Figures 5 and 6).

NSAID side-effects

NSAIDs can inflict injury along the whole gastrointestinal tract, when used for a prolonged time. Although many

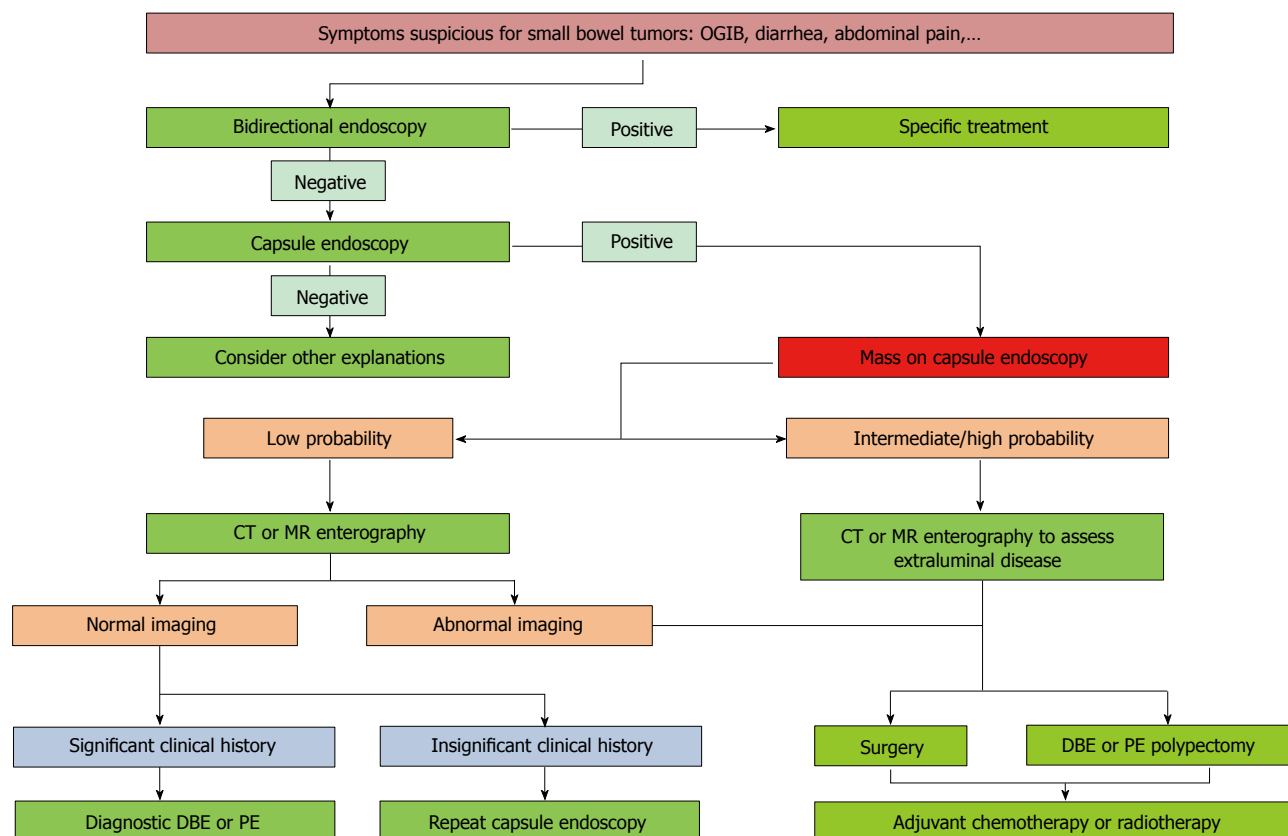


Figure 5 Recommended approaches for diagnosis and treatment of small bowel tumors. DBE: Double balloon enteroscopy; PE: Push enteroscopy; OGIB: Obscure gastrointestinal bleeding.

publications have emphasized on the incidence of upper gastrointestinal lesions, fewer have mentioned lower gastrointestinal ones. However, as mentioned before, NSAIDs can also induce small bowel lesions, which can be observed on CE. In fact, these lesions are far more common than the NSAID-induced gastropathy^[159]. Furthermore, complications in the lower gastrointestinal tract, such as perforation, bleeding, or obstruction are currently increasing while upper GI complications are decreasing^[160], which necessitates the need of small bowel diagnostics in the field of NSAID side-effects.

In seventy percent of the patients using NSAIDs continuously, mucosal damage of the small intestine has been reported on CE or DBE^[161,162]. Even a two-week NSAID-regimen with slow-release diclofenac resulted already in macroscopic injury of the small intestine in 68%-75% of the volunteers^[163]. Different types of lesions have been observed ranging from mucosal redness and multiple petechiae to erosions, ulcers, loss of villi, diaphragm-like strictures, which are pathognomonic for NSAID-induced enteropathy, and even severe bleeding^[164,165]. Most symptomatic patients present with OGIB with or without obstruction symptoms and are accordingly diagnosed^[166,167].

Both CE and DBE have been evaluated for NSAID-induced lesions. They show a similar yield of 60% in diagnosis^[166,168]. CE however is preferred for screening of NSAID-induced lesions and evaluation of further treatment because of its non-invasive character. DBE on

the other hand is the first choice in patients suspicious of strictures. NSAID-use has been recognized as a risk factor for capsule retention and CE should therefore be avoided in these patients^[19]. Furthermore DBE is preferred when further examination of the lesion, endoscopic or histologically, is needed or when local therapy has to be given, such as balloon dilatation of a stricture or endoscopic coagulation, clipping or injection of the bleeding site. Balloon dilatation of a stricture seems to be safe, since the muscularis propria remains intact and perforation is subsequently rarely observed^[156]. A recent study by Tacheci *et al*^[169] confirmed the high sensitivity of CE and further stated that subclinical small bowel damage also could be observed on CE. If NSAID enteropathy is found on CE or DBE, further investigation can be done using other modalities such as radiological examination, the permeability test, scintigraphy, the fecal excretion with ¹¹¹In white blood cells and measurement of the calprotectin concentration in the feces^[164].

Just like in CD, scoring systems are available to classify lesions and to consider and evaluate further treatment^[127,161,163,168]. However, no standard scoring system is thoroughly evaluated. Different therapeutic options are available. The first choice of therapy is a discontinuation in the use of NSAIDs, which in most cases is not possible due to the underlying pathology^[161]. Cyclooxygenase-2 (COX-2) selective inhibitors, prostaglandin derivatives, a combination of NSAIDs and

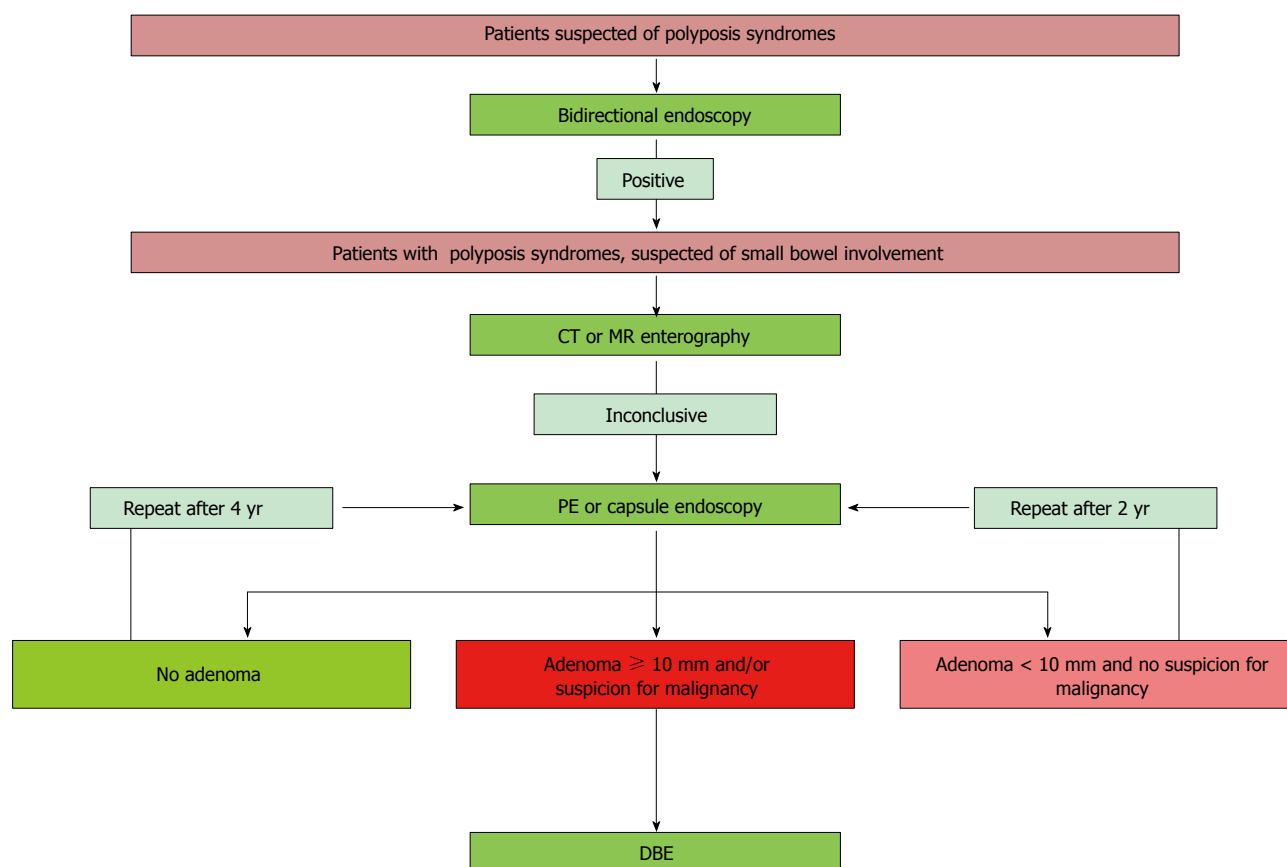


Figure 6 Recommended approaches or diagnosis of small bowel hereditary polyposis. DBE: Double balloon enteroscopy; PE: Push enteroscopy.

phosphatidylcholine, cytoprotective drugs and probiotics are all useful for the treatment of NSAID-induced small intestinal injuries^[159]. Yet controversy remains around the use of selective COX-2 agents. A trial by Goldstein *et al*^[170] reported that a 2-wk regimen of selective COX-2 agents caused fewer small intestine injuries than treatment with a nonspecific NSAID. This was confirmed in a big RCT by Chan *et al*^[171]. However, Maiden *et al*^[172] showed that COX-2 selective inhibitors caused the same amount of small bowel damage as long-term NSAIDs, which is interesting given the fact that they affect the gastroduodenal mucosa to a lesser extent^[170]. So COX-2 might play a significant role in the maintenance of the small bowel integrity. We can conclude that it remains unclear whether selective COX-2 inhibitors truly prevent NSAID-induced enteropathy.

Also chronic Low-dose aspirin (LDA) users are at risk of small bowel enteropathy. The phenomenon was first described by Leung *et al*^[171] in 2007 and the study by Endo *et al*^[165] was the first to report the characteristics of the small bowel damage associated with long-term LDA use. The use of LDA however was less harmful than other types of NSAIDs^[166]. These findings may have implications on treatment of the large group of patients requiring anti-inflammatory or antithrombotic drugs.

Celiac disease

Celiac disease is caused by an chronic auto-immune response of the intestines to gliadins in the diet and

occurs in approximately 1% of the population in genetically susceptible persons^[174]. It is characterized by duodenal folds, scalloping of folds, mucosal fissures, crevices or grooves, visible submucosal vessels, micronodules in the duodenal bulb and a mosaic pattern in the small bowel mucosa^[175]. The lesions are visible on CE, which makes CE therefore a perfect tool to assess small bowel damage in these patients. In a large meta-analysis by Rokkas *et al*^[176] sensitivity and specificity of CE in celiac disease have been reported up to 89% and 95% respectively. This was similar to a previous meta-analysis by El-Matary *et al*^[177] which reported a sensitivity of 83% and a specificity of 98%. However, to confirm celiac disease in patients with positive serologic markers, a biopsy is needed, which is not possible with the current capsules. Therefore, the gold standard for the diagnosis of celiac disease remains the histological findings of a small bowel specimen obtained through gastroduodenoscopy.

The main indications to use CE are serological positive patients, who are unwilling to undergo gastroduodenoscopy or patients with antibody-negative villous atrophy. The latter group showed a higher yield on CE, compared with CE in serological positive patients with biopsy-proven celiac disease and persisting symptoms as was found by Kurien *et al*^[178]. Also in patients with non-responsive celiac disease, defined by persistent or recurrent symptoms under treatment with a gluten-free diet, CE showed to be of use to detect

complications, such as multiple erosions, ulcerations, ulcerative jejunitis and adenocarcinoma^[179]. Tennyson *et al.*^[180] confirmed these findings, but emphasized that CE was not a necessary tool in the evaluation of non-responsive celiac disease when no alarm symptoms are present, such as weight loss and abdominal pain, or when no loss of T-cell antigens on intraepithelial lymphocytes or loss of clonality of the T-cell receptor gene was observed. In the latter situations, a combination of CE and CT or MR enterography should be performed. In all other cases, upper gastroduodenoscopy with biopsy remains the gold standard. A recent study by Van Weyenberg *et al.*^[181] found similar results stating that CE could be used in patients with non-responsive celiac disease to identify the cases who are at risk of complications. CE might also be useful in the follow-up of patients with celiac disease under treatment with a gluten-free diet, regarding mucosal healing, because the follow-up of duodenal histology is not representative for the mucosal healing more distally^[182]. Finally, Akin *et al.*^[183] confirmed other authors by stating that CE was useful as an alternative to duodenal biopsy in patients unable or unwilling to undergo gastroduodenoscopy and further stated that CE could be of use in the diagnosis of celiac disease in elderly patients with unspecific symptoms.

In conclusion, gastroduodenoscopy remains the diagnostic tool of choice for celiac disease, but CE shows to be a useful adjunctive tool in specific situations.

UPCOMING CHALLENGES

To conclude this paper about the current knowledge of CE, we would like to offer an insight in its bright future. Since its release in 2001, optics, battery life, visualization and software have been improved, with consequences on yield, completion rate and reading time. We have already discussed some technological advances in CE, but we will now shortly focus on future expectations of this technology.

One major field of advancement will be the maneuverability. If a capsule endoscope would be steerable and could approach a site of interest, this could be a big step forward in the diagnosis and treatment of diseases of the whole gastrointestinal tract. With efficient movement, battery life could sustain during movement through the whole gastrointestinal tract and thereby could increase completion rate. Various studies have been done and many prototype active capsules, using different locomotion techniques are currently under investigation for human use^[184-188]. However, in the near future, remote manipulation using magnetic forces will be the first to be commercially available. These capsules contain a magnet, which can then be mobilized with an externally handled magnetic paddle or with a joystick. Perspective of the camera also can be adjusted with this magnet, rendering the desired image^[189]. Swain *et al.*^[190] was the first to document the use of a magnetic field to guide a capsule through the human oesophagus and

stomach. Since this article, many studies have followed, especially focusing on investigation of the stomach^[191-194]. To overcome the problem of capsule impaction and to improve mucosal visualization, especially in the colon, insufflation techniques have recently been described by several authors using a capsule with a magnetic controlled drug release system to create a basic chemical reaction forming CO₂ in the lumen^[195-197]. Another very interesting topic is a novel wireless platform able to measure and locate the force opposing capsule motion as a reflection of the gastrointestinal tract resistance^[198]. It is the first platform for magnetic control of CEs that implemented this intermagnetic force measurement feature.

Another advancement might be the availability of a controlled drug release feature. This could help gastroenterologists in the local treatment of various gastrointestinal diseases, such as medical treatment of CD or even hemostasis in OGIB. Only one study introduced a capsule able to microposition a needle and to deliver 1 mL of a targeted medication, while resisting peristalsis with its holding mechanism^[199].

The inability of taking biopsies is a third challenge CE faces. Together with an accurate maneuverability, this could enable CE to completely take the place of DBE in diagnostic and even therapeutic endoscopy of the small bowel. In 2008, Valdastris *et al.*^[200] was the first to successfully report an *in vivo* experiment with a capsule with built-in clip-releasing mechanism. The VECTOR project by the European Commission is currently developing a capsule for diagnosis and treatment of gastrointestinal cancer^[201]. Another study also investigated the use of a large number of thermo-sensitive microgrippers in CE for this purpose of grabbing and retrieving tissue samples, which showed promising results^[202].

Finally, to end this paper, we would like to reflect on the environmental consequences of capsule endoscopies, a subject that will become more important in the future, given the growing importance of CE. Although the ASGE consensus states that the capsule is “disposable and designed to be excreted”^[3], considerations around this topic should be made, since the capsule contains many particles with potential biohazards^[203]. Pezzoli *et al.*^[204] was the first to publish a small article on this matter in 2011. They found that it was possible, after retrieval and cleaning, to reactivate used capsules with a 10 min procedure and a new battery cost of only 2 euro. Recycled capsules could then be given a second life in, *e.g.*, veterinary procedures^[205].

CONCLUSION

This paper gives a brief but complete overview on small bowel CE anno 2014. As the technology is still evolving and new insights are still being published every year, we emphasize that healthcare-providers should continue to monitor the medical literature for recent data, in order to provide the best evidence-based care for their patients.

REFERENCES

- 1 **Iddan G**, Meron G, Glukhovskiy A, Swain P. Wireless capsule endoscopy. *Nature* 2000; **405**: 417 [PMID: 10839527 DOI: 10.1038/35013140]
- 2 **Delvaux M**, Gay G. Capsule endoscopy: technique and indications. *Best Pract Res Clin Gastroenterol* 2008; **22**: 813-837 [PMID: 18790434 DOI: 10.1016/j.bpg.2008.06.003]
- 3 **Wang A**, Banerjee S, Barth BA, Bhat YM, Chauhan S, Gottlieb KT, Konda V, Maple JT, Murad F, Pfau PR, Pleskow DK, Siddiqui UD, Tokar JL, Rodriguez SA. Wireless capsule endoscopy. *Gastrointest Endosc* 2013; **78**: 805-815 [PMID: 24119509 DOI: 10.1016/j.gie.2013.06.026]
- 4 **Pan G**, Wang L. Swallowable wireless capsule endoscopy: progress and technical challenges. *Gastroenterol Res Pract* 2012; **2012**: 841691 [PMID: 22253621 DOI: 10.1155/2012/841691]
- 5 **Metzger YC**, Adler SN, Shitrit ABG, Koslowsky B, Bjarnason I. Comparison of a new PillCam™ SB2 video capsule versus the standard PillCam™ SB for detection of small bowel disease. *Medical Imaging* 2009; **2**: 7-11
- 6 **Liao Z**, Gao R, Li F, Xu C, Zhou Y, Wang JS, Li ZS. Fields of applications, diagnostic yields and findings of OMOM capsule endoscopy in 2400 Chinese patients. *World J Gastroenterol* 2010; **16**: 2669-2676 [PMID: 20518090]
- 7 **Li CY**, Zhang BL, Chen CX, Li YM. OMOM capsule endoscopy in diagnosis of small bowel disease. *J Zhejiang Univ Sci B* 2008; **9**: 857-862 [PMID: 18988304 DOI: 10.1631/jzus.B0820034]
- 8 **Koulaouzidis A**, Rondonotti E, Karagyris A. Small-bowel capsule endoscopy: a ten-point contemporary review. *World J Gastroenterol* 2013; **19**: 3726-3746 [PMID: 23840112 DOI: 10.3748/wjg.v19.i24.3726]
- 9 **Connor A**, Tolan D, Hughes S, Carr N, Tomson C. Consensus guidelines for the safe prescription and administration of oral bowel-cleansing agents. *Gut* 2012; **61**: 1525-1532 [PMID: 22842619 DOI: 10.1136/gutjnl-2011-300861]
- 10 **Kotwal VS**, Attar BM, Gupta S, Agarwal R. Should bowel preparation, antifoaming agents, or prokinetics be used before video capsule endoscopy? A systematic review and meta-analysis. *Eur J Gastroenterol Hepatol* 2014; **26**: 137-145 [PMID: 24220156 DOI: 10.1097/MEG.0b013e328365b9d4]
- 11 **Kantianis A**, Karagiannis S, Liatsos C, Galanis P, Psilopoulos D, Tenta R, Kalantzis N, Mavrogiannis C. Comparison of two schemes of small bowel preparation for capsule endoscopy with polyethylene glycol: a prospective, randomized single-blind study. *Eur J Gastroenterol Hepatol* 2009; **21**: 1140-1144 [PMID: 19757514]
- 12 **Bossa F**, Cocomazzi G, Valvano MR, Andriulli A, Annese V. Detection of abnormal lesions recorded by capsule endoscopy. A prospective study comparing endoscopist's and nurse's accuracy. *Dig Liver Dis* 2006; **38**: 599-602 [PMID: 16750944 DOI: 10.1016/j.dld.2006.03.019]
- 13 **Dokoutsidou H**, Karagiannis S, Giannakouloupoulou E, Galanis P, Kyriakos N, Liatsos C, Faiss S, Mavrogiannis C. A study comparing an endoscopy nurse and an endoscopy physician in capsule endoscopy interpretation. *Eur J Gastroenterol Hepatol* 2011; **23**: 166-170 [PMID: 21287720]
- 14 **Shiotani A**, Honda K, Kawakami M, Kimura Y, Yamanaka Y, Fujita M, Matsumoto H, Tarumi K, Manabe N, Haruma K. Analysis of small-bowel capsule endoscopy reading by using Quickview mode: training assistants for reading may produce a high diagnostic yield and save time for physicians. *J Clin Gastroenterol* 2012; **46**: e92-e95 [PMID: 22495816 DOI: 10.1097/MCG.0b013e31824fff94]
- 15 **Koulaouzidis A**, Smirnidis A, Douglas S, Plevris JN. QuickView in small-bowel capsule endoscopy is useful in certain clinical settings, but QuickView with Blue Mode is of no additional benefit. *Eur J Gastroenterol Hepatol* 2012; **24**: 1099-1104 [PMID: 22668872 DOI: 10.1097/MEG.0b013e32835563ab]
- 16 **Imagawa H**, Oka S, Tanaka S, Noda I, Higashiyama M, Sanomura Y, Shishido T, Yoshida S, Chayama K. Improved detectability of small-bowel lesions via capsule endoscopy with computed virtual chromoendoscopy: a pilot study. *Scand J Gastroenterol* 2011; **46**: 1133-1137 [PMID: 21619482 DOI: 10.3109/00365521.2011.584899]
- 17 **Krystallis C**, Koulaouzidis A, Douglas S, Plevris JN. Chromoendoscopy in small bowel capsule endoscopy: Blue mode or Fuji Intelligent Colour Enhancement? *Dig Liver Dis* 2011; **43**: 953-957 [PMID: 21893436 DOI: 10.1016/j.dld.2011.07.018]
- 18 **Cave D**, Legnani P, de Franchis R, Lewis BS. ICCE consensus for capsule retention. *Endoscopy* 2005; **37**: 1065-1067 [PMID: 16189792 DOI: 10.1055/s-2005-870264]
- 19 **Liao Z**, Gao R, Xu C, Li ZS. Indications and detection, completion, and retention rates of small-bowel capsule endoscopy: a systematic review. *Gastrointest Endosc* 2010; **71**: 280-286 [PMID: 20152309 DOI: 10.1016/j.gie.2009.09.031]
- 20 **Karagiannis S**, Faiss S, Mavrogiannis C. Capsule retention: a feared complication of wireless capsule endoscopy. *Scand J Gastroenterol* 2009; **44**: 1158-1165 [PMID: 19606392 DOI: 10.1080/00365520903132039]
- 21 **Bakhshi GD**, Tayade MB, Jadhav KV, Choure DD, Mane NL, Patil SR. Retention of an endoscopic capsule. *J Minim Access Surg* 2014; **10**: 163-165 [PMID: 25013337 DOI: 10.4103/0972-9941.134886]
- 22 **Höög CM**, Bark LÅ, Arkani J, Gorsetman J, Broström O, Sjöqvist U. Capsule retentions and incomplete capsule endoscopy examinations: an analysis of 2300 examinations. *Gastroenterol Res Pract* 2012; **2012**: 518718 [PMID: 21969823 DOI: 10.1155/2012/518718]
- 23 **Cheifetz AS**, Kornbluth AA, Legnani P, Schmelkin I, Brown A, Lichtiger S, Lewis BS. The risk of retention of the capsule endoscope in patients with known or suspected Crohn's disease. *Am J Gastroenterol* 2006; **101**: 2218-2222 [PMID: 16848804 DOI: 10.1111/j.1572-0241.2006.00761.x]
- 24 **Ladas SD**, Triantafyllou K, Spada C, Riccioni ME, Rey JF, Niv Y, Delvaux M, de Franchis R, Costamagna G. European Society of Gastrointestinal Endoscopy (ESGE): recommendations (2009) on clinical use of video capsule endoscopy to investigate small-bowel, esophageal and colonic diseases. *Endoscopy* 2010; **42**: 220-227 [PMID: 20195992 DOI: 10.1055/s-0029-1243968]
- 25 **Cheifetz AS**, Lewis BS. Capsule endoscopy retention: is it a complication? *J Clin Gastroenterol* 2006; **40**: 688-691 [PMID: 16940879]
- 26 **Roorda AK**, Kupec JT, Ostrinsky Y, Shamma'a JM, Goebel SU, Sundaram U. Endoscopic approach to capsule endoscopy retention. *Expert Rev Gastroenterol Hepatol* 2010; **4**: 713-721 [PMID: 21108591 DOI: 10.1586/egh.10.80]
- 27 **Van Weyenberg SJ**, Van Turenhout ST, Bouma G, Van Waesberghe JH, Van der Peet DL, Mulder CJ, Jacobs MA. Double-balloon endoscopy as the primary method for small-bowel video capsule endoscope retrieval. *Gastrointest Endosc* 2010; **71**: 535-541 [PMID: 20189512 DOI: 10.1016/j.gie.2009.10.029]
- 28 **Repici A**, Barbon V, De Angelis C, Luigiano C, De Caro G, Hervoso C, Danese S, Preatoni P, Pagano N, Comunale S, Pennazio M, Rizzetto M. Acute small-bowel perforation secondary to capsule endoscopy. *Gastrointest Endosc* 2008; **67**: 180-183 [PMID: 17981271 DOI: 10.1016/j.gie.2007.05.044]
- 29 **Parikh DA**, Parikh JA, Albers GC, Chandler CF. Acute small bowel perforation after wireless capsule endoscopy in a patient with Crohn's disease: a case report. *Cases J* 2009; **2**: 7607 [PMID: 19830002 DOI: 10.4076/1757-1626-2-7607]
- 30 **Palmer JS**, Marenah K, El Madani F, Jain K, Gupta S. Small bowel perforation following capsule endoscopy: a case report. *Ann R Coll Surg Engl* 2011; **93**: e69-e70 [PMID: 21929888 DOI: 10.1308/147870811X590829]
- 31 **Um S**, Poblete H, Zavotsky J. Small bowel perforation caused

- by an impacted endocapsule. *Endoscopy* 2008; **40** Suppl 2: E122-E123 [PMID: 18633864 DOI: 10.1055/s-2007-995694]
- 32 **Gonzalez Carro P**, Picazo Yuste J, Fernández Díez S, Pérez Roldán F, Roncero García-Escribano O. Intestinal perforation due to retained wireless capsule endoscope. *Endoscopy* 2005; **37**: 684 [PMID: 16010621 DOI: 10.1055/s-2005-861424]
- 33 **Dubner S**, Dubner Y, Gallino S, Spallone L, Zagalsky D, Rubio H, Zimmerman J, Goldin E. Electromagnetic interference with implantable cardiac pacemakers by video capsule. *Gastrointest Endosc* 2005; **61**: 250-254 [PMID: 15729234]
- 34 **Leighton JA**, Sharma VK, Srivathsan K, Heigh RI, McWane TL, Post JK, Robinson SR, Bazzell JL, Fleischer DE. Safety of capsule endoscopy in patients with pacemakers. *Gastrointest Endosc* 2004; **59**: 567-569 [PMID: 15044901]
- 35 **Daas AY**, Small MB, Pinkas H, Brady PG. Safety of conventional and wireless capsule endoscopy in patients supported with nonpulsatile axial flow Heart-Mate II left ventricular assist device. *Gastrointest Endosc* 2008; **68**: 379-382 [PMID: 18582876 DOI: 10.1016/j.gie.2008.03.1077]
- 36 **Fenkel JM**, Grasso MA, Goldberg EM, Feller ED. Capsule endoscopy is safe in patients with pulsatile Novacor PC left ventricular assist device. *Gastrointest Endosc* 2007; **65**: 559-60; author reply 560 [PMID: 17321277 DOI: 10.1016/j.gie.2006.11.029]
- 37 **Guyomar Y**, Vandeville L, Heuls S, Coviaux F, Graux P, Cornaert P, Filoche B. Interference between pacemaker and video capsule endoscopy. *Pacing Clin Electrophysiol* 2004; **27**: 1329-1330 [PMID: 15461730 DOI: 10.1111/j.1540-8159.2004.00631.x]
- 38 **Payeras G**, Piqueras J, Moreno VJ, Cabrera A, Menéndez D, Jiménez R. Effects of capsule endoscopy on cardiac pacemakers. *Endoscopy* 2005; **37**: 1181-1185 [PMID: 16329014 DOI: 10.1055/s-2005-870558]
- 39 **Stanich PP**, Kleinman B, Betkerur K, Mehta Oza N, Porter K, Meyer MM. Video capsule endoscopy is successful and effective in outpatients with implantable cardiac devices. *Dig Endosc* 2014; **26**: 726-730 [PMID: 24673381 DOI: 10.1111/den.12288]
- 40 **Cuschieri JR**, Osman MN, Wong RC, Chak A, Isenberg GA. Small bowel capsule endoscopy in patients with cardiac pacemakers and implantable cardioverter defibrillators: Outcome analysis using telemetry review. *World J Gastrointest Endosc* 2012; **4**: 87-93 [PMID: 22442746 DOI: 10.4253/wjge.v4.i3.87]
- 41 **Bandorski D**, Jakobs R, Brück M, Hoeltgen R, Wiczorek M, Keuchel M. Capsule Endoscopy in Patients with Cardiac Pacemakers and Implantable Cardioverter Defibrillators: (Re)evaluation of the Current State in Germany, Austria, and Switzerland 2010. *Gastroenterol Res Pract* 2012; **2012**: 717408 [PMID: 22253620 DOI: 10.1155/2012/717408]
- 42 **Dubner S**, Dubner Y, Rubio H, Goldin E. Electromagnetic interference from wireless video-capsule endoscopy on implantable cardioverter-defibrillators. *Pacing Clin Electrophysiol* 2007; **30**: 472-475 [PMID: 17437569 DOI: 10.1111/j.1540-8159.2007.00695.x]
- 43 **Harris LA**, Hansel SL, Rajan E, Srivathsan K, Rea R, Crowell MD, Fleischer DE, Pasha SF, Gurudu SR, Heigh RI, Shiff AD, Post JK, Leighton JA. Capsule Endoscopy in Patients with Implantable Electromedical Devices is Safe. *Gastroenterol Res Pract* 2013; **2013**: 959234 [PMID: 23710168 DOI: 10.1155/2013/959234]
- 44 **Lucendo AJ**, González-Castillo S, Fernández-Fuente M, De Rezende LC. Tracheal aspiration of a capsule endoscope: a new case report and literature compilation of an increasingly reported complication. *Dig Dis Sci* 2011; **56**: 2758-2762 [PMID: 21409372 DOI: 10.1007/s10620-011-1666-2]
- 45 **Pezzoli A**, Fusetti N, Carella A, Gullini S. Asymptomatic bronchial aspiration and prolonged retention of a capsule endoscope: a case report. *J Med Case Rep* 2011; **5**: 341 [PMID: 21810229 DOI: 10.1186/1752-1947-5-341]
- 46 **Ding NS**, Hair C, De Cruz P, Watson J. Education and Imaging. Gastrointestinal: symptomatic bronchial aspiration of capsule endoscope - a significant complication. *J Gastroenterol Hepatol* 2013; **28**: 761 [PMID: 23614341 DOI: 10.1111/jgh.12173]
- 47 **Parker C**, Davison C, Panter S. Tracheal aspiration of a capsule endoscope: not always a benign event. *Dig Dis Sci* 2012; **57**: 1727-1728 [PMID: 22526588 DOI: 10.1007/s10620-012-2173-9]
- 48 **Despott EJ**, O'Rourke A, Anikin V, Davison C, Panter S, Bromley J, Plaice J, Corbett M, Fraser C. Tracheal aspiration of capsule endoscopes: detection, management, and susceptibility. *Dig Dis Sci* 2012; **57**: 1973-1974 [PMID: 22618576 DOI: 10.1007/s10620-012-2144-1]
- 49 **Koulouazidis A**, Douglas S, Plevris JN. Tracheal aspiration of capsule endoscopes: completing a cases compilation. *Dig Dis Sci* 2011; **56**: 3101-3102 [PMID: 21516324 DOI: 10.1007/s10620-011-1704-0]
- 50 **Park SC**, Chun HJ, Kim ES, Keum B, Seo YS, Kim YS, Jeon YT, Lee HS, Um SH, Kim CD, Ryu HS. Sensitivity of the suspected blood indicator: an experimental study. *World J Gastroenterol* 2012; **18**: 4169-4174 [PMID: 22919250 DOI: 10.3748/wjg.v18.i31.4169]
- 51 **Lianguksakul S**, Mays L, Rex DK. Performance of Given suspected blood indicator. *Am J Gastroenterol* 2003; **98**: 2676-2678 [PMID: 14687816 DOI: 10.1111/j.1572-0241.2003.08731.x]
- 52 **Signorelli C**, Villa F, Rondonotti E, Abbiati C, Beccari G, de Franchis R. Sensitivity and specificity of the suspected blood identification system in video capsule enteroscopy. *Endoscopy* 2005; **37**: 1170-1173 [PMID: 16329012 DOI: 10.1055/s-2005-870410]
- 53 **Buscaglia JM**, Giday SA, Kantsevov SV, Clarke JO, Magno P, Yong E, Mullin GE. Performance characteristics of the suspected blood indicator feature in capsule endoscopy according to indication for study. *Clin Gastroenterol Hepatol* 2008; **6**: 298-301 [PMID: 18255353 DOI: 10.1016/j.cgh.2007.12.029]
- 54 **D'Halluin PN**, Delvaux M, Lapalus MG, Sacher-Huvelin S, Ben Soussan E, Heyries L, Filoche B, Saurin JC, Gay G, Heresbach D. Does the "Suspected Blood Indicator" improve the detection of bleeding lesions by capsule endoscopy? *Gastrointest Endosc* 2005; **61**: 243-249 [PMID: 15729233]
- 55 **Tal AO**, Filmann N, Makhlin K, Hausmann J, Friedrich-Rust M, Herrmann E, Zeuzem S, Albert JG. The capsule endoscopy "suspected blood indicator" (SBI) for detection of active small bowel bleeding: no active bleeding in case of negative SBI. *Scand J Gastroenterol* 2014; **49**: 1131-1135 [PMID: 24884306 DOI: 10.3109/00365521.2014.923503]
- 56 **Zhang W**, Han ZL, Cheng Y, Xu YZ, Xiao K, Li AM, Wang YD, Li Y, Liu SD. Value of the patency capsule in pre-evaluation for capsule endoscopy in cases of intestinal obstruction. *J Dig Dis* 2014; **15**: 345-351 [PMID: 24716539 DOI: 10.1111/1751-2980.12152]
- 57 **Lewis BS**. Expanding role of capsule endoscopy in inflammatory bowel disease. *World J Gastroenterol* 2008; **14**: 4137-4141 [PMID: 18636657]
- 58 **Nakamura M**, Hirooka Y, Yamamura T, Miyahara R, Watanabe O, Ando T, Ohmiya N, Goto H. Clinical usefulness of novel tag-less Agile patency capsule prior to capsule endoscopy for patients with suspected small bowel stenosis. *Dig Endosc* 2014; **27**: 61-66 [PMID: 24860910 DOI: 10.1111/den.12306]
- 59 **Spada C**, Shah SK, Riccioni ME, Spera G, Marchese M, Iacopini F, Familiari P, Costamagna G. Video capsule endoscopy in patients with known or suspected small bowel stricture previously tested with the dissolving patency capsule. *J Clin Gastroenterol* 2007; **41**: 576-582 [PMID: 17577114 DOI: 10.1097/01.mcg.0000225633.14663.64]
- 60 **Banerjee R**, Bhargav P, Reddy P, Gupta R, Lakhtakia S,

- Tandan M, Rao VG, Reddy ND. Safety and efficacy of the M2A patency capsule for diagnosis of critical intestinal patency: results of a prospective clinical trial. *J Gastroenterol Hepatol* 2007; **22**: 2060-2063 [PMID: 17614957 DOI: 10.1111/j.1440-1746.2007.05039.x]
- 61 **Herrerias JM**, Leighton JA, Costamagna G, Infantolino A, Eliakim R, Fischer D, Rubin DT, Manten HD, Scapa E, Morgan DR, Bergwerk AJ, Koslowsky B, Adler SN. Agile patency system eliminates risk of capsule retention in patients with known intestinal strictures who undergo capsule endoscopy. *Gastrointest Endosc* 2008; **67**: 902-909 [PMID: 18355824 DOI: 10.1016/j.gie.2007.10.063]
- 62 **Delvaux M**, Ben Soussan E, Laurent V, Lerebours E, Gay G. Clinical evaluation of the use of the M2A patency capsule system before a capsule endoscopy procedure, in patients with known or suspected intestinal stenosis. *Endoscopy* 2005; **37**: 801-807 [PMID: 16116529 DOI: 10.1055/s-2005-870241]
- 63 **Friedrich K**, Gehrke S, Stremmel W, Sieg A. First clinical trial of a newly developed capsule endoscope with panoramic side view for small bowel: a pilot study. *J Gastroenterol Hepatol* 2013; **28**: 1496-1501 [PMID: 23701674 DOI: 10.1111/jgh.12280]
- 64 **Pioche M**, Vanbiervliet G, Jacob P, Duburque C, Gincul R, Filoche B, Daudet J, Filippi J, Saurin JC. Prospective randomized comparison between axial- and lateral-viewing capsule endoscopy systems in patients with obscure digestive bleeding. *Endoscopy* 2014; **46**: 479-484 [PMID: 24285122 DOI: 10.1055/s-0033-1358832]
- 65 **Koulaouzidis A**, Karargyris A. Three-dimensional image reconstruction in capsule endoscopy. *World J Gastroenterol* 2012; **18**: 4086-4090 [PMID: 22919239 DOI: 10.3748/wjg.v18.i31.4086]
- 66 **Koulaouzidis A**, Karargyris A, Rondonotti E, Noble CL, Douglas S, Alexandridis E, Zahid AM, Bathgate AJ, Trimble KC, Plevris JN. Three-dimensional representation software as image enhancement tool in small-bowel capsule endoscopy: a feasibility study. *Dig Liver Dis* 2013; **45**: 909-914 [PMID: 23849802 DOI: 10.1016/j.dld.2013.05.013]
- 67 **Karargyris A**, Rondonotti E, Mandelli G, Koulaouzidis A. Evaluation of 4 three-dimensional representation algorithms in capsule endoscopy images. *World J Gastroenterol* 2013; **19**: 8028-8033 [PMID: 24307796 DOI: 10.3748/wjg.v19.i44.8028]
- 68 **Than TD**, Alici G, Zhou H, Li W. A review of localization systems for robotic endoscopic capsules. *IEEE Trans Biomed Eng* 2012; **59**: 2387-2399 [PMID: 22736628 DOI: 10.1109/TBME.2012.2201715]
- 69 **Marya N**, Karellas A, Foley A, Roychowdhury A, Cave D. Computerized 3-dimensional localization of a video capsule in the abdominal cavity: validation by digital radiography. *Gastrointest Endosc* 2014; **79**: 669-674 [PMID: 24424401 DOI: 10.1016/j.gie.2013.11.022]
- 70 **Karargyris A**, Koulaouzidis A. Capsule-odometer: a concept to improve accurate lesion localisation. *World J Gastroenterol* 2013; **19**: 5943-5946 [PMID: 24124345 DOI: 10.3748/wjg.v19.i35.5943]
- 71 **Raju GS**, Gerson L, Das A, Lewis B. American Gastroenterological Association (AGA) Institute technical review on obscure gastrointestinal bleeding. *Gastroenterology* 2007; **133**: 1697-1717 [PMID: 17983812 DOI: 10.1053/j.gastro.2007.06.007]
- 72 **Westerhof J**, Weersma RK, Koornstra JJ. Investigating obscure gastrointestinal bleeding: capsule endoscopy or double balloon enteroscopy? *Neth J Med* 2009; **67**: 260-265 [PMID: 19687519]
- 73 **Gilbert D**, O'Malley S, Selby W. Are repeat upper gastrointestinal endoscopy and colonoscopy necessary within six months of capsule endoscopy in patients with obscure gastrointestinal bleeding? *J Gastroenterol Hepatol* 2008; **23**: 1806-1809 [PMID: 19032448 DOI: 10.1111/j.1440-1746.2008.05643.x]
- 74 **Sidhu PS**, McAlindon ME, Drew K, Sidhu R. Diagnostic yield of small-bowel capsule endoscopy in patients with iron deficiency anemia: does it affect management? *Gastrointest Endosc* 2013; **78**: 800-801 [PMID: 24120341 DOI: 10.1016/j.gie.2013.06.022]
- 75 **Albert JG**, Schölbe R, Hahn L, Heinig D, Schoppmeyer K, Porst H, Lorenz R, Plauth M, Dollinger MM, Mössner J, Caca K, Fleig WE. Impact of capsule endoscopy on outcome in mid-intestinal bleeding: a multicentre cohort study in 285 patients. *Eur J Gastroenterol Hepatol* 2008; **20**: 971-977 [PMID: 18787463 DOI: 10.1097/MEG.0b013e3282fb2a53]
- 76 **Arakawa D**, Ohmiya N, Nakamura M, Honda W, Shirai O, Itoh A, Hirooka Y, Niwa Y, Maeda O, Ando T, Goto H. Outcome after enteroscopy for patients with obscure GI bleeding: diagnostic comparison between double-balloon endoscopy and videocapsule endoscopy. *Gastrointest Endosc* 2009; **69**: 866-874 [PMID: 19136098 DOI: 10.1016/j.gie.2008.06.008]
- 77 **Teshima CW**, Kuipers EJ, van Zanten SV, Mensink PB. Double balloon enteroscopy and capsule endoscopy for obscure gastrointestinal bleeding: an updated meta-analysis. *J Gastroenterol Hepatol* 2011; **26**: 796-801 [PMID: 21155884 DOI: 10.1111/j.1440-1746.2010.06530.x]
- 78 **Calabrese C**, Liguori G, Gionchetti P, Rizzello F, Laureti S, Di Simone MP, Poggioli G, Campieri M. Obscure gastrointestinal bleeding: single centre experience of capsule endoscopy. *Intern Emerg Med* 2013; **8**: 681-687 [PMID: 21959901 DOI: 10.1007/s11739-011-0699-z]
- 79 **Neu B**, Ell C, May A, Schmid E, Riemann JF, Hagenmüller F, Keuchel M, Soehendra N, Seitz U, Meining A, Rösch T. Capsule endoscopy versus standard tests in influencing management of obscure digestive bleeding: results from a German multicenter trial. *Am J Gastroenterol* 2005; **100**: 1736-1742 [PMID: 16086709 DOI: 10.1111/j.1572-0241.2005.41649.x]
- 80 **Triester SL**, Leighton JA, Leontiadis GI, Fleischer DE, Hara AK, Heigh RI, Shiff AD, Sharma VK. A meta-analysis of the yield of capsule endoscopy compared to other diagnostic modalities in patients with obscure gastrointestinal bleeding. *Am J Gastroenterol* 2005; **100**: 2407-2418 [PMID: 16279893 DOI: 10.1111/j.1572-0241.2005.00274.x]
- 81 **Triester SL**, Leighton JA, Leontiadis GI, Gurudu SR, Fleischer DE, Hara AK, Heigh RI, Shiff AD, Sharma VK. A meta-analysis of the yield of capsule endoscopy compared to other diagnostic modalities in patients with non-stricturing small bowel Crohn's disease. *Am J Gastroenterol* 2006; **101**: 954-964 [PMID: 16696781 DOI: 10.1111/j.1572-0241.2006.00506.x]
- 82 **Leighton JA**, Triester SL, Sharma VK. Capsule endoscopy: a meta-analysis for use with obscure gastrointestinal bleeding and Crohn's disease. *Gastrointest Endosc Clin N Am* 2006; **16**: 229-250 [PMID: 16644453 DOI: 10.1016/j.giec.2006.03.004]
- 83 **Pennazio M**, Santucci R, Rondonotti E, Abbiati C, Beccari G, Rossini FP, De Franchis R. Outcome of patients with obscure gastrointestinal bleeding after capsule endoscopy: report of 100 consecutive cases. *Gastroenterology* 2004; **126**: 643-653 [PMID: 14988816]
- 84 **Sidhu R**, Sanders DS, Kapur K, Leeds JS, McAlindon ME. Factors predicting the diagnostic yield and intervention in obscure gastrointestinal bleeding investigated using capsule endoscopy. *J Gastrointest Liver Dis* 2009; **18**: 273-278 [PMID: 19795019]
- 85 **Sidhu R**, Sanders DS, Sakellariou VP, McAlindon ME. Capsule endoscopy and obscure gastrointestinal bleeding: are transfusion dependence and comorbidity further risk factors to predict a diagnosis? *Am J Gastroenterol* 2007; **102**: 1329-1330 [PMID: 17531021 DOI: 10.1111/j.1572-0241.2007.01171.x]
- 86 **Singh A**, Marshall C, Chaudhuri B, Okoli C, Foley A, Person SD, Bhattacharya K, Cave DR. Timing of video capsule

- endoscopy relative to overt obscure GI bleeding: implications from a retrospective study. *Gastrointest Endosc* 2013; **77**: 761-766 [PMID: 23375526 DOI: 10.1016/j.gie.2012.11.041]
- 87 **Yamada A**, Watabe H, Kobayashi Y, Yamaji Y, Yoshida H, Koike K. Timing of capsule endoscopy influences the diagnosis and outcome in obscure-overt gastrointestinal bleeding. *Hepatogastroenterology* 2012; **59**: 676-679 [PMID: 22469708 DOI: 10.5754/hge12180]
- 88 **May A**, Wardak A, Nachbar L, Remke S, Ell C. Influence of patient selection on the outcome of capsule endoscopy in patients with chronic gastrointestinal bleeding. *J Clin Gastroenterol* 2005; **39**: 684-688 [PMID: 16082277]
- 89 **Leighton JA**, Sharma VK, Hentz JG, Musil D, Malikowski MJ, McWane TL, Fleischer DE. Capsule endoscopy versus push enteroscopy for evaluation of obscure gastrointestinal bleeding with 1-year outcomes. *Dig Dis Sci* 2006; **51**: 891-899 [PMID: 16758305 DOI: 10.1007/s10620-006-9350-7]
- 90 **Mylonaki M**, Fritscher-Ravens A, Swain P. Wireless capsule endoscopy: a comparison with push enteroscopy in patients with gastroscopy and colonoscopy negative gastrointestinal bleeding. *Gut* 2003; **52**: 1122-1126 [PMID: 12865269]
- 91 **Holleran GE**, Barry SA, Thornton OJ, Dobson MJ, McNamara DA. The use of small bowel capsule endoscopy in iron deficiency anaemia: low impact on outcome in the medium term despite high diagnostic yield. *Eur J Gastroenterol Hepatol* 2013; **25**: 327-332 [PMID: 23183118 DOI: 10.1097/MEG.0b013e32835b7d3a]
- 92 **Holleran G**, Hall B, Alhinai M, Zaheer A, Leen R, Alakkari A, Mahmud N, McNamara D. Double-balloon enteroscopy in Ireland in the capsule endoscopy era. *Ir J Med Sci* 2014; Epub ahead of print [PMID: 24633527 DOI: 10.1007/s11845-014-1097-0]
- 93 **Albert JG**, Nachtigall F, Wiedbrauck F, Dollinger MM, Gittinger FS, Hollerbach S, Wienke A. Minimizing procedural cost in diagnosing small bowel bleeding: comparison of a strategy based on initial capsule endoscopy versus initial double-balloon enteroscopy. *Eur J Gastroenterol Hepatol* 2010; **22**: 679-688 [PMID: 20446352]
- 94 **Nakamura M**, Niwa Y, Ohmiya N, Miyahara R, Ohashi A, Itoh A, Hirooka Y, Goto H. Preliminary comparison of capsule endoscopy and double-balloon enteroscopy in patients with suspected small-bowel bleeding. *Endoscopy* 2006; **38**: 59-66 [PMID: 16429356 DOI: 10.1055/s-2005-870446]
- 95 **Pasha SF**, Leighton JA, Das A, Harrison ME, Decker GA, Fleischer DE, Sharma VK. Double-balloon enteroscopy and capsule endoscopy have comparable diagnostic yield in small-bowel disease: a meta-analysis. *Clin Gastroenterol Hepatol* 2008; **6**: 671-676 [PMID: 18356113 DOI: 10.1016/j.cgh.2008.01.005]
- 96 **Mensink PB**, Haringsma J, Kucharzik T, Cellier C, Pérez-Cuadrado E, Mönkemüller K, Gasbarrini A, Kaffes AJ, Nakamura K, Yen HH, Yamamoto H. Complications of double balloon enteroscopy: a multicenter survey. *Endoscopy* 2007; **39**: 613-615 [PMID: 17516287 DOI: 10.1055/s-2007-966444]
- 97 **Matsumura T**, Arai M, Saito K, Okimoto K, Saito M, Minemura S, Oyamada A, Maruoka D, Nakagawa T, Watabe H, Katsuno T, Yokosuka O. Predictive factor of re-bleeding after negative capsule endoscopy for obscure gastrointestinal bleeding: over 1-year follow-up study. *Dig Endosc* 2014; **26**: 650-658 [PMID: 24628735 DOI: 10.1111/den.12257]
- 98 **Somsouk M**, Gralnek IM, Inadomi JM. Management of obscure occult gastrointestinal bleeding: a cost-minimization analysis. *Clin Gastroenterol Hepatol* 2008; **6**: 661-670 [PMID: 18550005 DOI: 10.1016/j.cgh.2008.02.033]
- 99 **Marmo R**, Rotondano G, Rondonotti E, de Franchis R, D'Inà R, Vettorato MG, Costamagna G, Riccioni ME, Spada C, D'Angella R, Milazzo G, Faraone A, Rizzetto M, Barbon V, Occhipinti P, Saettone S, Iaquinio G, Rossini FP. Capsule enteroscopy vs. other diagnostic procedures in diagnosing obscure gastrointestinal bleeding: a cost-effectiveness study. *Eur J Gastroenterol Hepatol* 2007; **19**: 535-542 [PMID: 17556898 DOI: 10.1097/MEG.0b013e32812144dd]
- 100 **Gerson L**, Kamal A. Cost-effectiveness analysis of management strategies for obscure GI bleeding. *Gastrointest Endosc* 2008; **68**: 920-936 [PMID: 18407270 DOI: 10.1016/j.gie.2008.01.035]
- 101 **Lai LH**, Wong GL, Chow DK, Lau JY, Sung JJ, Leung WK. Long-term follow-up of patients with obscure gastrointestinal bleeding after negative capsule endoscopy. *Am J Gastroenterol* 2006; **101**: 1224-1228 [PMID: 16771942 DOI: 10.1111/j.1572-0241.2006.00565.x]
- 102 **Riccioni ME**, Urgesi R, Cianci R, Rizzo G, D'Angelo L, Marmo R, Costamagna G. Negative capsule endoscopy in patients with obscure gastrointestinal bleeding reliable: recurrence of bleeding on long-term follow-up. *World J Gastroenterol* 2013; **19**: 4520-4525 [PMID: 23901227 DOI: 10.3748/wjg.v19.i28.4520]
- 103 **Macdonald J**, Porter V, McNamara D. Negative capsule endoscopy in patients with obscure GI bleeding predicts low rebleeding rates. *Gastrointest Endosc* 2008; **68**: 1122-1127 [PMID: 19028220 DOI: 10.1016/j.gie.2008.06.054]
- 104 **Koh SJ**, Im JP, Kim JW, Kim BG, Lee KL, Kim SG, Kim JS, Jung HC. Long-term outcome in patients with obscure gastrointestinal bleeding after negative capsule endoscopy. *World J Gastroenterol* 2013; **19**: 1632-1638 [PMID: 23539070 DOI: 10.3748/wjg.v19.i10.1632]
- 105 **Park JJ**, Cheon JH, Kim HM, Park HS, Moon CM, Lee JH, Hong SP, Kim TI, Kim WH. Negative capsule endoscopy without subsequent enteroscopy does not predict lower long-term rebleeding rates in patients with obscure GI bleeding. *Gastrointest Endosc* 2010; **71**: 990-997 [PMID: 20304392 DOI: 10.1016/j.gie.2009.12.009]
- 106 **Viazis N**, Papaxoinis K, Vlachogiannakos J, Efthymiou A, Theodoropoulos I, Karamanolis DG. Is there a role for second-look capsule endoscopy in patients with obscure GI bleeding after a nondiagnostic first test? *Gastrointest Endosc* 2009; **69**: 850-856 [PMID: 18950762 DOI: 10.1016/j.gie.2008.05.053]
- 107 **Jones BH**, Fleischer DE, Sharma VK, Heigh RI, Shiff AD, Hernandez JL, Leighton JA. Yield of repeat wireless video capsule endoscopy in patients with obscure gastrointestinal bleeding. *Am J Gastroenterol* 2005; **100**: 1058-1064 [PMID: 15842579 DOI: 10.1111/j.1572-0241.2005.40722.x]
- 108 **Svarta S**, Segal B, Law J, Sandhar A, Kwok R, Jacques A, Lakzadeh P, Enns R. Diagnostic yield of repeat capsule endoscopy and the effect on subsequent patient management. *Can J Gastroenterol* 2010; **24**: 441-444 [PMID: 20652160]
- 109 **Mergener K**, Ponchon T, Gralnek I, Pennazio M, Gay G, Selby W, Seidman EG, Cellier C, Murray J, de Franchis R, Rösch T, Lewis BS. Literature review and recommendations for clinical application of small-bowel capsule endoscopy, based on a panel discussion by international experts. Consensus statements for small-bowel capsule endoscopy, 2006/2007. *Endoscopy* 2007; **39**: 895-909 [PMID: 17968807 DOI: 10.1055/s-2007-966930]
- 110 **Niv Y**. Capsule endoscopy in the diagnosis of Crohn's disease. *Med Devices (Auckl)* 2013; **6**: 85-89 [PMID: 23818810 DOI: 10.2147/MDER.S38728]
- 111 **Bourreille A**, Ignjatovic A, Aabakken L, Loftus EV, Eliakim R, Pennazio M, Bouhnik Y, Seidman E, Keuchel M, Albert JG, Ardizzone S, Bar-Meir S, Bisschops R, Despott EJ, Fortun PF, Heuschkel R, Kammermeier J, Leighton JA, Mantzaris GJ, Moussata D, Lo S, Paulsen V, Panés J, Radford-Smith G, Reinisch W, Rondonotti E, Sanders DS, Swoger JM, Yamamoto H, Travis S, Colombel JF, Van Gossum A. Role of small-bowel endoscopy in the management of patients with inflammatory bowel disease: an international OMED-ECCO consensus. *Endoscopy* 2009; **41**: 618-637 [PMID: 19588292]

DOI: 10.1055/s-0029-1214790]

- 112 **Lucendo AJ**, Guagnozzi D. Small bowel video capsule endoscopy in Crohn's disease: What have we learned in the last ten years? *World J Gastrointest Endosc* 2011; **3**: 23-29 [PMID: 21403813 DOI: 10.4253/wjge.v3.i2.23]
- 113 **Mow WS**, Lo SK, Targan SR, Dubinsky MC, Treyzon L, Abreu-Martin MT, Papadakis KA, Vasilias EA. Initial experience with wireless capsule enteroscopy in the diagnosis and management of inflammatory bowel disease. *Clin Gastroenterol Hepatol* 2004; **2**: 31-40 [PMID: 15017630]
- 114 **Fidder HH**, Nadler M, Lahat A, Lahav M, Bardan E, Avidan B, Bar-Meir S. The utility of capsule endoscopy in the diagnosis of Crohn's disease based on patient's symptoms. *J Clin Gastroenterol* 2007; **41**: 384-387 [PMID: 17413607 DOI: 10.1097/01.mcg.0000225621.02094.8a]
- 115 **Dionisio PM**, Gurudu SR, Leighton JA, Leontiadis GI, Fleischer DE, Hara AK, Heigh RI, Shiff AD, Sharma VK. Capsule endoscopy has a significantly higher diagnostic yield in patients with suspected and established small-bowel Crohn's disease: a meta-analysis. *Am J Gastroenterol* 2010; **105**: 1240-1248; quiz 1249 [PMID: 20029412 DOI: 10.1038/ajg.2009.713]
- 116 **Lu XH**, Qin MW, Wen XH, Liu W, Shi JH, Qian JM, Li JN. [The diagnosis of Crohn's disease of the small bowel: comparing CT enterography, capsule endoscopy, small-bowel follow through and ileocolonoscopy]. *Zhonghua Nei Ke Zazhi* 2010; **49**: 746-749 [PMID: 21092443]
- 117 **Marmo R**, Rotondano G, Piscopo R, Bianco MA, Siani A, Catalano O, Cipolletta L. Capsule endoscopy versus enteroclysis in the detection of small-bowel involvement in Crohn's disease: a prospective trial. *Clin Gastroenterol Hepatol* 2005; **3**: 772-776 [PMID: 16234005]
- 118 **Solem CA**, Loftus EV, Fletcher JG, Baron TH, Gostout CJ, Petersen BT, Tremaine WJ, Egan LJ, Faubion WA, Schroeder KW, Pardi DS, Hanson KA, Jewell DA, Barlow JM, Fidler JL, Huprich JE, Johnson CD, Harmsen WS, Zinsmeister AR, Sandborn WJ. Small-bowel imaging in Crohn's disease: a prospective, blinded, 4-way comparison trial. *Gastrointest Endosc* 2008; **68**: 255-266 [PMID: 18513722 DOI: 10.1016/j.gie.2008.02.017]
- 119 **Girelli CM**, Porta P, Malacrida V, Barzaghi F, Rocca F. Clinical outcome of patients examined by capsule endoscopy for suspected small bowel Crohn's disease. *Dig Liver Dis* 2007; **39**: 148-154 [PMID: 17196893 DOI: 10.1016/j.dld.2006.10.018]
- 120 **Gölder SK**, Schreyer AG, Endlicher E, Feuerbach S, Schölmerich J, Kullmann F, Seitz J, Rogler G, Herfarth H. Comparison of capsule endoscopy and magnetic resonance (MR) enteroclysis in suspected small bowel disease. *Int J Colorectal Dis* 2006; **21**: 97-104 [PMID: 15846497 DOI: 10.1007/s00384-005-0755-0]
- 121 **Voderholzer WA**, Beinhöelzl J, Rogalla P, Murrer S, Schachschal G, Lochs H, Ortner MA. Small bowel involvement in Crohn's disease: a prospective comparison of wireless capsule endoscopy and computed tomography enteroclysis. *Gut* 2005; **54**: 369-373 [PMID: 15710985 DOI: 10.1136/gut.2004.040055]
- 122 **Crook DW**, Knuesel PR, Froehlich JM, Eigenmann F, Unterwieser M, Beer HJ, Kubik-Huch RA. Comparison of magnetic resonance enterography and video capsule endoscopy in evaluating small bowel disease. *Eur J Gastroenterol Hepatol* 2009; **21**: 54-65 [PMID: 19086147]
- 123 **Leighton JA**, Gralnek IM, Cohen SA, Toth E, Cave DR, Wolf DC, Mullin GE, Ketover SR, Legnani PE, Seidman EG, Crowell MD, Bergwerk AJ, Peled R, Eliakim R. Capsule endoscopy is superior to small-bowel follow-through and equivalent to ileocolonoscopy in suspected Crohn's disease. *Clin Gastroenterol Hepatol* 2014; **12**: 609-615 [PMID: 24075891 DOI: 10.1016/j.cgh.2013.09.028]
- 124 **D'Incà R**, Caccaro R. Measuring disease activity in Crohn's disease: what is currently available to the clinician. *Clin Exp Gastroenterol* 2014; **7**: 151-161 [PMID: 24876789 DOI: 10.2147/CEG.S41413]
- 125 **Lang J**, Price AB, Levi AJ, Burke M, Gumpel JM, Bjarnason I. Diaphragm disease: pathology of disease of the small intestine induced by non-steroidal anti-inflammatory drugs. *J Clin Pathol* 1988; **41**: 516-526 [PMID: 3384981]
- 126 **Doherty GA**, Moss AC, Cheifetz AS. Capsule endoscopy in suspected Crohn's disease: "yield" does not equal "diagnosis". *Am J Gastroenterol* 2010; **105**: 2111; author reply 2111-2112 [PMID: 20818355 DOI: 10.1038/ajg.2010.203]
- 127 **Gralnek IM**, Defranchis R, Seidman E, Leighton JA, Legnani P, Lewis BS. Development of a capsule endoscopy scoring index for small bowel mucosal inflammatory change. *Aliment Pharmacol Ther* 2008; **27**: 146-154 [PMID: 17956598 DOI: 10.1111/j.1365-2036.2007.03556.x]
- 128 **Niv Y**, Ilani S, Levi Z, Herschkowitz M, Niv E, Fireman Z, O'Donnel S, O'Morain C, Eliakim R, Scapa E, Kalantzis N, Kalantzis C, Apostolopoulos P, Gal E. Validation of the Capsule Endoscopy Crohn's Disease Activity Index (CECDI or Niv score): a multicenter prospective study. *Endoscopy* 2012; **44**: 21-26 [PMID: 22125196 DOI: 10.1055/s-0031-1291385]
- 129 **Hall B**, Holleran G, Costigan D, McNamara D. Capsule endoscopy: High negative predictive value in the long term despite a low diagnostic yield in patients with suspected Crohn's disease. *United European Gastroenterol J* 2013; **1**: 461-466 [PMID: 24917998 DOI: 10.1177/2050640613508551]
- 130 **Sharaf RN**, Levesque BG, Shah S, Longacre T, Pasricha PJ. Capsule endoscopy in the diagnosis of suspected small bowel involvement with Crohn's disease. *Dig Dis Sci* 2011; **56**: 46-48 [PMID: 20668937 DOI: 10.1007/s10620-010-1355-6]
- 131 **Kornbluth A**, Colombel JF, Leighton JA, Loftus E. ICCE consensus for inflammatory bowel disease. *Endoscopy* 2005; **37**: 1051-1054 [PMID: 16189789 DOI: 10.1055/s-2005-870315]
- 132 **Caunedo-Alvarez A**, Romero-Vazquez J, Herreras-Gutierrez JM. Patency and Agile capsules. *World J Gastroenterol* 2008; **14**: 5269-5273 [PMID: 18785278]
- 133 **Levesque BG**, Cipriano LE, Chang SL, Lee KK, Owens DK, Garber AM. Cost effectiveness of alternative imaging strategies for the diagnosis of small-bowel Crohn's disease. *Clin Gastroenterol Hepatol* 2010; **8**: 261-267, 261-267 [PMID: 19896559 DOI: 10.1016/j.cgh.2009.10.032]
- 134 **Leighton JA**, Gralnek IM, Richner RE, Lacey MJ, Papatheofanis FJ. Capsule endoscopy in suspected small bowel Crohn's disease: economic impact of disease diagnosis and treatment. *World J Gastroenterol* 2009; **15**: 5685-5692 [PMID: 19960565]
- 135 **Abu-Hamda EM**, Hattab EM, Lynch PM. Small bowel tumors. *Curr Gastroenterol Rep* 2003; **5**: 386-393 [PMID: 12959719]
- 136 **Williamson JM**, Williamson RC. Small bowel tumors: pathology and management. *J Med Assoc Thai* 2014; **97**: 126-137 [PMID: 24701741]
- 137 **Singeap AM**, Trifan A, Cojocariu C, Sfarti C, Stanciu C. [Capsule endoscopy role in diagnosis of small bowel tumors]. *Rev Med Chir Soc Med Nat Iasi* 2010; **114**: 988-992 [PMID: 21500447]
- 138 **Talamonti MS**, Goetz LH, Rao S, Joehl RJ. Primary cancers of the small bowel: analysis of prognostic factors and results of surgical management. *Arch Surg* 2002; **137**: 564-70; discussion 570-1 [PMID: 11982470]
- 139 **Goenka MK**, Majumder S, Goenka U. Capsule endoscopy: Present status and future expectation. *World J Gastroenterol* 2014; **20**: 10024-10037 [PMID: 25110430 DOI: 10.3748/wjg.v20.i29.10024]
- 140 **Rondonotti E**, Pennazio M, Toth E, Menchen P, Riccioni ME, De Palma GD, Scotto F, De Looze D, Pachofsky T, Tacheci I, Havelund T, Couto G, Trifan A, Kokofotsios A, Cannizzaro R, Perez-Quadrado E, de Franchis R. Small-bowel neoplasms in

- patients undergoing video capsule endoscopy: a multicenter European study. *Endoscopy* 2008; **40**: 488-495 [PMID: 18464193 DOI: 10.1055/s-2007-995783]
- 141 **Chen WG**, Shan GD, Zhang H, Li L, Yue M, Xiang Z, Cheng Y, Wu CJ, Fang Y, Chen LH. Double-balloon enteroscopy in small bowel tumors: a Chinese single-center study. *World J Gastroenterol* 2013; **19**: 3665-3671 [PMID: 23801870 DOI: 10.3748/wjg.v19.i23.3665]
- 142 **Minardi AJ**, Zibari GB, Aultman DF, McMillan RW, McDonald JC. Small-bowel tumors. *J Am Coll Surg* 1998; **186**: 664-668 [PMID: 9632155]
- 143 **Urgesi R**, Riccioni ME, Bizzotto A, Cianci R, Spada C, Pelecca G, Ricci R, Costamagna G. Increased diagnostic yield of small bowel tumors with PillCam: the role of capsule endoscopy in the diagnosis and treatment of gastrointestinal stromal tumors (GISTs). Italian single-center experience. *Tumori* 2012; **98**: 357-363 [PMID: 22825512 DOI: 10.1700/1125.12405]
- 144 **Leighton JA**. The role of endoscopic imaging of the small bowel in clinical practice. *Am J Gastroenterol* 2011; **106**: 27-36; quiz 37 [PMID: 20978483 DOI: 10.1038/ajg.2010.410]
- 145 **Tărcoveanu E**, Georgescu S, Vasilescu A, Dănilă N, Lupașcu C, Dimofte G, Neacșu CN, Moldovanu R. [Small bowel tumours from barium meal to capsule endoscopy and from open to laparoscopic approach]. *Chirurgia (Bucur)* 2011; **106**: 451-464 [PMID: 21991870]
- 146 **Bailey AA**, Debinski HS, Appleyard MN, Remedios ML, Hooper JE, Walsh AJ, Selby WS. Diagnosis and outcome of small bowel tumors found by capsule endoscopy: a three-center Australian experience. *Am J Gastroenterol* 2006; **101**: 2237-2243 [PMID: 17032187 DOI: 10.1111/j.1572-0241.2006.00749.x]
- 147 **Schulmann K**, Hollerbach S, Kraus K, Willert J, Vogel T, Möslein G, Pox C, Reiser M, Reinacher-Schick A, Schmiegel W. Feasibility and diagnostic utility of video capsule endoscopy for the detection of small bowel polyps in patients with hereditary polyposis syndromes. *Am J Gastroenterol* 2005; **100**: 27-37 [PMID: 15654777 DOI: 10.1111/j.1572-0241.2005.40102.x]
- 148 **Burke CA**, Santisi J, Church J, Levinthal G. The utility of capsule endoscopy small bowel surveillance in patients with polyposis. *Am J Gastroenterol* 2005; **100**: 1498-1502 [PMID: 15984971 DOI: 10.1111/j.1572-0241.2005.41506.x]
- 149 **Günther U**, Bojarski C, Buhr HJ, Zeitz M, Heller F. Capsule endoscopy in small-bowel surveillance of patients with hereditary polyposis syndromes. *Int J Colorectal Dis* 2010; **25**: 1377-1382 [PMID: 20544205 DOI: 10.1007/s00384-010-0982-x]
- 150 **Plum N**, May A, Manner H, Ell C. Small-bowel diagnosis in patients with familial adenomatous polyposis: comparison of push enteroscopy, capsule endoscopy, ileoscopy, and enteroclysis. *Z Gastroenterol* 2009; **47**: 339-346 [PMID: 19358059 DOI: 10.1055/s-2008-1027984]
- 151 **Wong RF**, Tuteja AK, Haslem DS, Pappas L, Szabo A, Ogara MM, DiSario JA. Video capsule endoscopy compared with standard endoscopy for the evaluation of small-bowel polyps in persons with familial adenomatous polyposis (with video). *Gastrointest Endosc* 2006; **64**: 530-537 [PMID: 16996344 DOI: 10.1016/j.gie.2005.12.014]
- 152 **Koornstra JJ**. Small bowel endoscopy in familial adenomatous polyposis and Lynch syndrome. *Best Pract Res Clin Gastroenterol* 2012; **26**: 359-368 [PMID: 22704577 DOI: 10.1016/j.bpg.2012.01.022]
- 153 **Hatogai K**, Hosoe N, Imaeda H, Rey JF, Okada S, Ishibashi Y, Kimura K, Yoneno K, Usui S, Ida Y, Tsukada N, Kanai T, Hibi T, Ogata H. Role of enhanced visibility in evaluating polyposis syndromes using a newly developed contrast image capsule endoscope. *Gut Liver* 2012; **6**: 218-222 [PMID: 22570751 DOI: 10.5009/gnl.2012.6.2.218]
- 154 **Urquhart P**, Grimpén F, Lim GJ, Pizzey C, Stella DL, Tesar PA, Macrae FA, Appleyard MA, Brown GJ. Capsule endoscopy versus magnetic resonance enterography for the detection of small bowel polyps in Peutz-Jeghers syndrome. *Fam Cancer* 2014; **13**: 249-255 [PMID: 24509884 DOI: 10.1007/s10689-014-9700-0]
- 155 **Rahmi G**, Samaha E, Lorenceau-Savale C, Landi B, Edery J, Manière T, Canard JM, Malamut G, Chatellier G, Cellier C. Small bowel polypectomy by double balloon enteroscopy: Correlation with prior capsule endoscopy. *World J Gastrointest Endosc* 2013; **5**: 219-225 [PMID: 23678374 DOI: 10.4253/wjge.v5.i5.219]
- 156 **Hale MF**, Sidhu R, McAlindon ME. Capsule endoscopy: current practice and future directions. *World J Gastroenterol* 2014; **20**: 7752-7759 [PMID: 24976712 DOI: 10.3748/wjg.v20.i24.7752]
- 157 **Urbain D**, Van Laer W, Mana F. Capsule endoscopy for detection of small bowel malignancies. *Surg Technol Int* 2008; **17**: 126-130 [PMID: 18802892]
- 158 **Girelli CM**, Porta P, Colombo E, Lesinigo E, Bernasconi G. Development of a novel index to discriminate bulge from mass on small-bowel capsule endoscopy. *Gastrointest Endosc* 2011; **74**: 1067-1074; quiz 1067-1074 [PMID: 21907982 DOI: 10.1016/j.gie.2011.07.022]
- 159 **Lim YJ**, Chun HJ. Recent Advances in NSAIDs-Induced Enteropathy Therapeutics: New Options, New Challenges. *Gastroenterol Res Pract* 2013; **2013**: 761060 [PMID: 24159330 DOI: 10.1155/2013/761060]
- 160 **Lanas A**, García-Rodríguez LA, Polo-Tomás M, Ponce M, Alonso-Abreu I, Perez-Aisa MA, Perez-Gisbert J, Bujanda L, Castro M, Muñoz M, Rodrigo L, Calvet X, Del-Pino D, García S. Time trends and impact of upper and lower gastrointestinal bleeding and perforation in clinical practice. *Am J Gastroenterol* 2009; **104**: 1633-1641 [PMID: 19574968 DOI: 10.1038/ajg.2009.164]
- 161 **Handa O**, Naito Y, Fukui A, Omatsu T, Yoshikawa T. The impact of non-steroidal anti-inflammatory drugs on the small intestinal epithelium. *J Clin Biochem Nutr* 2014; **54**: 2-6 [PMID: 24426183 DOI: 10.3164/jcbs.13-84]
- 162 **Maiden L**. Capsule endoscopic diagnosis of nonsteroidal antiinflammatory drug-induced enteropathy. *J Gastroenterol* 2009; **44** Suppl 19: 64-71 [PMID: 19148796 DOI: 10.1007/s00535-008-2248-8]
- 163 **Maiden L**, Thjodleifsson B, Theodors A, Gonzalez J, Bjarnason I. A quantitative analysis of NSAID-induced small bowel pathology by capsule endoscopy. *Gastroenterology* 2005; **128**: 1172-1178 [PMID: 15887101]
- 164 **Higuchi K**, Umegaki E, Watanabe T, Yoda Y, Morita E, Murano M, Tokioka S, Arakawa T. Present status and strategy of NSAIDs-induced small bowel injury. *J Gastroenterol* 2009; **44**: 879-888 [PMID: 19568687 DOI: 10.1007/s00535-009-0102-2]
- 165 **Endo H**, Hosono K, Inamori M, Nozaki Y, Yoneda K, Fujita K, Takahashi H, Yoneda M, Abe Y, Kirikoshi H, Kobayashi N, Kubota K, Saito S, Ohya T, Hisatomi K, Teratani T, Matsushashi N, Nakajima A. Characteristics of small bowel injury in symptomatic chronic low-dose aspirin users: the experience of two medical centers in capsule endoscopy. *J Gastroenterol* 2009; **44**: 544-549 [PMID: 19373431 DOI: 10.1007/s00535-009-0040-z]
- 166 **Matsumoto T**, Kudo T, Esaki M, Yano T, Yamamoto H, Sakamoto C, Goto H, Nakase H, Tanaka S, Matsui T, Sugano K, Iida M. Prevalence of non-steroidal anti-inflammatory drug-induced enteropathy determined by double-balloon endoscopy: a Japanese multicenter study. *Scand J Gastroenterol* 2008; **43**: 490-496 [PMID: 18365915 DOI: 10.1080/00365520701794121]
- 167 **Slessor AA**, Wharton R, Smith GV, Buchanan GN. Systematic review of small bowel diaphragm disease requiring surgery. *Colorectal Dis* 2012; **14**: 804-813 [PMID: 21812898 DOI: 10.1111/j.1463-1318.2011.02741.x]
- 168 **Graham DY**, Opekun AR, Willingham FF, Qureshi WA.

- Visible small-intestinal mucosal injury in chronic NSAID users. *Clin Gastroenterol Hepatol* 2005; **3**: 55-59 [PMID: 15645405]
- 169 **Tacheci I**, Bradna P, Douda T, Bastecká D, Kopáčová M, Rejchrt S, Bureš J. NSAID-Induced Enteropathy in Rheumatoid Arthritis Patients with Chronic Occult Gastrointestinal Bleeding: A Prospective Capsule Endoscopy Study. *Gastroenterol Res Pract* 2013; **2013**: 268382 [PMID: 24382953 DOI: 10.1155/2013/268382]
 - 170 **Goldstein JL**, Eisen GM, Lewis B, Gralnek IM, Zlotnick S, Fort JG. Video capsule endoscopy to prospectively assess small bowel injury with celecoxib, naproxen plus omeprazole, and placebo. *Clin Gastroenterol Hepatol* 2005; **3**: 133-141 [PMID: 15704047]
 - 171 **Chan FK**, Lanas A, Scheiman J, Berger MF, Nguyen H, Goldstein JL. Celecoxib versus omeprazole and diclofenac in patients with osteoarthritis and rheumatoid arthritis (CONDOR): a randomised trial. *Lancet* 2010; **376**: 173-179 [PMID: 20638563 DOI: 10.1016/S0140-6736(10)60673-3]
 - 172 **Maiden L**, Thjodleifsson B, Seigal A, Bjarnason II, Scott D, Birgisson S, Bjarnason I. Long-term effects of nonsteroidal anti-inflammatory drugs and cyclooxygenase-2 selective agents on the small bowel: a cross-sectional capsule enteroscopy study. *Clin Gastroenterol Hepatol* 2007; **5**: 1040-1045 [PMID: 17625980 DOI: 10.1016/j.cgh.2007.04.031]
 - 173 **Leung WK**, Bjarnason I, Wong VW, Sung JJ, Chan FK. Small bowel enteropathy associated with chronic low-dose aspirin therapy. *Lancet* 2007; **369**: 614 [PMID: 17307109 DOI: 10.1016/S0140-6736(07)60282-7]
 - 174 **Green PH**, Cellier C. Celiac disease. *N Engl J Med* 2007; **357**: 1731-1743 [PMID: 17960014 DOI: 10.1056/NEJMr071600]
 - 175 **Lee SK**, Green PH. Endoscopy in celiac disease. *Curr Opin Gastroenterol* 2005; **21**: 589-594 [PMID: 16093775]
 - 176 **Rokkas T**, Niv Y. The role of video capsule endoscopy in the diagnosis of celiac disease: a meta-analysis. *Eur J Gastroenterol Hepatol* 2012; **24**: 303-308 [PMID: 22266837 DOI: 10.1097/MEG.0b013e32834fa914]
 - 177 **El-Matary W**, Huynh H, Vandermeer B. Diagnostic characteristics of given video capsule endoscopy in diagnosis of celiac disease: a meta-analysis. *J Laparoendosc Adv Surg Tech A* 2009; **19**: 815-820 [PMID: 19405806 DOI: 10.1089/lap.2008.0380]
 - 178 **Kurien M**, Evans KE, Aziz I, Sidhu R, Drew K, Rogers TL, McAlindon ME, Sanders DS. Capsule endoscopy in adult celiac disease: a potential role in equivocal cases of celiac disease? *Gastrointest Endosc* 2013; **77**: 227-232 [PMID: 23200728 DOI: 10.1016/j.gie.2012.09.031]
 - 179 **Atlas DS**, Rubio-Tapia A, Van Dyke CT, Lahr BD, Murray JA. Capsule endoscopy in nonresponsive celiac disease. *Gastrointest Endosc* 2011; **74**: 1315-1322 [PMID: 21835400 DOI: 10.1016/j.gie.2011.05.049]
 - 180 **Tennyson CA**, Green PH. The role of capsule endoscopy in patients with nonresponsive celiac disease. *Gastrointest Endosc* 2011; **74**: 1323-1324 [PMID: 22136777 DOI: 10.1016/j.gie.2011.07.021]
 - 181 **Van Weyenberg SJ**, Smits F, Jacobs MA, Van Turenhout ST, Mulder CJ. Video capsule endoscopy in patients with nonresponsive celiac disease. *J Clin Gastroenterol* 2013; **47**: 393-399 [PMID: 23164686 DOI: 10.1097/MCG.0b013e32818-26bea12]
 - 182 **Lidums I**, Teo E, Field J, Cummins AG. Capsule endoscopy: a valuable tool in the follow-up of people with celiac disease on a gluten-free diet. *Clin Transl Gastroenterol* 2011; **2**: e4 [PMID: 23237971 DOI: 10.1038/ctg.2011.3]
 - 183 **Akin E**, Ersoy O. Capsule endoscopy in celiac disease. *Gastroenterol Res Pract* 2012; **2012**: 676073 [PMID: 22235199 DOI: 10.1155/2012/676073]
 - 184 **Kim HM**, Yang S, Kim J, Park S, Cho JH, Park JY, Kim TS, Yoon ES, Song SY, Bang S. Active locomotion of a paddling-based capsule endoscope in an in vitro and in vivo experiment (with videos). *Gastrointest Endosc* 2010; **72**: 381-387 [PMID: 20497903 DOI: 10.1016/j.gie.2009.12.058]
 - 185 **Tortora G**, Valdastrì P, Susilo E, Menciasci A, Dario P, Rieber F, Schurr MO. Propeller-based wireless device for active capsular endoscopy in the gastric district. *Minim Invasive Ther Allied Technol* 2009; **18**: 280-290 [PMID: 19707936 DOI: 10.1080/13645700903201167]
 - 186 **Quirini M**, Menciasci A, Scapellato S, Dario P, Rieber F, Ho CN, Schostek S, Schurr MO. Feasibility proof of a legged locomotion capsule for the GI tract. *Gastrointest Endosc* 2008; **67**: 1153-1158 [PMID: 18513557 DOI: 10.1016/j.gie.2007.11.052]
 - 187 **Gao M**, Hu C, Chen Z, Zhang H, Liu S. Design and fabrication of a magnetic propulsion system for self-propelled capsule endoscope. *IEEE Trans Biomed Eng* 2010; **57**: 2891-2902 [PMID: 20542758 DOI: 10.1109/TBME.2010.2051947]
 - 188 **Yang S**, Park K, Kim J, Kim TS, Cho JJ, Yoon ES. Autonomous locomotion of capsule endoscope in gastrointestinal tract. *Conf Proc IEEE Eng Med Biol Soc* 2011; **2011**: 6659-6663 [PMID: 22255866 DOI: 10.1109/IEMBS.2011.6091642]
 - 189 **Valdastrì P**, Quaglia C, Buselli E, Arezzo A, Di Lorenzo N, Morino M, Menciasci A, Dario P. A magnetic internal mechanism for precise orientation of the camera in wireless endoluminal applications. *Endoscopy* 2010; **42**: 481-486 [PMID: 20506065 DOI: 10.1055/s-0029-1244170]
 - 190 **Swain P**, Toor A, Volke F, Keller J, Gerber J, Rabinovitz E, Rothstein RI. Remote magnetic manipulation of a wireless capsule endoscope in the esophagus and stomach of humans (with videos). *Gastrointest Endosc* 2010; **71**: 1290-1293 [PMID: 20417507 DOI: 10.1016/j.gie.2010.01.064]
 - 191 **Kim HM**, Choi JS, Cho JH. A pilot trial of ambulatory monitoring of gastric motility using a modified magnetic capsule endoscope. *J Neurogastroenterol Motil* 2014; **20**: 261-264 [PMID: 24840379 DOI: 10.5056/jnm.2014.20.2.261]
 - 192 **Keller J**, Fibbe C, Volke F, Gerber J, Mosse AC, Reimann-Zawadzki M, Rabinovitz E, Laver P, Schmitt D, Andresen V, Rosien U, Swain P. Inspection of the human stomach using remote-controlled capsule endoscopy: a feasibility study in healthy volunteers (with videos). *Gastrointest Endosc* 2011; **73**: 22-28 [PMID: 21067740 DOI: 10.1016/j.gie.2010.08.053]
 - 193 **Rey JF**, Ogata H, Hosoe N, Ohtsuka K, Ogata N, Ikeda K, Aihara H, Pangtay I, Hibi T, Kudo SE, Tajiri H. Blinded nonrandomized comparative study of gastric examination with a magnetically guided capsule endoscope and standard videoendoscopy. *Gastrointest Endosc* 2012; **75**: 373-381 [PMID: 22154417 DOI: 10.1016/j.gie.2011.09.030]
 - 194 **Denzer UW**, Rösch T, Hoytat B, Abdel-Hamid M, Hebuterne X, Vanbiervelt G, Filippi J, Ogata H, Hosoe N, Ohtsuka K, Ogata N, Ikeda K, Aihara H, Kudo S, Tajiri H, Treszl A, Wegscheider K, Greff M, Rey J. Magnetically Guided Capsule Versus Conventional Gastroscopy for Upper Abdominal Complaints: A Prospective Blinded Study. *J Clin Gastroenterol* 2014; **49**: 101-107 [PMID: 24618504 DOI: 10.1097/MCG.0000000000000110]
 - 195 **Pasricha T**, Smith BF, Mitchell VR, Fang B, Brooks ER, Gerding JS, Washington MK, Valdastrì P, Obstein KL. Controlled colonic insufflation by a remotely triggered capsule for improved mucosal visualization. *Endoscopy* 2014; **46**: 614-618 [PMID: 24845802 DOI: 10.1055/s-0034-1365497]
 - 196 **Obstein KL**, Battaglia S, Smith BF, Gerding JS, Valdastrì P. Novel approach for colonic insufflation via an untethered capsule (with video). *Gastrointest Endosc* 2013; **77**: 516-517 [PMID: 23410707 DOI: 10.1016/j.gie.2012.10.010]
 - 197 **Gorlewicz JL**, Battaglia S, Smith BF, Ciuti G, Gerding J, Menciasci A, Obstein KL, Valdastrì P, Webster RJ. Wireless insufflation of the gastrointestinal tract. *IEEE Trans Biomed Eng* 2013; **60**: 1225-1233 [PMID: 23212312 DOI: 10.1109/TBME.2012.2230631]
 - 198 **Natali CD**, Beccani M, Obstein KL, Valdastrì P. A wireless

- platform for in vivo measurement of resistance properties of the gastrointestinal tract. *Physiol Meas* 2014; **35**: 1197-1214 [PMID: 24852810 DOI: 10.1088/0967-3334/35/7/1197]
- 199 **Woods SP**, Constandinou TG. Wireless capsule endoscope for targeted drug delivery: mechanics and design considerations. *IEEE Trans Biomed Eng* 2013; **60**: 945-953 [PMID: 23192476 DOI: 10.1109/TBME.2012.2228647]
 - 200 **Valdastri P**, Quaglia C, Susilo E, Menciassi A, Dario P, Ho CN, Anhoeck G, Schurr MO. Wireless therapeutic endoscopic capsule: in vivo experiment. *Endoscopy* 2008; **40**: 979-982 [PMID: 19065478 DOI: 10.1055/s-0028-1103424]
 - 201 **Schostek S**, Schurr MO. European research on wireless endoscopy--the VECTOR project. *Stud Health Technol Inform* 2013; **189**: 193-199 [PMID: 23739381]
 - 202 **Yim S**, Gultepe E, Gracias DH, Sitti M. Biopsy using a magnetic capsule endoscope carrying, releasing, and retrieving untethered microgrippers. *IEEE Trans Biomed Eng* 2014; **61**: 513-521 [PMID: 24108454 DOI: 10.1109/TBME.2013.2283369]
 - 203 **Pezzoli A**. Wireless endoscopy capsules should not be released in the environment. *Gastrointest Endosc* 2014; **80**: 191-192 [PMID: 24950652 DOI: 10.1016/j.gie.2014.02.021]
 - 204 **Pezzoli A**, Ricci N, Fusetti N, Zelante A, Carella A, Gullini S. Reactivation of used endoscopic capsules: A pilot study. *Dig Liver Dis* 2011; **43**: S160 [DOI: 10.1016/S1590-8658(11)60264-8]
 - 205 **Chen X**, Ran ZH, Tong JL. A meta-analysis of the yield of capsule endoscopy compared to double-balloon enteroscopy in patients with small bowel diseases. *World J Gastroenterol* 2007; **13**: 4372-4378 [PMID: 17708614]
 - 206 **Leung WK**, Ho SS, Suen BY, Lai LH, Yu S, Ng EK, Ng SS, Chiu PW, Sung JJ, Chan FK, Lau JY. Capsule endoscopy or angiography in patients with acute overt obscure gastrointestinal bleeding: a prospective randomized study with long-term follow-up. *Am J Gastroenterol* 2012; **107**: 1370-1376 [PMID: 22825363 DOI: 10.1038/ajg.2012.212]
 - 207 **Wang Z**, Chen JQ, Liu JL, Qin XG, Huang Y. CT enterography in obscure gastrointestinal bleeding: a systematic review and meta-analysis. *J Med Imaging Radiat Oncol* 2013; **57**: 263-273 [PMID: 23721134 DOI: 10.1111/1754-9485.12035]
 - 208 **Chong AK**, Taylor A, Miller A, Hennessy O, Connell W, Desmond P. Capsule endoscopy vs. push enteroscopy and enteroclysis in suspected small-bowel Crohn's disease. *Gastrointest Endosc* 2005; **61**: 255-261 [PMID: 15729235]

P-Reviewer: Konishi K, Luo HS **S-Editor:** Tian YL

L-Editor: A **E-Editor:** Zhang DN





Published by **Baishideng Publishing Group Inc**

8226 Regency Drive, Pleasanton, CA 94588, USA

Telephone: +1-925-223-8242

Fax: +1-925-223-8243

E-mail: bpgoffice@wjgnet.com

Help Desk: <http://www.wjgnet.com/esps/helpdesk.aspx>

<http://www.wjgnet.com>

