

*Acta chir belg*, 2007, **107**, 000-000

## Cystic Lesions in the Liver : Benign or Malignant ?

O. C. M. Varin\*, D. S. E. Varin\*\*, F. C. Berrevoet\*

\*Department of General Surgery, Division of Hepatobiliary and Liver Transplantation Service, Ghent University Hospital Medical School, Ghent, Belgium ; \*\*Erasmus Medical Center, Rotterdam, The Netherlands.

**Key words.** Polycystic liver lesions ; biliary microhamartoma ; hepatobiliary cystadenocarcinoma.

**Abstract.** A 65-year old patient is presented with an ultrasound showing multiple cysts in liver and both kidneys. Computed tomography scan (CT-scan) showed a cyst in the right liver lobe with a largest diameter of 12 cm, suspicious for cystadenocarcinoma. Further staging showed no extrahepatic metastasis. Considering possible malignancy, aspiration of the cyst was not an option because of the risk for end-metastasis. Resection of the tumour was considered as the best treatment. Peroperatively the cyst was localized with ultrasound, after which an extended right hepatectomy was performed. No peroperative complications occurred. Histological diagnosis was a cyst, originating in dilated von Meyenburg complexes. No signs of a biliary cystadenoma or malignant deformation were observed. A CT-scan 1 year postoperatively showed some other small cysts in the left liver lobe, the patient was free of any complaints. The differential diagnosis in cases of asymptomatic liver cysts will be discussed.

### Introduction

Cystic lesions of the liver are not rare and give rise to complaints if the cysts are large enough to cause compression on stomach or other intra-abdominal organs. In most cases, ultrasound or abdominal computed tomography scan (CT-scan) will give rise to the diagnosis (1-2). Cysts of over 4 cm with different compartments will more often be diagnosed by physical examination (1). In case of larger cystic deformities, the complication rate and the percentage of malignant deformation is higher, but still rare (1, 3). However, histological proof of malignant deformity of a liver cyst, suspicious at CT or ultrasound, is difficult to obtain. This case will show this more in detail.

### Case report

A 65-year old lady with a body weight of 74 kg presented at the department of internal medicine with a polycystic disease in liver and kidneys. Due to a chronic cystitis, the general practitioner asked for an abdominal ultrasound that evidenced the cysts. There were no abdominal complaints. Her family history showed cystic kidney disease on her father's side as well as an aunt with liver and kidney cysts. Her own medical history showed arterial hypertension for which she took Tenoretic<sup>®</sup> once a day. The patient did not report any travelling to countries with a higher risk of *Echinococcus granulosus* infection. Physical examination showed some hepatomegaly and varicosis on both legs. Chest X-ray was normal and her blood results

showed an erythrocyte sedimentation rate (ESR) of 49 mm/hour (0-30 mm/hour), urea 11.9 mmol/l (2.9-7.7 mmol/l), creatinin 162 µmol/l (40-95 µmol/l), gamma-glutamyltranspeptidase (GGT) 37 U/l (0-35 U/l), total bilirubin 18 µmol/l (neg). Carbohydrate antigen 19-9 (CA 19-9) was not checked. Abdominal imaging, ultrasound, CT and magnetic resonance imaging (MRI), showed cysts besides kidney, several liver cysts with the largest cyst of 12 cm diameter in the dorsal part of the right liver lobe. In the cystic wall a nodular tumour was observed, suspicious for biliary cystadenocarcinoma (Fig. 1). No dilation of the biliary tract was seen. As the observed deformity was suspicious for malignancy we decided not to puncture the lesion but to perform surgery. Peroperatively the suspicious cyst could be localized by ultrasound. An extended right hepatectomy was performed (Fig. 2) and several other cysts were drained and coagulated by the argon laser beamer. Histological examination showed dilated von Meyenburg complexes, also reported as biliary microhamartomas. There were no arguments for a biliary cystadenoma or malignancy in general, but a recent bleeding in the lesion was observed. The postoperative course was uneventful and the abdominal CT after one year showed only small cysts in the liver without suspicious deformities.

### Discussion

In contrast with solitary cysts, large cystic lesions in the liver with different compartments diagnosed during ultrasound or CT-scan should critically be looked at,

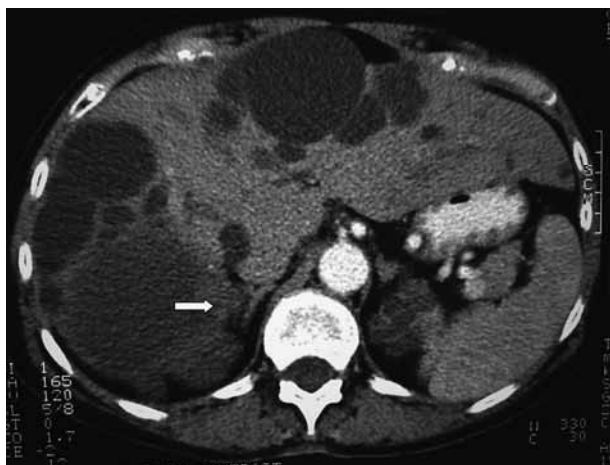

Fig. 1

Abdominal CT-scan of a polycystic liver, with a large cyst in the right lobe containing a solid deformity in the wall (arrow), suspicious for a hepatobiliary cystadenocarcinoma.

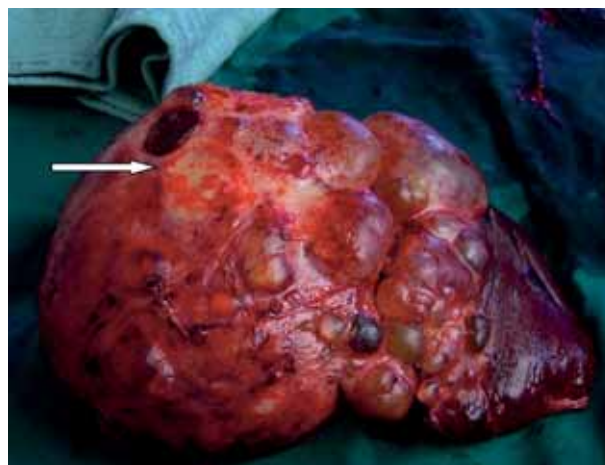


Fig. 2

Resected specimen after extended right hepatectomy with suspicious cystic lesion (arrow). Peroperatively localized by ultrasound.

COLOR PRINT ?

because of possible malignant character (2-3). Inhomogeneous aspects of the cystic wall by nodules or solid parts are examples of such characteristics. These are best observed after contrast enhancement (4-5). However, despite our current medical imaging, with ultrasound, CT-scan and MRI, the recognition and interpretation of these cystic lesions, with a possible malignant appearance, is still difficult. Furthermore, a recent bleeding inside the cysts, might influence the interpretation of the imaging (4, 6). Increase of the tumour marker CA 19-9 can be an indication for suspicion. As puncture of the lesion for histological examination might increase the risk for metastasis, it was not proposed (6). The presence of Echinococcus cysts should of course always be borne in mind (1).

Malignant deformities of liver cysts are rare. In a series of 78 patients with liver cysts, only one had a diagnosis of biliary cystadenocarcinoma and only 8 that of biliary cystadenoma (1). In case of suspicion for malignancy, diagnosis of biliary cystadenoma, and more specifically the mucinous type, is the most prevalent one (5). Both the edge of this cyst, consisting of a thin and smooth outer layer, and the presence of mucinous fluid in different compartments are the most significant characteristics (1, 5). This type of cyst counts for 5% of all liver cysts, is mostly asymptomatic and can evolve into a hepatobiliary cystadenocarcinoma (2-3). The biliary cystadenoma is more frequent in women and may even contain ovarian stroma by fusion of gonadal epithelium with an adjacent organ during embryonic development (7). The problem of an autosomal dominant polycystic liver disease is rather low (0.05-0.13%). One can distinguish 2 types. In the first type, the liver cysts are

part of an autosomal dominant polycystic kidney disease, while in the second, no kidney cysts are present (8). In the latter case, it is important to include in the differential diagnosis the possibility of a malignant deformation. In this type of liver disease, deformity of cysts is rather rare, but has been reported before (9). Other possible complications of this disease are infection, bleeding inside the cyst, rupture of cysts or obstructive icterus (1). Surgical resection should be the therapy of choice for liver cysts with suspicious imaging for malignancy or for a biliary cystadenoma (2, 6). Although, the latter might lead to extensive surgery for only a small chance of finding malignancy. However, currently, liver surgery for these indications has low morbidity and mortality in tertiary Centers (1-2).

At definitive histology, no arguments were observed for biliary cystadenoma or a cystadenocarcinoma. However, dilated von Meyenburg complexes or biliary microhamartomas were present. These complexes, usually multiple, are best looked at as a congenital malformation with focal proliferation of masses of hepatic cells, blood vessels, smaller bile ducts and connective tissue, and extensively branched structures lined by cuboidal epithelium (6, 10). By occlusion of these branched structures, progressive dilation occurs and cysts may develop, often with nodularity.

This has been considered as an important aetiology for polycystic liver disease (6, 10).

As demonstrated in this particular case, radiological imaging and macroscopic morphology of these multicystic and multifocal structures might be suspicious for malignancy. However, the differentiation is only possible by histological examination (10).

## Conclusion

Although malignancy from pre-existing liver cysts, even in autosomal dominant polycystic liver disease, is relatively rare, a critical appraisal of these lesions seems necessary. If abdominal imaging by CT-scan or MRI shows suspicion for malignancy, a complete surgical resection of the cyst is the therapy of choice. In high volume centers for hepatobiliary surgery, both morbidity and mortality after surgical resection for this indication is acceptable. Differentiation between benign and malignant lesions can be extremely difficult in case of Von Meyenburg complexes.

## References

1. REGEV A., RAJENDER REDDY K., BERHO M. *et al.* Large cystic lesions of the liver in adults : A 15-year experience in a tertiary center. *J Am Coll Surg*, 2001, **193** : 36-45.
2. KAMMULA U. S., BUELL J. F., LABOW D. M., ROSEN S., MILLIS J. M., POSNER M. C. Surgical management of benign tumors of the liver. *Int J Gastrointest Cancer*, 2001, **30** : 141-6.
3. SHRIKHANDE S., KLEEF J., ADYANTHAYA K., ZIMMERMAN A., SHRIKHANDE V. Management of hepatobiliary cystadenocarcinoma. *Dig Surg*, 2003, **20** : 60-3.
4. BUETOW P. C., BUCK J. L., PANTONGRAG-BROWN L. *et al.* Biliary cystadenoma and cystadenocarcinoma, clinical-imaging pathologic correlations with emphasis on the importance of ovarian stroma. *Radiology*, 1995, **196** : 805-10.
5. DEVANEY K., GOODMAN Z. D., ISHAK K. G. Hepatobiliary cystadenoma and cystadenocarcinoma : a light microscopic and immunohistochemical study of 70 patients. *Am J Surg Pathol*, 1994, **18** : 1078-91.
6. BIEKER E., FISHER H. P., STRUNK H., SAUERBRUH T. Benign hepatic tumors. *Z Gastroenterol*, 2003, **41** : 191-200.
7. POELMA M., LAMERS W. H., DRILLENBURG P., OFFERHAUS G. J. A., GOUMA D. J., VAN GULLIK T. M. Cystadenomen met ovarieel stroma in lever en pancreas : aanwijzingen voor embryonale migratie van gonadaal eptiheel. *Ned Tijdschr Geneesk*, 2004, **148** : 320-5.
8. JANSSENS A. R., JANSSEN M. J. Gastrointestinal surgery and gastroenterology. XV. Polycystic liver disease. *Ned Tijdschr Geneesk*, 2002, **146** : 885-90.
9. REHULOVA E., DITE P. Multiple carcinomas arising from congenital cysts of the liver and kidneys. *Cesk Patol*, 1981, **17** : 198-203.
10. KARHUNEN P. J. Adult polycystic liver disease and biliary microhamartomas (von Meyenburg's complexes. *Acta Pathol Microbiol Immunol Scand*, 1986, **94** : 397-400.

O. C. M. Varin  
 Department of Surgery, Division of Hepatobiliary and Liver Transplantation Surgery  
 Ghent University Hospital Medical School, 2K12 IC  
 De Pintelaan 185  
 B-9000 Ghent, Belgium  
 Tel. : +32 9 240 55 19  
 Fax : +32 9 240 38 91  
 E-mail : oswald.varin@Ugent.be