

Arthrography and MRI for evaluation of shoulder joint pathology

H. van Bree, I. Gielen

Department of Medical Imaging & Small Animal Orthopaedics

Veterinary Faculty, Ghent University

The canine shoulder is a complex joint, with numerous passive and active soft tissue stabilizing components. It is a ball-and-socket joint, which allows movement in essentially every direction. In the dog and cat, however, most of the motion takes place in a direct cranial-to-caudal plane, resulting mainly in extension and flexion of the joint. The medial and lateral glenohumeral ligaments are not really ligaments, but rather thickenings of the respective surfaces of the joint capsule. They are rather weak, so it is the strength of the heavy musculature surrounding the shoulder joint that maintains its integrity.

Shoulder lameness, although a common condition in the dog, can be difficult to localise, and determining the specific cause is often challenging. Even when the lameness has been localized to the shoulder, identifying the precise cause can be frustrating.

Some of the indications for imaging of the shoulder joint are:

- Any lameness associated with a shoulder problem: i.e. pain on manipulation of the joint itself or any of the structures in the shoulder area.
- Swelling or deformity of the shoulder region.
- Atrophy of the adjacent shoulder muscles.

Possible imaging techniques:

Scintigraphy can be used to localise lameness originating in the shoulder region and to evaluate the significance of equivocal radiological findings.

Plain radiography: standard radiographs provide only limited diagnostic information, and frequently there is a poor correlation between the radiological findings and clinical signs. There may be extensive changes due to degenerative joint disease (DJD) present, with no lameness but as an incidental finding in older dogs. The radiological assessment of the shoulder joint should include evaluation of alignment, subchondral bone, joint space, and adjacent periarticular soft tissues. Many of the joint tissues – such as cartilage, synovial membrane, fibrous capsule, and collagenous structures – are not visible on plain radiographs and therefore can only be evaluated indirectly, by (for example) calcification within tendons and irregularities at their attachments.

Arthrography and/or ultrasound can be helpful in visualizing some of these structures.

Arthrography of the shoulder joint is the most common arthrographic procedure used in small animal orthopaedics. It is a useful and simple technique for imaging various shoulder problems in the dog. Several bursae around the scapulohumeral joint can be visualised. The bicipital tendon sheath and subscapular recess are always visible, whereas the infraspinatus bursa is only occasionally seen. Arthrography can outline the articular cartilage, synovial membrane, biceps tendon and associated synovial sheath (but cannot identify smaller lesions within the biceps tendon), various bursae, a cartilage flap in shoulder osteochondrosis (OCD) and radiolucent joint mice. In cases of shoulder OCD, positive-contrast arthrography helps to assess – with an accuracy of 80% – whether a non-mineralized cartilage flap is present, and this finding helps to determine whether a dog should be treated conservatively or surgically. In cases of bicipital pathology, positive contrast arthrography may demonstrate changes in the contour of the bicipital groove and tendon, incomplete filling of the synovial sheath, filling defects and irregularities. It can also aid decision making in cases of caudal glenoid fragmentation. With the use of positive arthrography, impingement of the joint capsule can be demonstrated, and the fragment is visible as a filling defect.

Ultrasonography (US) can be used in the shoulder joint to diagnose muscle and tendon injury and to evaluate OC lesions. A high-frequency linear transducer is used for this examination, and the dog may have to be anaesthetised if joint manipulation is painful. The humeral head is visible as a hyperechoic convex curvilinear line with a strong acoustic shadow, and the cartilage as an anechoic layer covered by the joint capsule, the tendons of the infraspinatus and teres minor muscle and the acromial part of the deltoid muscle. For the evaluation of the bicipital tendon sheath, cross-sectional images at the level of the bicipital groove and longitudinal images at the level of the attachment on the supraglenoid tubercle are taken. Results of a recent study in shoulder OCD – comparing ultrasound with radiography, arthrography and arthroscopy – suggest that all radiologically diagnosed subchondral lesions in the humeral head can be visualised by the use of ultrasound as a concave deviation of the hyperechoic subchondral bone line with a variable length according to the extent of the lesion. The results also suggest that the presence of a second hyperechoic line at the bottom of the subchondral defect seen on US is a pathognomonic sign for the presence of a flap. It was suggested that US might present an alternative to positive contrast arthrography. With the use of ultrasound, bicipital lesions and supraspinatus tendinopathy can be identified. This technique is highly operator-dependant and requires experience.

Computed tomography (CT): The use of CT can be justified in some conditions, especially in situations where one wants to avoid superimposition of bony structures when evaluating the extent of processes, or to determine the source of calcifications or fragments seen on plain film radiographs. New bone formation in the bicipital groove can be easily seen. Also, CT may be useful in cases with suspect demineralisation, as this technique can detect loss of bone content at an earlier stage than conventional radiography can. Also, arthro-CT can be performed to check the integrity of the biceps tendon. In the case of soft tissue involvement of the shoulder region, IV contrast can be applied with a dose of 200 mg I/kg bodyweight. CT guided biopsies of neoplastic processes in the shoulder region can be performed.

Magnetic resonance imaging (MRI) can provide a more complete look at important canine soft tissue shoulder structures. MRI is a non-invasive diagnostic modality that provides a high-contrast, multi-planar depiction of joint associated anatomy. Superior soft tissue image resolution, along with the ability to image in multiple planes, has made MR imaging the diagnostic modality of choice for joint pathology in human orthopaedics. MRI relies on interactions between an external magnetic field, radio waves and hydrogen nuclei in the body. The tissue contrast seen with MRI is due to the differences in the magnetic properties of each tissue.

MRI protocols and studies:

Several protocols for MR imaging of the shoulder have been proposed applying different sequences and planes – but essentially T1 (sometimes with contrast), T2 and STIR (short tau inversion recovery) images are always necessary (Figure 1). Depending on which structures one wants to visualise, images in the sagittal, transverse and dorsal plane are obtained. Protocols have been proposed with the limb in both flexion and extension. To visualise the joint capsule and glenohumeral ligaments, positioning of the shoulder in extension using intra-articular contrast has been described. The major periarticular anatomic structures of the normal canine shoulder can consistently be identified, but evaluation of the glenohumeral structures remains difficult. Cortical bone is visible on MRI as a signal void; but, to evaluate new bone formation, CT still is the modality of choice. Visualisation of canine articular cartilage remains a controversial issue. Even with high-field MRI, the resolution is not good enough to depict the thin canine cartilage.

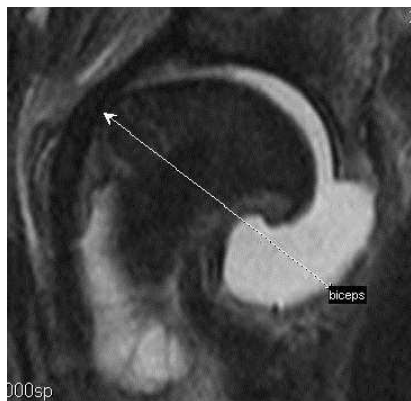


Figure 1: A STIR image of an inflamed shoulder joint clearly showing the massive joint effusion.

Data on the use of low-field MRI in shoulder problems in dogs are scarce. The protocol used in our department is to start with a STIR sequence, imaging both elbows in extension in the dorsal plane to rule out brachial plexus pathology. Then, both shoulder joints are imaged in extension separately, using a T1 (plane and after intravenous application of a paramagnetic contrast agent, if indicated) sequence. Then, a T2 sequence is performed. Both sequences are obtained in sagittal and transverse planes.

MRI has been evaluated for detecting OC lesions in the canine humeral head and was found to be useful in assessing the extent and severity of subchondral bone lesions. Although articular cartilage discontinuity could be detected, loose flaps were not always demonstrated and articular cartilage could not be distinguished from synovial fluid. In this study, MR arthrography proved to be ineffective in visualising canine articular cartilage.

In one study, where surgical exploration for shoulder pain had been performed in 21 dogs, a high level of agreement and concordance between MRI and surgical findings has been found. However, this study was somewhat limited, because the radiologists were not blinded but were aware of the case data. Still, this study demonstrated the potential of MRI in the field of canine shoulder lameness.

Another study established that MRI was a good imaging technique for detection of supraspinatus tendinopathy, where impingement or displacement of the biceps tendon by the enlarged supraspinatus tendon was often observed on imaging, contributing to development of clinical signs.

One should be aware of artefacts produced by identification "chips" when imaging the shoulder region and the "magic angle" artefact when evaluating tendon integrity using a T1 sequence.

Additional reading:

Agnello KA, Puchalski SM, Wisner ER, Schulz KS, Kapatkin AS. Effect of positioning, scan plane, and arthrography on visibility of periarticular canine shoulder soft tissue structures on magnetic resonance images. *Vet Radiol Ultrasound*. 2008 Nov-Dec;49(6):529-39.

Fransson BA, Gavin PR, Lahmers KK. Supraspinatus tendinosis associated with biceps brachii tendon displacement in a dog. *J Am Vet Med Assoc*. 2005 Nov 1;227(9):1429-33, 1416.

Gielen & van Bree, Chapter 38 – CT of the shoulder joint. In Schwarz T, Saunders J, editors: *Veterinary computed tomography*, Oxford, 2011, Wiley-Blackwell.

Janach KJ, Breit SM, Künzel WW. Assessment of the geometry of the cubital (elbow) joint of dogs by use of magnetic resonance imaging. *Am J Vet Res.* 2006 Feb;67(2):211-8.

Kramer M, Gerwing M, Sheppard C, Schimke E. Ultrasonography for the diagnosis of diseases of the tendon and tendon sheath of the biceps brachii muscle. *Vet Surg.* 2001 Jan-Feb;30(1):64-71.

Lafuente MP, Fransson BA, Lincoln JD, Martinez SA, Gavin PR, Lahmers KK, Gay JM. Surgical treatment of mineralized and nonmineralized supraspinatus tendinopathy in twenty-four dogs. *Vet Surg.* 2009 Apr;38(3):380-7.

Long CD, Nyland TG. Ultrasonographic evaluation of the canine shoulder. *Vet Radiol Ultrasound.* 1999 Jul-Aug;40(4):372-9.

Murphy SE, Ballegeer EA, Forrest LJ, Schaefer SL. Magnetic resonance imaging findings in dogs with confirmed shoulder pathology. *Vet Surg.* 2008 Oct;37(7):631-8.

Schaefer SL, Forrest LJ. Magnetic resonance imaging of the canine shoulder: an anatomic study. *Vet Surg.* 2006 Dec;35(8):721-8.

Schaefer SL, Baumel CA, Gerbig JR, Forrest LJ. Direct magnetic resonance arthrography of the canine shoulder. *Vet Radiol Ultrasound.* 2010 Jul-Aug;51(4):391-6.

Sidaway BK, McLaughlin RM, Elder SH, Boyle CR, Silverman EB. Role of the tendons of the biceps brachii and infraspinatus muscles and the medial glenohumeral ligament in the maintenance of passive shoulder joint stability in dogs. *Am J Vet Res.* 2004 Sep;65(9):1216-22.

Vandeveld B, Van Ryssen B, Saunders JH, Kramer M, Van Bree H. Comparison of the ultrasonographic appearance of osteochondrosis lesions in the canine shoulder with radiography, arthrography, and arthroscopy. *Vet Radiol Ultrasound.* 2006 Mar-Apr;47(2):174-84.

van Bree H, Van Ryssen B, Degryse H, Ramon F. Magnetic resonance arthrography of the scapulohumeral joint in dogs, using gadopentetate dimeglumine. *Am J Vet Res.* 1995 Mar;56(3):286-8.

van Bree H. Comparison of the diagnostic accuracy of positive-contrast arthrography and arthrotomy in evaluation of osteochondrosis lesions in the scapulohumeral joint in dogs. *J Am Vet Med Assoc.* 1993 Jul 1;203(1):84-8.

van Bree H, Degryse H, Van Ryssen B, Ramon F, Desmidt M. Pathologic correlations with magnetic resonance images of osteochondrosis lesions in canine shoulders. *J Am Vet Med Assoc.* 1993 Apr 1;202(7):1099-105.

van Bree H. Comparison of the diagnostic accuracy of positive-contrast arthrography and arthrotomy in evaluation of osteochondrosis lesions in the scapulohumeral joint in dogs. *J Am Vet Med Assoc.* 1993 Jul 1;203(1):84-8.

van Bree H & Gielen I. The shoulder joint and scapula. *BSAVA Manual of Canine and Feline Musculoskeletal Imaging*, 2006, Chapter 7, p 86-102. Edited by F.J. Barr and R.M. Kirberger.

Xia, Y. Resolution 'scaling law' in MRI of articular cartilage. *Osteoarthritis and Cartilage* 2007, 15, 363-365