

How to read the equine electrocardiogram?

Prof. dr. Gunther van Loon

DVM, PhD, Dipl ECEIM

Department of Large Animal Internal Medicine, Ghent University

Belgium

Gunther.vanLoon@UGent.be

Introduction

Recording of an electrocardiogram (ECG) is used for monitoring heart rate and is mandatory to diagnose dysrhythmias. Recording is performed at rest (ambulatory) or during exercise. Prolonged recordings (e.g. 24 hour ECG recording) are predominantly used in case of syncope or when treating rhythm disturbances such as atrial fibrillation or ventricular tachycardia. Diagnosis of a dysrhythmia in a horse should always lead to further diagnostic work-up to find the underlying cause of the dysrhythmia such as electrolyte disorders, valvular regurgitation, cardiac dilatation, myocardial disease, intoxication,... Echocardiography, haematology and biochemistry including cardiac troponin I (cTnI) should be performed as initial examinations.

ECG recording

Self-adhesive electrodes are most frequently used. Except in case of a very long hair coat, clipping is not necessary as the electrodes usually better stick to hair than to clipped skin. Adding a small amount of contact gel is beneficial in case of long hair coat. Multiple electrode positions and lead recordings have been described. The fact that ECG vector analysis is not applicable in horses makes that the exact electrode position is of limited importance. The reference electrode (e.g. N electrode, black) is usually placed on the left shoulder-triceps region. In order to obtain a 'normal' ECG configuration with a positive P wave and a largely negative QRS complex, a positive electrode (e.g. LA electrode, yellow) should be placed on the left thorax, just caudoventral to the olecranon. As the main cardiac vector points from this location to dorsal, to cranial and slightly to the right, the negative electrode (e.g. RA electrode, red) should be located along this vector. Placing it on the right lower third of the jugular furrow will produce the base-apex ECG when recording from lead I. In order to make ECG recordings during exercise or long-term recordings, the negative electrode is commonly placed in the left neck before the scapula or left to the withers (e.g. under a girth). Generally, recording from 1 lead is sufficient to make a diagnosis. However, multiple lead recordings may facilitate making a diagnosis under certain circumstances.

The normal ECG

1. Basic concepts

The ECG reflects the electrical activity of the heart but artefacts (muscle artefacts, electrical interference,...) are frequently found and must be differentiated from the real cardiac activity. One should bear in mind that the equine ECG does not allow to diagnose changes in cardiac morphology, only to record heart rate and heart rhythm. Both atria and also both ventricles act as a pseudo-syncytium which means that they always depolarise 'as a whole'. After depolarisation of the myocardial cell a short refractory period prevents it to be depolarised again, thus preventing a tetanic condition. Atria and ventricles are completely isolated from each other with only one connection, the atrioventricular (AV) node. From the AV node specialised conduction tissue originates to spread into the ventricles (His – Purkinje system). This specialised conduction tissue spreads the electrical signal rapidly over the whole ventricular myocardium. This route of depolarisation results in the most efficient, organised ventricular contraction and produces a small and sharp QRS complex. Any other route of

electrical activation (e.g. premature beat) results in a broadening of the QRS complex because the myocardial cell-to-cell conduction is slower compared to the specialised conduction tissue.

2. Classification

Simply spoken, there are 4 regions of interest, through which the electrical signal travels consecutively during one normal cardiac cycle. These regions are (1) sinus node, (2) atrial myocardium, (3) AV node and (4) ventricular myocardium. Only depolarisation of a large mass will result in a visible deflection on the ECG. This means that depolarisation (and even repolarisation) of atrial myocardium and also ventricular myocardium results in deflections on the surface ECG. The sinus node and AV node are too small for their depolarisation to be seen on the surface ECG.

Often the cardiac rhythm or rate is described referring to the site of origin of the impulses. A ventricular or supra-ventricular rhythm indicates that the impulses are generated in the ventricular myocardium, or coming from any tissue 'above' that, respectively. A sinus rhythm or atrial rhythm originates from the sinus node or the atrial myocardium, respectively. Sinus tachycardia, atrial tachycardia and ventricular tachycardia indicate a high heart rate originating from the sinus node, atrial myocardium or ventricular myocardium, respectively.

3. The normal cardiac cycle

Impulse formation starts at the sinus node (not visible on the ECG). This impulse enters the atrial myocardium and depolarises both atria, producing a P wave on the surface ECG. This P wave is often bifid (or biphasic), especially at slow rates. After it's spread over the atria, the electrical impulse enters the AV node. In the AV node, conduction is very slow in order to produce a short time-delay between atrial and ventricular contraction. This short time delay presents on the ECG as the isoelectric PQ segment. Once through the AV node, the depolarisation wave is rapidly conducted over the His-Purkinje system to result in a massive, organised depolarisation of the ventricular myocardium, resulting in a QRS complex. Because of the large mass of the ventricles, also repolarisation is clearly seen on the ECG as a T wave. The T wave can be positive, negative or biphasic in normal horses. At high heart rates, the T wave will become opposite (positive) to the QRS complex. This means that T wave polarity may suddenly shift depending on heart rate.

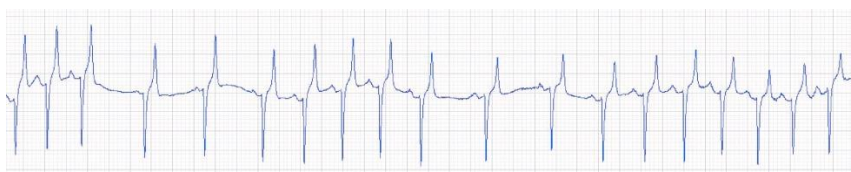Dysrhythmias

There are many ways to classify dysrhythmias (e.g. abnormalities in impulse formation, in impulse conduction,...). Below, dysrhythmias will be classified depending on their site of origin: (1) sinus node, (2) atrial myocardium, (3) AV node and (4) ventricular myocardium.

1. Sinus node

The sinus node determines the normal heart rate and is the pacemaker of the heart. The normal (regular) cardiac rhythm is therefore called 'sinus rhythm'. A too slow impulse formation in the sinus node produces sinus bradycardia, usually because of a high vagal tone. It is characterised by a slow regular rate (less than 24/min) with normal P-QRS-T relation. Increased rate of impulse formation results in sinus tachycardia and is usually caused by stress, exercise, pain,... It presents as an increased heart rate with a regular rhythm and with normal P-QRS-T relation.

High vagal tone may prevent the sinus nodal impulse to exit from the sinus node into the atrial myocardium. As such, one P wave and QRS-T

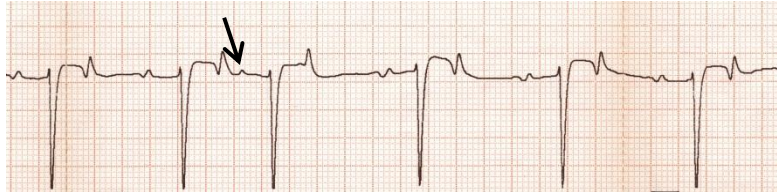


Sinus arrhythmia during recovery from exercise results in 'accordion-like' changes in heart rate.

are missing, causing a pause that is exactly double the normal rhythm. This arrhythmia is called sinus (exit) block. Changes between vagal and sympathetic tone cause a waxing and waning of the rate at which the sinus node fires. This sinus arrhythmia results in progressive increase and decrease in heart rate. P-QRS-T morphology and relation are normal but PP intervals vary and produce an arrhythmia. This sinus arrhythmia typically occurs during recovery from exercise, when heart rate drops from about 110 to 50 bpm. When the sinus node produces a normal, regular rhythm but occasionally fails to produce an impulse for a brief period of time, sinus arrest is present. This arrhythmia is usually vagal induced and results in a pause in cardiac rhythm that is more than double the normal interbeat interval but P-QRS-T morphology and relation are normal.

2. Atrial myocardium

Atrial premature contractions (APCs) are impulses that originate from the atrial myocardium. The impulse depolarises both atria and produces a P wave that occurs too early (and that may have a slightly different duration and/or shape).

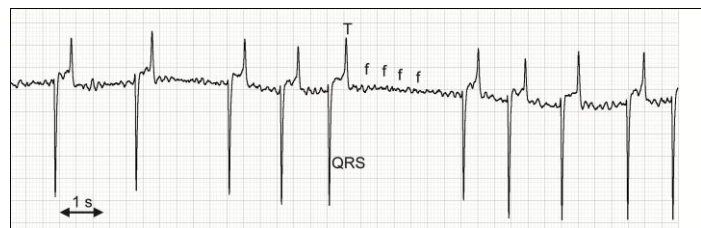

Atrial premature contraction with non-compensatory pause

Depending on its prematurity, the impulse may or may not conduct over the AV node and depolarise the ventricles (normal QRS morphology and duration because the impulse follows the normal conduction pathway). Often, the APC will reset the 'timer' of the sinus node so that the APC is followed by a non-compensatory pause. This means that the interval of normal – premature - normal complex is shorter than the interval of 3 normal complexes. On some occasions a compensatory pause is present (when resetting of the sinus node did not occur) or the APC may be interlaced (not disturbing the underlying rhythm).

When 3 or more consecutive APCs occur the rhythm is called atrial tachycardia. This rhythm may be paroxysmal (occurring in bouts) or persistent. Especially at higher rates, conduction to the ventricles may be 2/1 or 3/1 or irregular. Because the conduction to the ventricles is via the AV node and the His-Purkinje system, QRS morphology is normal.

During atrial fibrillation, a very rapid (around 350 depolarisations per minute), chaotic and self-sustaining electrical activity, independent of the sinus node, is present in the atrial myocardium. This rapid electrical activity results in f-waves on the ECG and organised atrial depolarisations are no longer present (no P waves).



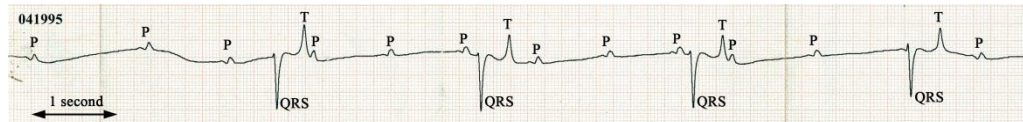
Atrial fibrillation

At irregular intervals pulses are conducted through the AV node. This results in QRS complexes with normal morphology, occurring at irregularly irregular intervals. Under high vagal tone (at rest) the AV node blocks most of the atrial impulses so that final heart rate remains normal in horses (in contrast to humans, dogs,...). However, during exercise or stress, when vagal tone ceases, the AV node will lose this blocking function, suddenly allowing a high number of pulses to conduct to the ventricles, resulting in a disproportionately high ventricular answer. The author has recorded ventricular rates of over 350 bpm in AF horses during exercise. Extremely high ventricular rates are regarded as a risk factor in exercising horses. In addition, such high rates are often accompanied by episodes of wide-QRS and R-on-T-like phenomenon which also hold a risk for induction of ventricular tachydysrhythmias. One should be aware that in most horses AF will persist once it is initiated, unless treatment is given. Only on rare occasions, especially in race horses, paroxysmal AF may occur during exercise, resolving spontaneously within the following seconds, hours or days. Diagnosis of such short-lasting AF events can be challenging.

3. Atrioventricular node

The most important dysrhythmias associated with the AV node are AV blocks. In case of first degree AV block, PQ interval is prolonged (> 500 ms), usually caused by high vagal tone. In case of 2nd degree AV block, the underlying rhythm is regular, but at regular intervals the P wave is blocked by the AV node and not further conducted to the ventricles. This results in a normal P wave, at the right time, but not followed by a QRS complex. The pause is exactly double the time of the normal cardiac cycle. The rhythm is regularly irregular and usually caused by high vagal tone. Mild exercise or simply stressing the animal should abolish the 2nd degree AV block temporarily. Occasionally, persistent high-grade (advanced) 2nd degree AV block is found, associated with clinical signs. Third degree AV block is a severe condition since there is no conduction of pulses from the atria to the ventricles. The

ventricles need to depolarise at their own, slow, intrinsic (escape)

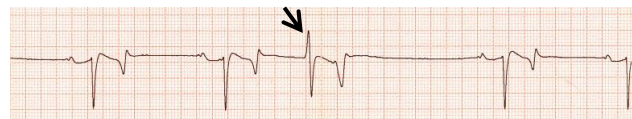

Third degree atrioventricular block. Atrial rate is 65 while ventricular rate is 22 bpm.

rhythm. On the ECG there is a complete dissociation between atrial and ventricular rhythm. Because of hypotension, the atrial rate (P waves) may be between 60 and 100 per minute while the ventricular rate remains slow. QRS complexes may have a normal configuration (originating from His-Purkinje network) or have an abnormal morphology and duration (originating from ventricular myocardium). The RR interval may be regular or irregular.

4. Ventricular myocardium

Ventricular premature contractions (VPCs) are depolarisations originating from the ventricular myocardium or ventricular conduction system. They are characterised by a QRS complex that occurs too early, having an abnormal morphology and duration. Generally, the VPC is



Ventricular premature contraction

followed by a compensatory pause which means that the interval 'normal-normal-normal' is almost equal to the interval 'normal-VPC-normal'. Occasionally, the VPC is interlaced between 2 normal beats. Ventricular tachycardia (VT) consists of three or more VPCs in a row. VT can be monomorphic or polymorphic, paroxysmal (intermittently, with spontaneous termination) or persistent. Persistent monomorphic VT is usually at a high rate (> 120 bpm). One should be aware that QRS duration of VPCs or VT at high heart rates may be within reference limits. VPCs and VT may deteriorate into ventricular flutter and ventricular fibrillation. During ventricular fibrillation (VF) a self-sustaining, rapid and chaotic electrical activity is present in the ventricular myocardium. The ECG shows irregular and bizarre waves, while QRS complexes and T waves can no longer be identified. Ventricular fibrillation may be coarse (large oscillations) or fine (small oscillations). P waves may still be identified.

Conclusion

ECG reading starts with identifying P waves, QRS complexes and T waves and determining their morphology and duration. Subsequently, the relation between all these waves is assessed. Logical, step-wise interpretation of these results allows to deduce the origin of the cardiac rhythm.