

Technical Refinements to Extended Metoidioplasty without Urethral Lengthening: Surgical Technique

Shane D. Morrison, MD, MS*†; Martin P. Morris, MBE‡; Sterre E. Mokken, BSc§;
Marlon E. Buncamper, MD, PhD*; Müjde Özer, MD§

INTRODUCTION

Phallic construction is a complex set of procedures associated with long recovery times and high complication rates, especially related to urethral lengthening.^{1,2} For these reasons, among others, fewer transgender and gender diverse people seek phallic construction relative to other gender-affirming procedures.³ To ameliorate urethral risks, variations in phalloplasty have been developed and include staged urethral lengthening, use of additional vascularized tissue from vaginectomy, and shaft-only options.⁴⁻¹⁰ Even with these refinements, these phallic constructions can suffer from unpredictable sensibility, voiding dysfunction, and inability to obtain spontaneous erections.¹¹⁻¹³

Metoidioplasty without urethral lengthening can subvert some of the limitations in phallic construction with retained sensibility, ability to attain erections, absence of a skin grafted donor site and minimization of urethral complications by creating a perineal urethrostomy.^{14,15} Individuals who chose this procedure can retain their vagina or undergo vaginectomy. While not all patients will be able to engage in penetrative intercourse, phallic length can be adequate if appropriately lengthened. This generally requires a clitoral length of at least 3 cm before metoidioplasty.¹⁶ Concomitant scrotoplasty can generally complete the reconstruction for most transgender and gender diverse people. The purpose of this article is to discuss refinements in metoidioplasty to improve phallic length and utilize local adipose tissue to add bulk to the scrotum and mimic testis (Table 1).

From the *Division of Plastic Surgery, Ghent University Hospital, Ghent, Belgium, †Seattle Children's Hospital, Seattle, Wash.; ‡Thomas Jefferson University, Philadelphia, Pa.; and §Department of Plastic Surgery, Amsterdam University Medical Center, Amsterdam, The Netherlands.

Received for publication November 30, 2021; accepted December 3, 2021.

Copyright © 2022 The Authors. Published by Wolters Kluwer Health, Inc. on behalf of The American Society of Plastic Surgeons. This is an open-access article distributed under the terms of the [Creative Commons Attribution-Non Commercial-No Derivatives License 4.0 \(CCBY-NC-ND\)](https://creativecommons.org/licenses/by-nc-nd/4.0/), where it is permissible to download and share the work provided it is properly cited. The work cannot be changed in any way or used commercially without permission from the journal.

Plast Reconstr Surg Glob Open 2022;10:e4101; doi: [10.1097/GOX.0000000000004101](https://doi.org/10.1097/GOX.0000000000004101); Published online 15 February 2022.

INDICATIONS/SURGICAL CASE

A 29-year-old transgender man presented to our tertiary referral center for genital gender affirmation after meeting the World Professional Association for Transgender Health Standards of Care, Version 7, criteria.¹⁷ His body mass index was 21 and his clitoral stretched length at baseline was 4 cm. He wanted to avoid phallic donor sites and retain phallic sensibility with the possibility of erections. He preferred to retain his vaginal canal and avoid urethral complications, so a metoidioplasty without urethral lengthening with scrotoplasty and perineal urethrostomy was proposed (see **Video [online]**, which demonstrates surgical refinement to extended metoidioplasty without urethral lengthening).

SURGICAL TECHNIQUE

The procedure is performed under general anesthesia with the patient in modified lithotomy position (hip and knee flexion < 90 degrees). A single dose of preoperative antibiotics is given as surgical prophylaxis. Planned incisions are designed. The first starts at the apex of the palpated clitoral suspensory ligament and extends down bilaterally around both labia minora, curving superiorly at the posterior labia minora to above the urethral meatus. The second incision for scrotoplasty begins just outside the external labia majora just above the urethral meatus and extends downward to encompass the posterior labia majora. The final incision is outlined in a semicircular fashion starting 2 cm above the planned clitoral apex incision. The incision extends downward bilaterally to 2 cm above the planned scrotoplasty incision. The space between the two incisions is maintained to preserve internal pudendal artery perforators (Fig. 1).

Traction sutures are placed in the bilateral labia minora and clitoral glans. A 16 French Foley catheter is placed. The ventral clitoral chordee (urethral plate) is released. The inner mucosa of the labia minora is demucosalized. The urethra is released slightly on the dorsal surface to allow it to transpose more easily into the perineum to sit behind the scrotum.

Disclosure: The authors have no financial interest to declare in relation to the content of this article.

Related Digital Media are available in the full-text version of the article on www.PRSGlobalOpen.com.

Table 1. Technical Modifications of Extended Metoidioplasty with Scrotal Autoaugmentation

Technical Modification	Outcome
Extensive lateral, ventral, and posterior clitoral release	Lengthened phallus
Suprapubic adipocutaneous flap	Autoaugmentation of scrotum to mimic testicles without the need for testicular implants
Transposition of clitoris under suprapubic adipocutaneous flap	Anatomic positioning of phallus with increased dorsal phallic projection
Augmentation of base of phallus with labia minora phallus	Improved projection of ventral phallus
Release of dorsal urethral meatus	Positioning of urethral meatus at base of scrotum, which can in some patients allow for an anterior directed urine stream while standing when the scrotum is pulled anterior and superior
Combined extended metoidioplasty with scrotoplasty, autoaugmentation with adipocutaneous flap, and perineal urethrostomy	Completion of genital reconstruction in a single stage

The incision along the clitoral suspensory ligament and labia minora is completed. Both the broad and narrow components of the clitoral suspensory ligament are released with care taken not to injure the clitoral shaft or neurovascular bundles. The posterior labia minora are completely released up to the clitoral shaft.

After complete release of the clitoris, the suprapubic incision is made. A plane just into the subcutaneous adipose tissue below the dermis is exposed for 10 × 10 cm. The edges of the adipose tissue are released to the anterior rectus sheath. Through the incision used to release the clitoral suspensory ligament, the plane between the anterior rectus sheath and the suprapubic adipose tissue is dissected to free the suprapubic adipocutaneous flap. The flap is a bipediced flap-based laterally.

The scrotoplasty incision is made and the labia majora elevated above Scarpa’s fascia. A rotation advancement

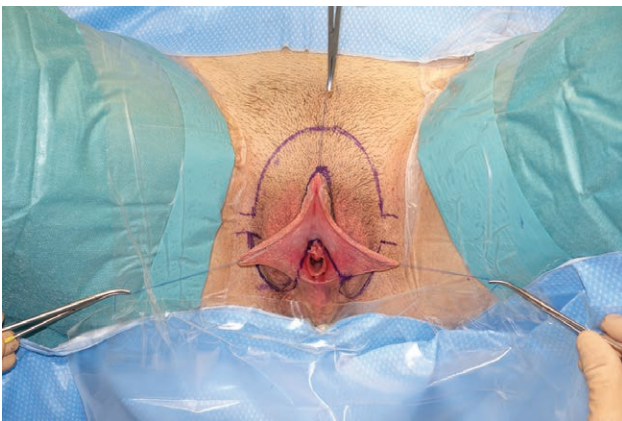


Fig. 1. Incision planning for metoidioplasty. Three incisions are outlined for clitoral and labia minora release, scrotoplasty, and suprapubic adipocutaneous flap elevation.

Takeaways

Question: How we can improve and innovate surgical technique for metoidioplasty without urethral lengthening?

Findings: This video article demonstrates surgical technique including extensive release of the clitoris and transposition of a suprapubic adipocutaneous flap for scrotal autoaugmentation.

Meaning: Extended metoidioplasty without urethral lengthening with autoaugmentation scrotoplasty with a suprapubic adipocutaneous flap is an option for phallic reconstruction for those desiring retained phallic sensibility.

flap for scrotoplasty is completed. The perineal tissue from the labia majora donor site is inset to the vaginal canal and urethra to create a perineal urethrostomy. The transposed suprapubic adipocutaneous flap adds bulk to the scrotum.

The clitoris is secured to the pubic tubercle to become the new phallus. The securing suture is placed in the midline of the phallus to minimize the risk of neurovascular bundle injury. The suprapubic skin is advanced to the base of the phallus and secured to the pubic tubercle. The dorsal phallic skin is secured to the advanced suprapubic area.

The amount of labia minora skin needed for ventral phallus coverage is estimated and the remainder deepithelialized. The deepithelialized tissue will be used to add more bulk to the base of the phallus. The lateral extensions of the suprapubic skin are advanced and secured to the deep tissue after a drain is placed. The base of the phallus is closed. Extra adipose tissue in the scrotum is removed as needed to allow for closure. The final phallic length obtained was 7 cm with an anatomic scrotum.

POSTOPERATIVE MANAGEMENT AND OUTCOMES

The Foley is left in place for 2 days and the phallus is wrapped in Kling to allow for elevation to improve venous drainage and reduce edema. After 3 days, the bandages are removed. Edema and some wound dehiscence are expected and are managed conservatively. Long-term outcomes are seen in Figure 2. We have completed this procedure in 17 patients with 27 months average follow-up, and none of the patients have decided to pursue secondary phalloplasty. Range of phallic length obtained at 6 months postoperative was 4–9 cm, with a range of phallic girth between 2 and 4 cm. Penetration was possible for four patients. Two patients had significant length and growth during erection, but had not attempted sexual intercourse yet. Other complications included mild wound dehiscence, as well as infection of a hematoma of the pubic area resulting in prophylactic drain placement (n = 2).

CONCLUSIONS

Extended metoidioplasty without urethral lengthening with autoaugmentation scrotoplasty with a suprapubic adipocutaneous flap is an option for phallic reconstruction




Fig. 2. Outcomes of extended metoidioplasty with scrotal autoaugmentation. A, Preoperative anatomy. B, Three-month postoperative anterior view. C, Three-month postoperative lateral view.

for those desiring retained phallic sensibility. Though standing micturition is largely not afforded postoperatively, this procedure allows for the potential for spontaneous erections with minimization of donor site morbidity and urologic complications.

Mijde Özer, MD

Department of Plastic, Reconstructive and Hand Surgery
Amsterdam UMC, location VU Medical Centre
De Boelelaan 1117
1081 HV Amsterdam, The Netherlands
E-mail: m.oz@amsterdamumc.nl

REFERENCES

1. Boczar D, Huayllani MT, Saleem HY, et al. Surgical techniques of phalloplasty in transgender patients: a systematic review. *Ann Transl Med.* 2021;9:607.
2. Lane M, Sluiter EC, Morrison SD, et al. Phalloplasty: understanding the chaos. *Plast Aesthet Res* 2020;7:51.
3. Nolan IT, Kuhner CJ, Dy GW. Demographic and temporal trends in transgender identities and gender confirming surgery. *Transl Androl Urol.* 2019;8:184–190.
4. Al-Tamimi M, Pigot GL, van der Sluis WB, et al. Colpectomy significantly reduces the risk of urethral fistula formation after urethral lengthening in transgender men undergoing genital gender affirming surgery. *J Urol.* 2018;200:1315–1322.
5. Al-Tamimi M, Pigot GL, van der Sluis WB, et al. The surgical techniques and outcomes of secondary phalloplasty after metoidioplasty in transgender men: an international, multi-center case series. *J Sex Med.* 2019;16:1849–1859.
6. Chen W, Cylinder I, Najafian A, et al. An option for shaft-only gender-affirming phalloplasty: vaginal preservation and vulvoscrotoplasty. A technical description. *Plast Reconstr Surg.* 2021;147:480–483.
7. Danker S, Esmonde N, Berli JU. “Staging” in phalloplasty. *Urol Clin North Am.* 2019;46:581–590.
8. Massie JP, Morrison SD, Wilson SC, et al. Phalloplasty with urethral lengthening: addition of a vascularized bulbospongiosus flap from vaginectomy reduces postoperative urethral complications. *Plast Reconstr Surg.* 2017;140:551e–558e.
9. Morrison SD, Chen ML, Crane CN. An overview of female-to-male gender-confirming surgery. *Nat Rev Urol.* 2017;14:486–500.
10. Huayllani MT, Boczar D, Saleem HY, et al. Single versus two-stage phalloplasty for transgender female-to-male patients: a systematic review of the literature. *Ann Transl Med.* 2021;9:608.
11. Morrison SD, Massie JP, Dellon AL. Genital sensibility in the neophallus: getting a sense of the current literature and techniques. *J Reconstr Microsurg.* 2019;35:129–137.
12. Rooker SA, Vyas KS, DiFilippo EC, et al. The rise of the neophallus: a systematic review of penile prosthetic outcomes and complications in gender-affirming surgery. *J Sex Med.* 2019;16:661–672.
13. Veerman H, de Rooij FPW, Al-Tamimi M, et al. Functional outcomes and urological complications after genital gender affirming surgery with urethral lengthening in transgender men. *J Urol.* 2020;204:104–109.
14. Bizic M, Stojanovic B, Bencic M, et al. Overview on metoidioplasty: variants of the technique. *Int J Impot Res.* 2020;33:762–770.
15. Pigot GLS, Al-Tamimi M, Nieuwenhuijzen JA, et al. Genital gender-affirming surgery without urethral lengthening in transgender men—a clinical follow-up study on the surgical and urological outcomes and patient satisfaction. *J Sex Med.* 2020;17:2478–2487.
16. Bizic MR, Stojanovic B, Joksic I, et al. Metoidioplasty. *Urol Clin North Am.* 2019;46:555–566.
17. Coleman E, Bockting W, Botzer M, et al. Standards of care for the health of transsexual, transgender, and gender-nonconforming people, version 7. *Int J Transgend.* 2012;13:165–232.