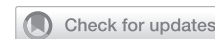

## SURGERY

## Surgical Outcomes After Treatment of Urethral Complications Following Metoidioplasty in Transgender Men



Freek P.W. de Rooij, MD,<sup>1</sup> Marco Falcone, PhD,<sup>2</sup> Mieke Waterschoot, MD,<sup>3</sup> Giuseppe Pizzuto, MD,<sup>2</sup> Mark-Bram Bouman, MD, PhD,<sup>4</sup> Paolo Gontero, MD, PhD,<sup>2</sup> Nicolaas Lumen, MD, PhD,<sup>3</sup> and Garry L.S. Pigot, PhD<sup>1</sup>

## ABSTRACT

**Background:** Several treatment options for urethral complications following metoidioplasty in transmen are described in the literature, yet little is known with regard to the surgical outcomes.

**Aim:** The aim of this study was to analyze the surgical outcomes after treatment of urethral strictures and urethral fistulas following metoidioplasty.

**Methods:** A multicenter retrospective cohort study was conducted with transmen treated for strictures and fistulas after metoidioplasty in 3 tertiary referral centers.

**Outcomes:** The primary outcome was the recurrence-free rate after surgical treatment of urethral strictures and urethral fistulas over a time period of 3 years postoperatively.

**Results:** Of 96 transmen included in this study with a urethral complication, 44 (46%) experienced a urethral fistula, 31 (32%) a urethral stricture, and 21 (22%) both complications simultaneously. The recurrence-free rate for urethral strictures following endoscopic management (ie, urethral dilation or direct visual internal urethrotomy) was 61% after 1, 50% after 2, and 43% after 3 years, compared to 82% following open treatment options after 1, 2, and 3 years ( $P = .002$ ). Open treatment options were Heineke-Mikulicz procedure (7/9, 78% success), excision and primary anastomosis (3/3, 100%), 2-stage without graft (9/9, 100%), pedicled flap urethroplasty (1/1, 100%), and buccal mucosa graft urethroplasty (2/4 [50%] single-stage, 1/1 [100%] 2-stage). The recurrence-free rate for small urethral fistulas located at the pendulous urethra was 79% after 1, and 72% after 2 and 3 years, compared to 45% after 1, and 41% after 2 and 3 years for large fistulas, generally located at the urethral anastomoses of the fixed urethra. Treatment options for urethral fistulas were fistulectomy (26/48, 54%), fistulectomy & (redo) colpectomy (7/11, 64%), buccal mucosa graft urethroplasty (1/1, 100%), and retubularization of the urethral plate (3/4, 75%). A colpectomy before or during reoperation of a urethral fistula at the proximal urethral anastomosis showed higher success rates compared to without a colpectomy (7/11 [64%] vs 2/13 [15%] respectively,  $P = .03$ ).

**Clinical Implications:** This study provides insight in the treatment possibilities and corresponding outcomes of urethral complications following metoidioplasty in transmen.

**Strengths & Limitations:** Strengths were the relatively large sample size and the overview of multiple treatment options available. Limitations were the heterogeneity of the cohort, underexposure of some surgical modalities, and absence of patient-reported outcomes.

**Conclusion:** Open surgical techniques show better long-term outcomes in the management of urethral strictures compared to endoscopic options, and a colpectomy is beneficial before or during urethral fistula repair at the proximal urethral anastomosis. **de Rooij FPW, Falcone M, Waterschoot M, et al. Surgical Outcomes After Treatment of Urethral Complications Following Metoidioplasty in Transgender Men. J Sex Med 2022;19:377–384.**

Received August 3, 2021. Accepted December 6, 2021.

<sup>1</sup>Department of Urology, Amsterdam University Medical Center, Location VUmc, Amsterdam, The Netherlands;

<sup>2</sup>Urology Department, Città della Salute e della Scienza, Torino, Italy;

<sup>3</sup>Department of Urology, Ghent University Hospital, Ghent, Belgium;

<sup>4</sup>Department of Plastic, Reconstructive and Hand Surgery, Amsterdam University Medical Center, Location VUmc, Amsterdam, The Netherlands

Copyright © 2021 The Authors. Published by Elsevier Inc. on behalf of the International Society for Sexual Medicine. This is an open access article under the CC BY-NC-ND license (<http://creativecommons.org/licenses/by-nc-nd/4.0/>).

<https://doi.org/10.1016/j.jsxm.2021.12.006>

Copyright © 2021 The Authors. Published by Elsevier Inc. on behalf of the International Society for Sexual Medicine. This is an open access article under the CC BY-NC-ND license (<http://creativecommons.org/licenses/by-nc-nd/4.0/>).

**Key Words:** Transgender Men; Genital Gender-Affirming Surgery; Metoidioplasty; Urethral Lengthening; Urethral Complications; Urethral Stricture; Urethral Fistula; Surgical Outcome

## INTRODUCTION

During metoidioplasty, a male-like external genital is reconstructed by using the hormonally hypertrophied clitoris, the labia minora and the labia majora.<sup>1</sup> Neo-urethral formation during metoidioplasty, in which vaginal flaps, labia minora island flaps, and vulvar vestibular mucosa may be used, enables transgender men to void from the tip of the neophallus.<sup>1</sup> Despite surgical developments worldwide, urethral lengthening remains one of the most complex parts of metoidioplasty, with high rates of urological complications postoperatively.<sup>1–3</sup> Urethral strictures and urethral fistulas are frequently reported, with incidence rates of 3–63% and 8–50% respectively.<sup>1–6</sup> Possible causes for urethral complications are postoperative infection, wound dehiscence, and local ischemia due to the use of multiple flaps.<sup>2,4</sup> Additionally, change in the urethral diameter at the anastomosis of native to fixed urethra may lead to alterations in intraurethral pressure during voiding, which is thought to be a risk factor for the formation of urethral fistulas.<sup>7</sup>

Several surgical techniques have been reported to treat urethral strictures and urethral fistulas, however, little is known with regard to the surgical outcomes as only a few studies describe single center or single surgeon results.<sup>4,7,8</sup> The aim of this study was to describe the surgical outcomes after treatment of urethral complications following metoidioplasty in a multicenter cohort of transgender men.

## METHODS

### Study Design

A multicenter retrospective cohort study was conducted with transgender men treated for urethral strictures and urethral fistulas after metoidioplasty in 3 tertiary referral centers. Transgender men that underwent metoidioplasty from January 2000 to December 2019 were included in the present study. Only participants with a postoperative follow-up of at least 12 months were recruited. The primary outcome was the recurrence-free rate after surgical treatment of urethral strictures and urethral fistulas. The study protocol was approved by local ethics committees of the participating centers, and all participants provided written informed consent for the use of their anonymized data.

### Data Collection

Data was retrieved and anonymized at each study site separately, and thereafter merged in a central database. Collected

data were participant characteristics (age, BMI, comorbidities, colpectomy, and length of follow-up), perioperative variables (type of metoidioplasty, operation time, length of hospital stay, and length of indwelling transurethral catheter), urethral complications (urethral stricture, urethral fistula, date and urethral location of complication), and corresponding treatments with recurrence rates.

### Definitions

A urethral stricture was defined as a symptomatic (eg, hesitancy, poor urinary stream, or incomplete bladder emptying) narrowing of the urethra, visualized with a retrograde urethrogram or urethroscopy. These diagnostic tests were used to evaluate stricture length and diameter preoperatively, to come to a surgical treatment plan. The definitive choice of treatment was based on surgeon's preference and stricture length observed during surgery. A urethral fistula was described as a connection between the urethra and skin or (a remnant of) the vaginal cavity, that persisted or originated at least 6 weeks after metoidioplasty. A distinction was made between small fistulas located at the ventral shaft of the pendulous urethra, and large fistulas, generally located at the urethral anastomoses of the fixed urethra. A recurrence was defined as a consecutive urethral stricture or urethral fistula after surgical treatment, at the same location in the urethra as the initial complication.

### Surgical Techniques

The following surgical modalities are used for urethral strictures:

- Transurethral procedures: Urethral dilation or Direct Visual Internal Urethrotomy (DVIU) according to Sachse are performed in short urethral strictures (<1 cm).
- Heineke-Mikulicz Procedure: Used in short urethral strictures (<1 cm), a longitudinal incision is made ventrally at the urethral stricture, and the urethra is closed transversely.
- Excision and Primary Anastomosis: A short urethral stricture (<1 cm) is excised and both urethral ends are spatulated and anastomosed.
- Pedicled Flap Urethroplasty: In case of a longer urethral stricture (≥1 cm) and with the availability of a local (hairless) skin flap, the urethra is incised ventrally and the strictured part is augmented with a pedicled ventral onlay flap.
- Single-stage Buccal Mucosa Graft (BMG) Urethroplasty: After ventral and dorsal incision of the urethra at the urethral stricture (≥1

cm), the harvested BMG is sutured as a dorsal inlay on the corporal bodies of the clitoris, and the urethra is closed ventrally.

- **Staged Urethroplasty:** In the first stage, the urethra is spatulated ventrally beyond the stricture site ( $\geq 1$  cm), and the edges are sutured to the phallic skin, resulting in displacement of the meatus proximally. A BMG is sutured as a dorsal inlay on the corporal bodies. In the second stage, tubularization of the urethra is performed after at least 3 months.

Treatment options for urethral fistulas are:

- **Fistulectomy:** In case of a urethrocutaneous fistula, the fistula tract is excised and the urethra is released ventrally, after which the urethral edges are sutured. Additionally, subcutaneous tissue and skin of the neophallus are sutured to cover the urethra with multiple layers, preventing overlapping suture lines. If a primary closure is not possible due to a too large urethral defect, a local pedicled skin flap or dorsal inlay BMG urethroplasty can be performed. In case of a urethrovaginal fistula, a fistulectomy is combined with a (redo) vaginectomy.
- **Retubularization of the Urethral Plate:** Dehiscence of the ventral distal part of the pendulous urethra is treated by retubularization of the pendulous urethra.

If transgender men do not prefer surgical correction for a urethral stricture or urethral fistula, a definitive perineostomy is created after which the possibility of micturition in standing position is abandoned.

## Statistical Analysis

SPSS Statistics 26.0 was used to analyze the data. After normality tests, descriptive statistics were displayed as mean with standard deviation, median with interquartile range, or number of participants with percentages (%). Dichotomous variables were analyzed using the chi-square test or Fisher's exact test as appropriate. Kaplan-Meier curves were used to display the recurrence-free rate after surgical treatment of urethral strictures and urethral fistulas over a time period of 3 years postoperatively. A log-rank test was performed to compare the recurrence-free rates after open and endoscopic treatment options for urethral strictures. A univariate Cox regression analysis was conducted to find possible predictors for recurrence of urethral complications. Variables used in this analysis were age, smoking status, type of urethral lengthening, location of the urethral complication, interval between metoidioplasty and reoperation, and whether or not participants had a colpectomy before or during reoperation. A *P* value of  $\leq .05$  was considered as significant.

## RESULTS

### Participant Characteristics

From January 2000 to December 2019, urethral complications were treated in 96 transgender men, of which 31 (32%) had a surgical treatment for a urethral stricture, 44 (46%) a

**Table 1.** Participant characteristics

|  |             |
|--|-------------|
| Total number of included participants                                      | 96          |
| Mean age at metoidioplasty, y (SD)   | 34 (10)     |
| Mean BMI, kg/m <sup>2</sup> (SD)   | 24.3 (3.6)  |
| Comorbidities, n (%)   |             |
| Smoking*   | 27 (28)     |
| Diabetes   | 1 (1)       |
| Colpectomy before metoidioplasty, n (%)                                    |             |
| Not performed  | 59 (62)     |
| Ablation   | 5 (5)       |
| Laparoscopic   | 27 (28)     |
| Transvaginal   | 5 (5)       |
| Type of fixed urethra, n (%)   |             |
| Anterior vaginal wall  | 5 (5)       |
| Vulvar vestibular mucosa   | 79 (82)     |
| Anterior vaginal wall and vulvar vestibular mucosa                         | 12 (13)     |
| Type of pendulous urethra, n (%)   |             |
| Tubularization of the vestibular mucosal plate                             | 65 (68)     |
| Local island flap  | 19 (20)     |
| Labial ring flap   | 6 (6)       |
| BMG augmentation   | 1 (1)       |
| Staged BMG augmentation  | 5 (5)       |
| Mean operation time of metoidioplasty, min (SD)                            | 169 (45)    |
| Median hospital stay, d (IQR)  | 6 (5–7)     |
| Median duration of indwelling transurethral catheter, d (IQR) <sup>†</sup> | 15 (12–23)  |
| Median follow-up time, mo (IQR)  | 63 (31–155) |

\*These men smoked perioperatively despite the medical advice to stop smoking.

<sup>†</sup>Catheter removal was planned 2 weeks after surgery, and postponed in case of postoperative complications.

BMI = Body Mass index; BMG = Buccal Mucosa Graft; IQR: Interquartile Range; SD = Standard Deviation.

surgical treatment for a urethral fistula, and 21 (22%) a combined surgical treatment for a stricture and fistula. Participant characteristics and urethral complications are shown in [Tables 1](#) and [2](#) respectively. The anastomosis of the fixed and pendulous urethra, visualized with retrograde urethrogram or urethroscopy at the penoscrotal angle after metoidioplasty, was the primary location of urethral strictures (17/52, 33%). The anastomosis between the native and fixed urethra was the primary location of urethral fistulas (24/65, 37%). Of 96 transgender men, 59 (62%) did not underwent a colpectomy prior to or during metoidioplasty.

### Surgical Outcomes

Success and recurrence rates per treatment option for urethral strictures and urethral fistulas are displayed in [Figures 1](#) and [2](#) respectively. In both groups, 1 participant had a definitive perineostomy, and was left out of success rate analysis. The median follow-up time after reoperation for a urethral

**Table 2.** Postoperative urethral complications (n = 96)

| Type of urethral complication, n (%)  |               |
|---|---------------|
| Urethral Stricture  | 31 (32)       |
| Urethral Fistula  | 44 (46)       |
| Both  | 21 (22)       |
| Median interval between metoidioplasty and diagnosis of urethral complication, d (IQR)      | 44 (27–191)   |
| Location of urethral stricture, n (%)   |               |
| PUA   | 7 (13)        |
| Fixed urethra   | 6 (12)        |
| DUA   | 17 (33)       |
| Pendulous urethra   | 11 (21)       |
| Unknown   | 11 (21)       |
| Location of urethral fistula, n (%)   |               |
| PUA   | 24 (37)       |
| Fixed urethra   | 5 (8)         |
| DUA   | 19 (29)       |
| Pendulous urethra   | 17 (26)       |
| Median interval between metoidioplasty and reoperation for a urethral complication, d (IQR) | 246 (158–552) |
| Median follow-up time after reoperation for a urethral complication, mo (IQR)               | 36 (14–123)   |

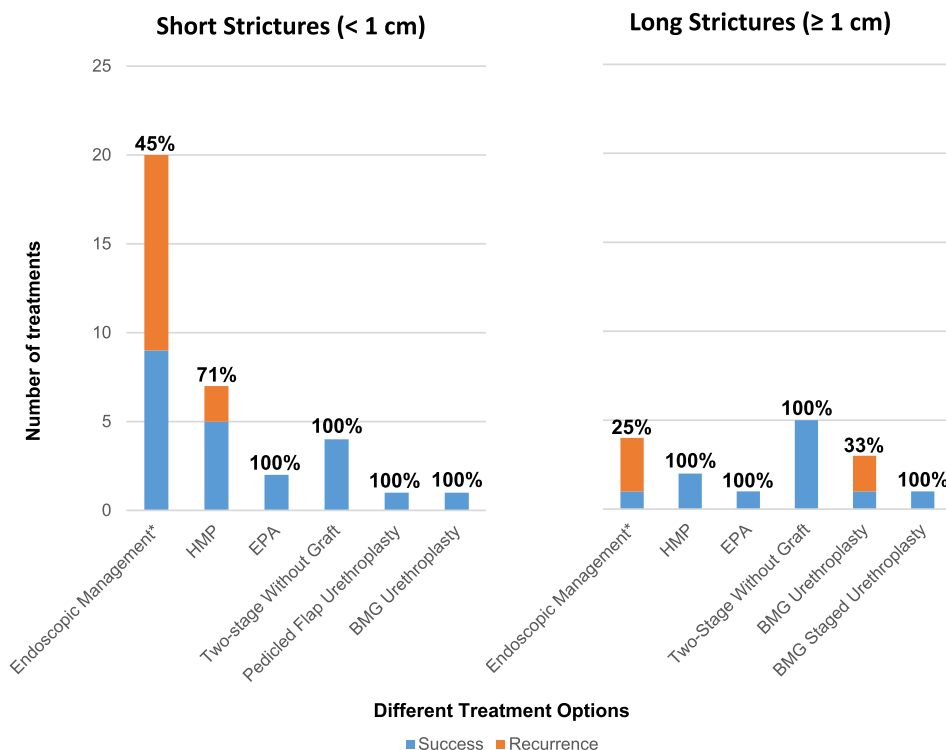
DUA = Distal Urethral Anastomosis; IQR = Interquartile Range; PUA = Proximal Urethral Anastomosis.

complications was 36 months (interquartile range 14–123). Success rates after treatment of isolated strictures or fistulas were comparable to success rates after combined treatment for both complications simultaneously, with success rates for strictures of 19/30 (63%) and 14/21 (67%) respectively ( $P = .81$ ), and for fistulas 24/43 (56%) and 13/21 (52%) respectively ( $P = .64$ ).

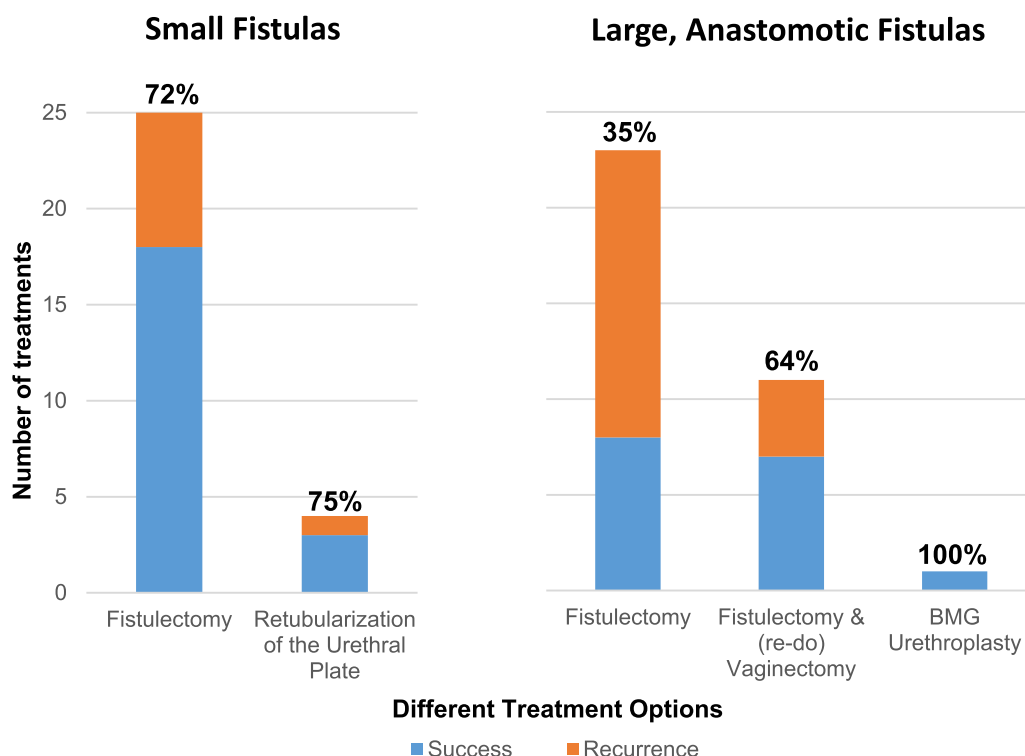
Of 64 transgender men with a urethral fistula repair, 31 (48%) did not undergo a colpectomy before or during reoperation. A colpectomy before or during reoperation, showed no effect on the outcome of urethral fistula treatment (success rate of 22/33 [67%] vs 15/31 [48%] respectively,  $P = .14$ ). In an additional analysis of 24 men with a urethral fistula located at the proximal urethral anastomosis, 13 (54%) did not have a colpectomy before or during reoperation. In this subgroup, higher success rates were seen for the participants who had a colpectomy before or during reoperation compared to who did not (7/11 [64%] vs 2/13 [15%] respectively,  $P = .03$ ).

### Recurrence-Free Rate

The recurrence-free rate for urethral strictures following trans-urethral management was 61% after 1, 50% after 2, and 43%



**Figure 1.** Success and recurrence rates per treatment option for urethral strictures, divided by short (<1 cm) and long (≥1 cm) strictures (n = 51). Success rates displayed as percentages above each bar. BMG = Buccal Mucosa Graft; EPA = Excision and Primary Anastomosis; HMP = Heineke-Mikulicz Procedure. \*Urethral Dilatation and Direct Visual Internal Urethrotomy (Figure 1 is available in color online at [www.jsm.jsmed.org](http://www.jsm.jsmed.org)).



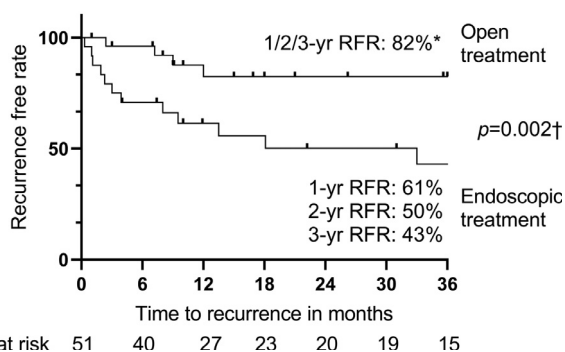
**Figure 2.** Success and recurrence rates per treatment option for urethral fistulas, divided by small and large, anastomotic fistulas ( $n = 64$ ). Success rates displayed as percentages above each bar. BMG = Buccal Mucosa Graft (Figure 2 is available in color online at [www.jsm.jsexmed.org](http://www.jsm.jsexmed.org)).

after 3 years, compared to 82% following open treatment options after 1, 2, and 3 years ( $P = .002$ , Figure 3).

The recurrence-free rate for small urethral fistulas located at the pendulous urethra was 79% after 1, and 72% after 2 and 3 years. For large fistulas, generally located at the

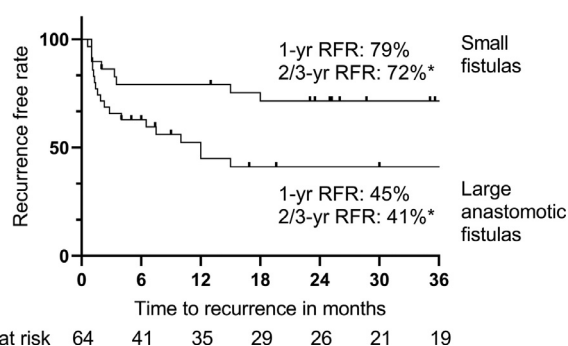
urethral anastomoses of the fixed urethra, recurrence-free rates were 45% after 1, and 41% after 2 and 3 years (Figure 4). No significant predictors for recurrence of urethral strictures or fistulas were identified after univariate Cox regression analysis (Table 3).

#### RFR After Urethral Stricture Treatment



**Figure 3.** Recurrence-free rate after surgical treatment of a urethral stricture, divided by open and endoscopic treatment options ( $n = 51$ ). RFR = Recurrence-free Rate. \*The RFR remained 82% after the first, second and third year following open treatment options for a urethral stricture. †A log-rank test was performed to compare the recurrence-free rates after open and endoscopic treatment options.

#### RFR After Urethral Fistula Treatment



**Figure 4.** Recurrence-free rate after surgical treatment of a urethral fistula, divided by small and large, anastomotic fistulas ( $n = 64$ ). RFR = Recurrence-free Rate. \*The RFR remained the same after the second and third year following urethral fistula treatment, 72% for small fistulas and 41% for large, anastomotic fistulas.



**Table 3.** Univariate Cox regression analysis for recurrence of urethral strictures and urethral fistulas

|  | Univariate analysis for urethral strictures (n = 51) |         | Univariate analysis for urethral fistulas (n = 64) |         |
|--|--|---------|--|---------|
|  | HR (95% CI)  | P value | HR (95% CI)  | P value |
| Age  | 1.0 (1.0–1.1)  | .55     | 1.0 (0.9–1.0)                                      | .36     |
| Smoking  | 1.5 (0.4–5.3)  | .53     | 1.6 (0.7–3.4)                                      | .22     |
| Type of urethral lengthening during metoidioplasty | 1.1 (0.7–1.6)  | .70     | 0.5 (0.3–1.1)                                      | .07     |
| Location of urethral complication                  | 1.2 (0.8–1.7)  | .42     | 1.3 (1.0–1.7)                                      | .22     |
| Interval between metoidioplasty and reoperation    | 1.0 (1.0–1.0)  | .19     | 1.0 (1.0–1.0)                                      | .79     |
| Colpectomy before/during reoperation or not        | 0.4 (0.1–1.1)  | .07     | 0.6 (0.3–1.2)                                      | .13     |

CI = Confidence Interval; HR = Hazard Ratio.

## DISCUSSION

In this multicenter study, 96 transgender men who had a urethral complication following metoidioplasty with urethral lengthening were described with regard to the success and recurrence rates after surgical treatment. Recurrences of urethral complications were frequently seen. The recurrence-free rates for urethral strictures after 3 years of follow-up were 43% after endoscopic management (ie, urethral dilation or DVIU), and 82% after open surgical treatment options. The recurrence-free rates for urethral fistulas after 2 and 3 years of follow-up were 72% for small fistulas located at the pendulous urethra, and 41% for large fistulas generally located at the urethral anastomoses of the fixed urethra. Colpectomy before or during urethral fistula repair is beneficial in fistulas located at the proximal urethral anastomosis, or in connection with (a remnant of) the vaginal cavity.

### Treatment of Urethral Strictures

For urethral strictures, open treatment options showed significantly higher success rates compared to transurethral management. Although urethral dilation and DVIU were mostly performed in short (<1 cm) and relatively simple urethral strictures, the majority of transgender men had a recurrence. Endoscopic management might suffice as a temporary solution until further treatment is possible, however, open treatment options show better results as a definitive solution on the long term.<sup>9</sup> Compared to studies with long term follow-up in cisgender men, DVIU also had a high recurrence rate of 70–90%.<sup>10</sup> Therefore, performing a primary open surgical correction for urethral strictures is advisable.

Staged urethroplasty with or without a BMG for urethral strictures showed a success rate of 10/10 (100%). In a staged procedure, an interval between surgeries of 3–6 months is used to provide time for the urethra to heal. Although micturition in standing position is not possible due to a temporary scrotal or perineal urethrostomy, transgender men have a good urodynamic function during this period without indwelling catheters. Due to

relatively high recurrence rates of urethral strictures in general, a sufficient part of transgender men need multiple surgical treatments, making a shift towards staged procedures more eligible. In particular for more complicated strictures (eg, longer, more scarred, or infectious strictures, or located in less vascularized periurethral tissue), a staged urethroplasty may be beneficial in achieving the best surgical outcome.<sup>11</sup>

### Treatment of Urethral Fistulas

After fistulectomy, high recurrence rates were seen, especially in the first year of postoperative follow-up and in case of large fistulas located at the fixed urethra. Comparison with recurrence rates described in the literature was difficult as previously studied cohorts were small, surgical techniques mostly not described, and length of follow-up was short or unknown.<sup>1–3,12</sup> Despite changes in the surgical technique (ie, fistula closure with multiple layers of tissue without overlapping suture lines), recurrences following urethral fistula repair persist.<sup>4</sup> During metoidioplasty, different types of tissue are used to lengthen the urethra to the tip of the neophallus. If transgender men have postoperative complications (eg, wound dehiscence, infection, strictures, or fistulas), further variations in the neo-urethra occur, such as additional scar tissue and prestenotic dilation of a urethral stricture.<sup>2,4,6</sup> Differences in diameter and flexibility of the neo-urethral tissue may result in alterations of intraurethral pressure during voiding, which is thought to be a risk factor for urethral fistulas.<sup>7</sup> This could also explain why 22% of the participants had a concomitant urethral stricture and fistula. We believe that creating a wide neo-urethral tract during metoidioplasty and reoperations, if necessary with the use of a BMG, may result in a lower urethral (re-) fistula rate.

The majority of transgender men in our cohort did not undergo a colpectomy before metoidioplasty (62%). These were mostly participants who had their metoidioplasty before 2009. Since that time, a colpectomy has been mandatory. This adjustment of the surgical pathway resulted in a decrease of the urethral

fistula rate from 65/154 (42%) to 1/12 (8%) in participants after metoidioplasty.<sup>13</sup> If a colpectomy is performed, the well-vascularized bulbospongiosus muscle can be used to cover the urethral anastomosis between the native and the fixed urethra.<sup>13,14</sup> However, a colpectomy is a complex procedure with its own risk of complications. Nikkels et al (2019) showed that after vaginal colpectomy, 17/143 (12%) transgender men had a major postoperative complication with the need for secondary intervention.<sup>15</sup> In our cohort, higher success rates were observed for transgender men who had a colpectomy before or during urethral fistula closure if the fistula was located at the proximal urethral anastomosis. No effect of colpectomy on success rates was observed in analysis with all fistula locations combined. Therefore, colpectomy is advised during repair of urethral fistulas located at the proximal urethral anastomosis or in connection with (a remnant of) the vaginal cavity.

### Predictors for Recurrence

No significant predictors for recurrence of urethral complications were identified, possibly due to the heterogeneity of the cohort. Although the sample size was relatively high compared to previous literature, differences in techniques used for metoidioplasty and type of reoperations made it difficult to do additional subanalyses.

### Surgical Techniques

Metoidioplasty techniques changed over the years to achieve higher satisfaction with regard to appearance and functionality (eg, micturition and sexuality), and to reduce the number of postoperative complications.<sup>16</sup> Alterations in the formation and coverage of the fixed and pendulous urethra were needed to decrease the number of urethral strictures and urethral fistulas, in particular at the urethral anastomoses.<sup>1,3,7,12</sup> Due to the lack of prospective data in which techniques of metoidioplasty are compared, it is unclear what type of metoidioplasty provides the best surgical outcome, and urethral complications are still frequently reported.<sup>1–6</sup> In this multicenter study, 3 different types of fixed urethra and 5 types of pendulous urethra were used over the years, as displayed in Table 1. As a result, a certain level of heterogeneity is present during comparison of groups.

In addition to the different techniques of metoidioplasty, multiple types of reoperations were described to treat urethral strictures and urethral fistulas. The choice of surgical treatment is partly based on complication characteristics (eg, length, size, patency, location, and degree of infection or scar tissue), and the level of periurethral vascularization.<sup>8</sup> Surgeons experience and preference, however, also has to be taken into account. Due to the variety in surgical treatments and small groups per surgical modality, comparison of treatment options on success and recurrence rates remains difficult. However, compared to previous literature in which single center or single surgeon results were

shown, current study presents a reasonable overview of treatment options available with success and recurrence rates.<sup>4,7,8</sup>

### Strengths and Limitations

Strengths of this study were the relatively large sample size and the overview of multiple treatment options available for urethral complications with corresponding success and recurrence rates. Limitations were the heterogeneity of the cohort, as previously described, which had a possible negative effect on the comparison of groups. In addition, some surgical modalities were underexposed in the treatment of urethral complications. No clear statement can be made for instance on the effect of BMG urethroplasty (single and 2-staged) in the treatment of urethral complications after metoidioplasty, which is something that could be described in future studies. Therefore, it is difficult to conclude our study with a specific treatment advice. Lastly, no patient-reported outcomes were scored, which is needed to clarify the postoperative quality of life and satisfaction with the appearance and functionality following complication surgery after metoidioplasty.

### CONCLUSIONS

Recurrences of urethral complications were frequently seen in transgender men that underwent urethral reoperation after metoidioplasty. Open surgical techniques showed better long-term outcomes in the management of urethral strictures compared to endoscopic options, and therefore primary open surgical correction for urethral strictures is advisable. Colpectomy during urethral fistula repair is only necessary if the urethral fistula is located at the proximal urethral anastomosis, or in connection with (a remnant of) the vaginal cavity.

**Corresponding Author:** Freek P. W. de Rooij, MD, Department of Urology, Amsterdam UMC, Location VUmc, De Boelelaan 1117, 1081 HV, Amsterdam, The Netherlands. Tel: +31-20-4446030; Fax: +31-20-4446031; E-mail: [f.derooij@amsterdamumc.nl](mailto:f.derooij@amsterdamumc.nl)

*Conflict of Interest:* The authors report no conflicts of interest.

*Funding:* None.

### STATEMENT OF AUTHORSHIP

Freek P.W. de Rooij: Methodology, Formal Analysis, Investigation, Writing – Original Draft, Visualization; Marco Falcone: Conceptualization, Methodology, Formal Analysis, Investigation, Writing – Review & Editing, Visualization, Supervision, Project Administration; Mieke Waterschoot: Investigation, Writing – Review & Editing, Visualization, Project Administration; Giuseppe Pizzuto: Investigation, Visualization, Project Administration; Mark-Bram Bouman: Methodology, Writing – Review & Editing, Visualization, Supervision; Paolo Gontero: Conceptualization, Writing – Review & Editing, Supervision; Nicolaas

Lumen: Conceptualization, Writing – Review & Editing, Supervision; Garry L.S. Pigot: Conceptualization, Writing – Original Draft, Supervision, Project Administration.

## REFERENCES

1. Djordjevic ML, Bizic MR. Comparison of two different methods for urethral lengthening in female to male (metoidioplasty) surgery. *J Sex Med* 2013;10:1431–1438.
2. Hage JJ, van Turnhout AA. Long-term outcome of metoidioplasty in 70 female-to-male transsexuals. *Ann Plast Surg* 2006;57:312–316.
3. Takamatsu A, Harashina T. Labial ring flap: A new flap for metoidioplasty in female-to-male transsexuals. *J Plast, Reconstr Aesthetic Surg: JPRAS* 2009;62:318–325.
4. Lumen N, Waterschoot M, Verla W, et al. Surgical repair of urethral complications after metoidioplasty for genital gender affirming surgery. *Int J Impot Res* 2020;33:771–778.
5. Perovic SV, Djordjevic ML. Metoidioplasty: A variant of phalloplasty in female transsexuals. *BJU Int* 2003;92:981–985.
6. Veerman H, de Rooij FPW, Al-Tamimi M, et al. Functional outcomes and urological complications after genital gender affirming surgery with urethral lengthening in transgender men. *J Urol* 2020;204:104–109.
7. Johnsen NV, Voelzke BB. Autologous rectus fascia graft interposition repair of urethrocutaneous fistulae in female-to-male metoidioplasty patients. *Urology* 2018;116:208–212.
8. Nikolavsky D, Hughes M, Zhao LC. Urologic complications after phalloplasty or metoidioplasty. *Clin Plast Surg* 2018;45:425–435.
9. Jun MS, Santucci RA. Urethral stricture after phalloplasty. *Transl Androl Urol* 2019;8:266–272.
10. Shaw NM, Venkatesan K. Endoscopic management of urethral stricture: Review and practice algorithm for management of male urethral stricture disease. *Curr Urol Rep* 2018;19:19.
11. de Rooij FPW, Peters FRM, Ronkes BL, et al. Surgical outcomes and proposal for a treatment algorithm of urethral strictures in transgender men. *BJU Int* 2021. E-pub ahead of print. doi: 10.1111/bju.15500.
12. Djordjevic ML, Stanojevic D, Bizic M, et al. Metoidioplasty as a single stage sex reassignment surgery in female transsexuals: Belgrade experience. *J Sex Med* 2009;6:1306–1313.
13. Al-Tamimi M, Pigot GL, van der Sluis WB, et al. Colpectomy significantly reduces the risk of urethral fistula formation after urethral lengthening in transgender men undergoing genital gender affirming surgery. *J Urol* 2018;200:1315–1322.
14. Massie JP, Morrison SD, Wilson SC, et al. Phalloplasty with urethral lengthening: addition of a vascularized bulbo-spongiosus flap from vaginectomy reduces postoperative urethral complications. *Plast Reconstr Surg* 2017;140:551e–558e.
15. Nikkels C, van Trotsenburg M, Huirne J, et al. Vaginal colpectomy in transgender men: A retrospective cohort study on surgical procedure and outcomes. *J Sex Med* 2019;16:924–933.
16. Jolly D, Wu CA, Boskey ER, et al. Is clitoral release another term for metoidioplasty? A systematic review and meta-analysis of metoidioplasty surgical technique and outcomes. *Sex Med* 2021;9:100294.